

PATIENT

Smash Thompson

SPECIES

Canine

BREED

Catahoula

SEX

Neutered Male

AGE

2 Years 3 Months

WEIGHT

38.3 kg

INTERPRETED BY

R. McKenzie Daniel,
DVM, DABVP (Canine
/ Feline Practice)

IMAGING PERFORMED BY

Renee Trionfetti VMD

HOSPITAL NAME

Blue Pearl Wyomissing

REFERRING VET

Heatherlynn
McFarlane DVM,
DACVIM (Internal
Med)

INVOICE

15543

DATE

04/28/26

PRESENTING CLINICAL SIGNS

AUS to further evaluate bilateral pleural effusion, decreased appetite, lethargy. BW changes showed elevated ALT, hypoproteinemia, hyperglobulinemia, normal alb, hypocholesterolemia, hyperphosphatemia, Anaplasma positive. CXR shows pleural effusion bilaterally and poss widened mediastinum (vs positioning). Presented to IM service for evaluation. Increased RR/RE. Signs were first noted 4/19. Evaluated by pDVM and had BW performed and Smash was empirically started on doxycycline due to recent tick exposure (BW not available for review at time of consultation but reported negative for tick diseases). After starting doxycycline, Smash's appetite continued to decline and he started vomiting.

Abnormal PE/Chem/CBC/UA Results: Thoracocentesis: 1,850 hemorrhagic fluid removed CBC: PLT 91 L PCV/TS: 44%/5 L Chem: TP 4.8 L, Alb 3.0. Glob 1.8 L, Cr 0.8. BUN 15.8, ALT 400 H, ALP 80, GGT <10, TBil 0.1, Chol 116 L, Ca 9.9, Phos 8.3 H, Glu 115 PT/PTT: 16.8s/109.6s 4Dx: Anaplasma pos, HW/Lyme/Ehrlichia Neg CXR (3v): There is marked loss of detail due to the presence of pleural effusion (R>>L). Lungs are retracted and floating in the caudodorsal aspect of the lung fields on both lateral views. Cardiac silhouette is not visible. VD concern for widening of the mediastinum PCV/TS: 47%/5.4g/dL Blood smear: No platelet clumps seen on the peripheral edge. Averaging between 6-7PLT/HPF, RBC morphology is overall unremarkable. Unremarkable WBC morphology. No evidence of intracellular parasites seen

ULTRASONOGRAPHIC EXAMINATION OF THE ABDOMEN

Urinary System

The urinary bladder, trigone, cystourethral junction, and visible pelvic urethra to a depth of 2.0 cm exhibited normal thickness and tone. Primarily anechoic urine was present in the lumen. Echogenic to particulate nondependent mild sediment was present without evidence of calculus formation. The ureteral papillae were normal. The ureters were not visible which is normal. No evidence of inflammatory or neoplastic mural changes were noted.

The area of the residual prostate appeared normal and free of pathology.

Normal size and margination was present in the kidneys. A normal 1:3 cortex / medulla ratio and normal corticomedullary definition were maintained. The echogenicity of the cortex was similar to or slightly less than normal liver parenchyma while the medulla echogenicity was hypoechoic to the cortex with no evidence of pelvic dilation. The left kidney measured 6.5 cm in length. The right kidney measured 5.7 cm in length.

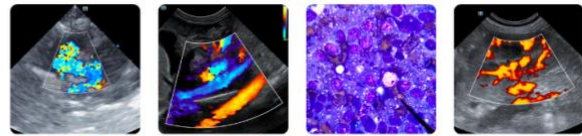
Adrenal Glands

The left adrenal gland was not definitively visualized owing to periadrenal lymphadenopathy.

The right adrenal gland was uniform in size and contour with a uniformly hypoechoic parenchyma. The right adrenal gland measured 0.66 cm width at the caudal pole.

Spleen

The spleen exhibited a finely textured and homogenous parenchyma which was hyperechoic to the liver and renal cortical parenchyma. The capsule was smooth and regular without apparent expansion. The splenic vasculature at the hilus was normal in volume with no evidence of congestion or



PATIENT

Smash Thompson

SPECIES

Canine

BREED

Catahoula

SEX

Neutered Male

AGE

2 Years 3 Months

WEIGHT

38.3 kg

INTERPRETED BY

R. McKenzie Daniel,
DVM, DABVP (Canine
/ Feline Practice)

IMAGING PERFORMED BY

Renee Trionfetti VMD

HOSPITAL NAME

Blue Pearl Wyomissing

REFERRING VET

Heatherlynn
McFarlane DVM,
DACVIM (Internal
Med)

INVOICE

15543

DATE

04/28/26

thrombosis. Acute to chronic inflammatory, neoplastic, or benign parenchyma changes were not noted.

Liver & Gallbladder

The liver revealed generalized hepatomegaly. The hepatic parenchyma revealed diffuse reduced echogenicity compared to the spleen with a mild coarse echotexture. Increased prominence of the intrahepatic hyperechoic portal vascular borders. The capsule of the liver was normal in margination. Distinct masses or nodules were not evident. The hepatic and portal vasculature were normal in appearance without signs of congestion.

The gallbladder was non-distended in size with thin walls and primarily anechoic luminal content. The cystic and common bile ducts were normal.

Gastrointestinal

The stomach presented mildly thickened hypoechoic wall with empty lumen and intact to indistinct gastric mural detail. The stomach wall measured 0.82 cm wall width.

The small intestine presented intact wall layering with 1:3 muscularis/mucosa ratio. The lumen of the small intestine was empty with no signs of ileus, obstruction or foreign material.

Normal visible colon wall layers were present with apparent formed feces in lumen.

Pancreas

The area of the pancreas was indistinctly visualized yet sonographically unremarkable.

Free Abdomen

Multiple abdominal lymph nodes and mild medial iliac/sublumbar lymph nodes were present. The lymph nodes exhibited symmetrical to rounded margination with abnormal width: length ratio (>0.5). Perilymphatic to generalized mild omental hyperechogenicity. An example of medial iliac lymph nodes measured 2.1 cm in diameter. An example of mesenteric lymph nodes measured 5.4 cm x 3.0 cm

Heart

Brief subjective echocardiogram revealed normal left and right heart chamber dimension and adequate LV systolic function. Mild compensated. Eccentric MR on doppler. Indistinctly marginated significant cranial mediastinal lymphadenopathy to mediastinal mass was visualized measuring approximately 9.0 to 10.0 cm in diameter. Peritoneal and pleural effusion was present.

ULTRASONOGRAPHIC FINDINGS

- Multicentric hyperechoic to swollen abdominal lymphadenopathy with concurrent marked cranial mediastinal lymphadenopathy/mediastinal mass.
- Enlarged hypoechoic noncongested liver.
- Mildly thickened empty stomach, sonographically normal small intestine.
- Subjective normal cardiac structure/function with mild compensated mitral insufficiency.
- Noncardiogenic bi-cavitary effusion.
- Mild urine sediment.

INTERPRETATION OF THE FINDINGS & FURTHER RECOMMENDATIONS



PATIENT

Smash Thompson

SPECIES

Canine

BREED

Catahoula

SEX

Neutered Male

AGE

2 Years 3 Months

WEIGHT

38.3 kg

INTERPRETED BY

R. McKenzie Daniel, DVM, DABVP (Canine / Feline Practice)

IMAGING PERFORMED BY

Renee Trionfetti VMD

HOSPITAL NAME

Blue Pearl Wyomissing

REFERRING VET

Heatherlynn McFarlane DVM, DACVIM (Internal Med)

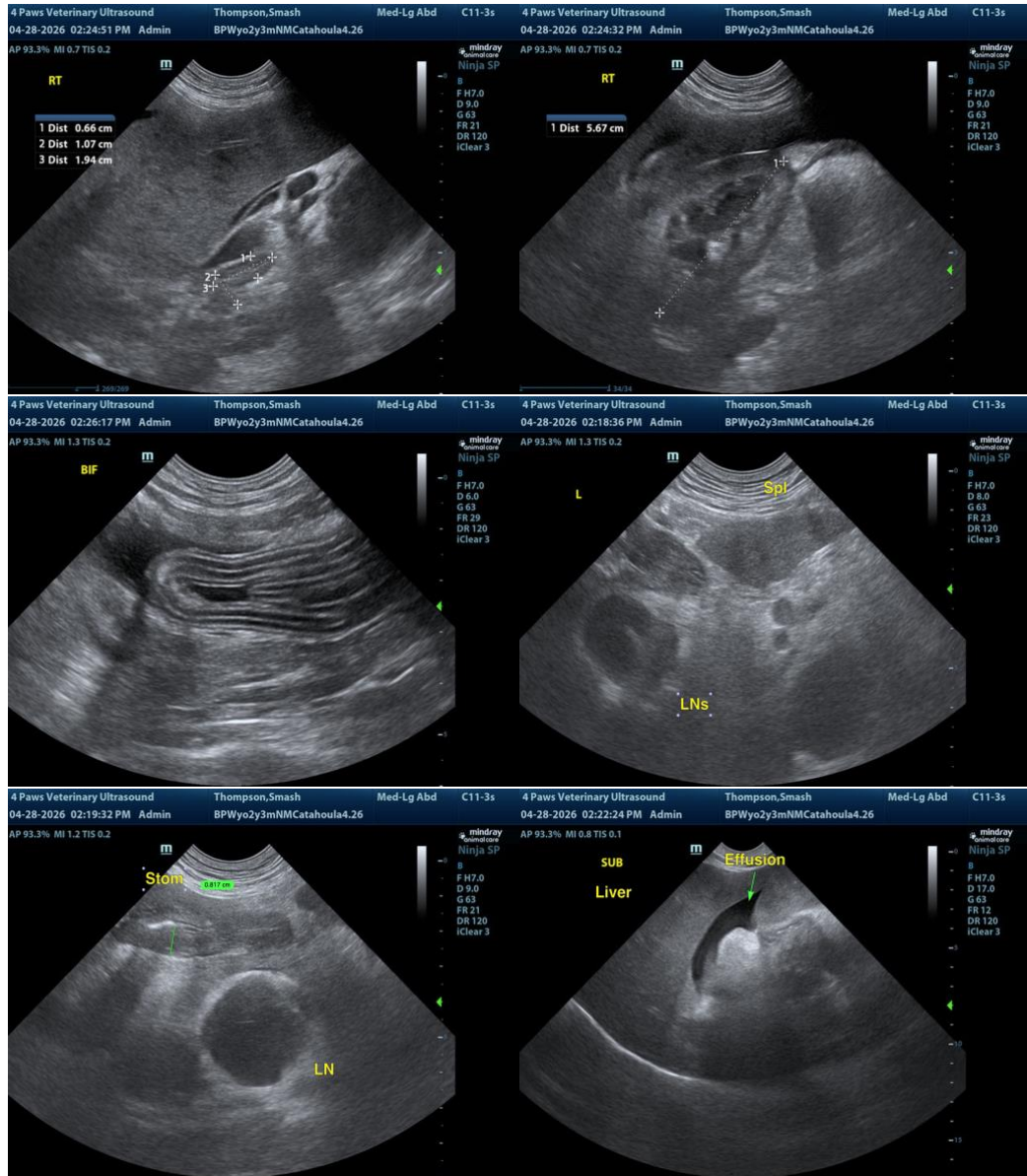
INVOICE

15543

DATE

04/28/26

The sonographic findings are consistent with multicentric round cell neoplasia such as lymphoma or other. Multicentric FNA cytology and correlation with effusion analysis and oncology consult is recommended.





PATIENT

Smash Thompson

SPECIES

Canine

BREED

Catahoula

SEX

Neutered Male

AGE

2 Years 3 Months

WEIGHT

38.3 kg

INTERPRETED BY

R. McKenzie Daniel,
DVM, DABVP (Canine
/ Feline Practice)

**IMAGING
PERFORMED BY**

Renee Trionfetti VMD

HOSPITAL NAME

Blue Pearl Wyomissing

REFERRING VET

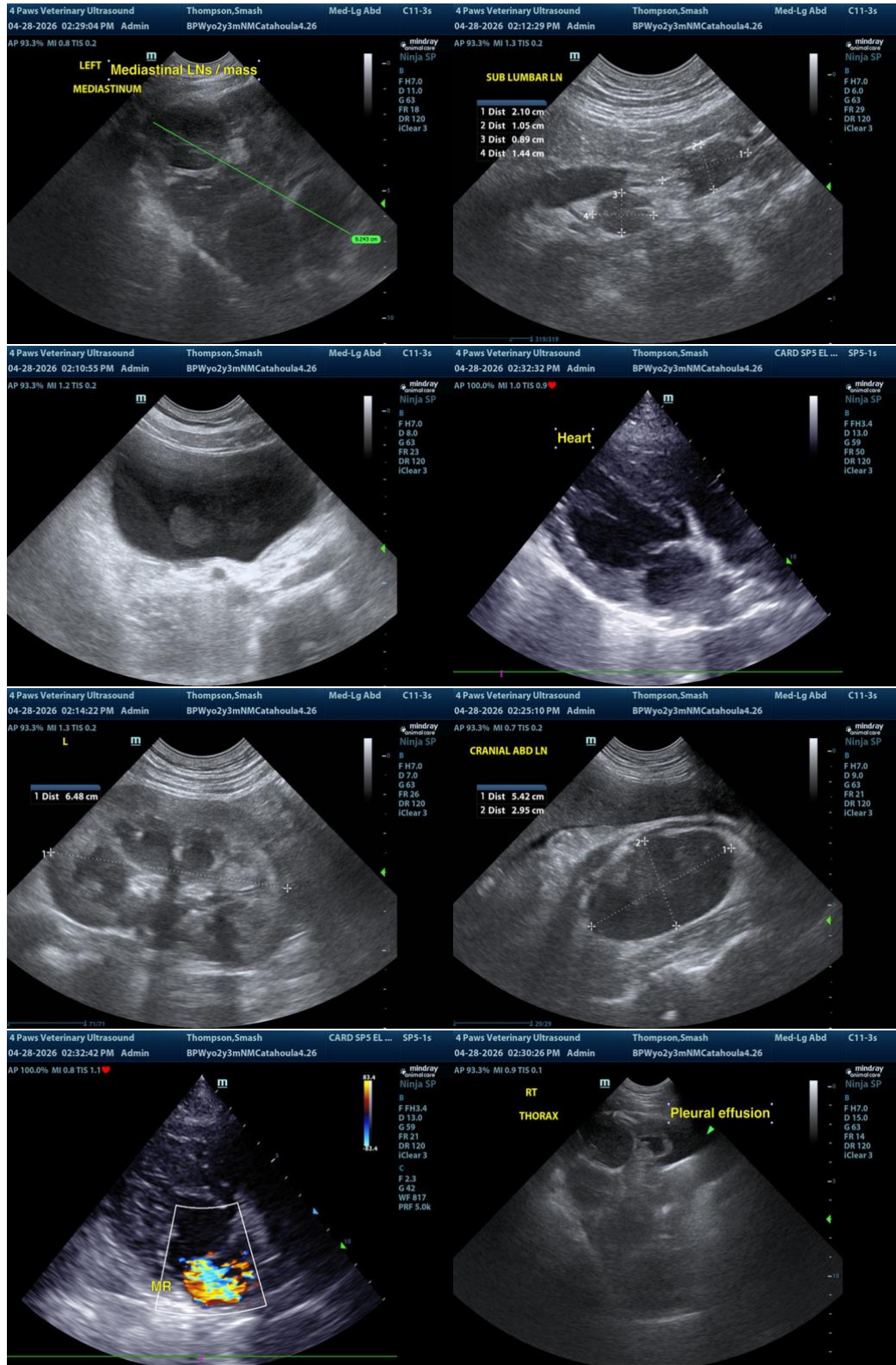
Heatherlynn
McFarlane DVM,
DACVIM (Internal
Med)

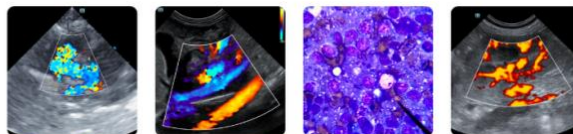
INVOICE

15543

DATE

04/28/26





PATIENT

Smash Thompson

SPECIES

Canine

BREED

Catahoula

SEX

Neutered Male

AGE

2 Years 3 Months

WEIGHT

38.3 kg

INTERPRETED BY

R. McKenzie Daniel,
DVM, DABVP (Canine
/ Feline Practice)

IMAGING PERFORMED BY

Renee Trionfetti VMD

HOSPITAL NAME

Blue Pearl Wyomissing

REFERRING VET

Heatherlynn
McFarlane DVM,
DACVIM (Internal
Med)

INVOICE

15543

DATE

04/28/26

The information and recommendations provided are based on the images presented by the referring veterinarian/sonographer. No evaluation can be communicated regarding pathology that was not visible in the image/video clips provided.

Thank you for this referral. If the clinical or image interpretation does not parallel your findings or if I can be of any further assistance, please contact me.

R. McKenzie Daniel, DVM, DABVP (Canine / Feline Practice)

info@SonoPath.com