



PATIENT

Ruthie Flannery

SPECIES

Canine

BREED

Australian Shepherd

SEX

FS

AGE

3yr

WEIGHT

50.2lb

INTERPRETED BY

R. McKenzie Daniel,
DVM, DABVP
(Canine and Feline)

IMAGING PERFORMED BY

Graham Sager-Gellerman, DVM

HOSPITAL NAME

Back Bay Veterinary
Clinic

REFERRING VET

Tess Gannaway, DVM

INVOICE

13618ag

DATE

04/28/2023

PRESENTING CLINICAL SIGNS

3.5 yo FS Australian sheperd Presented for annual exam 4/3/23 w/ no concerns. Routine labwork indicated elevated SDMA, remainder relatively wnl. Follow up USG (after overnight water withheld) isosthenuric. Owner would like to try and r/o underlying renal disease. No obvious clinical signs -- no PU/PD (per owner), no vomiting, good appetite. Has lost 2 lbs over past 3 weeks. Historically relatively lethargic pup.

Abnormal PE/Chem/CBC/UA Results: 4/4/23: CBC: wnl CHEM: Glu 82, SDMA 21, Creat 1.1, BUN 16, electrolytes wnl, ALT 12 (18-121) 4dx: neg 4/18/23: USG: 1.015 Pre-OVH labwork 4/25/20: SDMA: 12, ALT 16

ULTRASONOGRAPHIC EXAMINATION OF THE ABDOMEN

Urinary System

The urinary bladder, trigone, cystourethral junction, and visible pelvic urethra exhibited normal thickness and tone. Anechoic urine was present in the lumen with no uroliths or sediment. The ureteral papillae were normal. The ureters were not visible which is normal. No evidence of inflammatory or neoplastic changes were noted.

Normal size and margination were present in the kidneys. A normal 1:3 cortex / medulla ratio and normal corticomedullary definition were maintained. The echogenicity of the cortex was similar to or slightly less than normal liver parenchyma while the medulla echogenicity was hypoechoic to the cortex with no evidence of pelvic dilatation. The left kidney measured 5.4 cm in length. The right kidney measured 4.9 cm in length.

The area of the aortic trifurcation was free of pathology.

Adrenal Glands

The left adrenal gland was uniform in size and contour with a uniformly hypoechoic parenchyma. The left adrenal gland measured 0.60 cm width at the caudal pole and 2.3 cm length. The right adrenal gland was uniform in size and contour with a uniformly hypoechoic parenchyma. The right adrenal gland measured 0.59 cm width at the caudal pole and 2.5 cm length.

Spleen

The spleen exhibited a finely textured and homogenous parenchyma which was hyperechoic to the liver and renal cortical parenchyma. The capsule was smooth and regular without apparent expansion. The splenic vasculature at the hilus was normal in volume with no evidence of congestion or thrombosis. Acute to chronic inflammatory, neoplastic, or benign parenchyma changes were not noted.

Liver/Gallbladder

The liver was subjectively normal in size, structure, and contour. The liver parenchyma was uniform and hypoechoic to the spleen with a mild coarse echotexture. The hepatic and portal vasculature were normal in appearance without signs of congestion. The gallbladder was non-distended in size with thin walls and primarily anechoic luminal content. The cystic and common bile ducts were normal.

Gastrointestinal

The stomach presented intact wall layering with a normal wall layer ratio. The lumen of the stomach was empty with no signs of ileus, obstruction or foreign material.



PATIENT

Ruthie Flannery

The small intestine presented intact wall layering with 1:3 muscularis/mucosa ratio. The lumen of the small intestine was empty with no signs of ileus, obstruction or foreign material.

Normal visible colon wall layers were present with apparent formed feces in lumen.

SPECIES

Canine

Pancreas

The parenchyma of the left limb, body and right limb of the pancreas presented isoechoic to the adjacent omental fat. A normal curvilinear capsule contour of the pancreas was present. The visible pancreatic duct was normal. No signs of active inflammation or neoplastic disease was evident.

BREED

Australian Shepherd

Free Abdomen

No omental masses, overt lymphadenopathy or peritoneal effusion was present.

SEX

FS

ULTRASONOGRAPHIC FINDINGS

- Sonographically unremarkable bilateral kidneys.
- Normal urinary bladder.
- Sonographically unremarkable GI tract.

AGE

3yr

INTERPRETATION OF THE FINDINGS & FURTHER RECOMMENDATIONS

Sonographically unremarkable abdomen without evidence of sonographically detectable renal pathology i.e., dysplasia, nephritis etc. Given the mild progressive increase in SDMA yet without evidence of azotemia, some degree of mild progressive microscopic or glomerular disease cannot be definitively excluded.

WEIGHT

50.2lb

Given no evidence of azotemia, conservative monitoring at this stage would be reasonable. A baseline UPC level could be considered if evidence of gross proteinuria is present on UA. An obvious cause of weight loss was not apparent. Further renal staging to include urine C/S and protein: creatinine ratio on sterile urine sample may be considered.

INTERPRETED BY

R. McKenzie Daniel,
DVM, DABVP
(Canine and Feline)

IMAGING PERFORMED BY

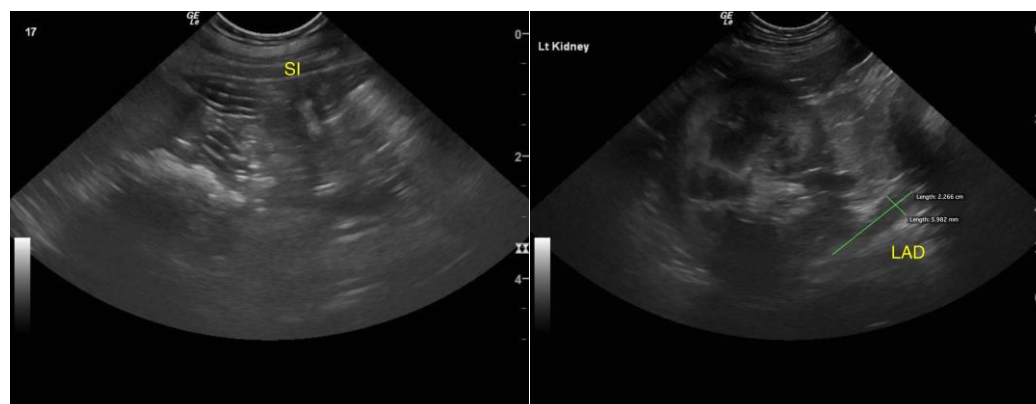
Graham Sager-Gellerman, DVM

HOSPITAL NAME

Back Bay Veterinary
Clinic

REFERRING VET

Tess Gannaway, DVM



INVOICE

13618ag

DATE

04/28/2023



PATIENT

Ruthie Flannery

SPECIES

Canine

BREED

Australian Shepherd

SEX

FS

AGE

3yr

WEIGHT

50.2lb

INTERPRETED BY

R. McKenzie Daniel,
DVM, DABVP
(Canine and Feline)

IMAGING PERFORMED BY

Graham Sager-Gellerman, DVM

HOSPITAL NAME

Back Bay Veterinary
Clinic

REFERRING VET

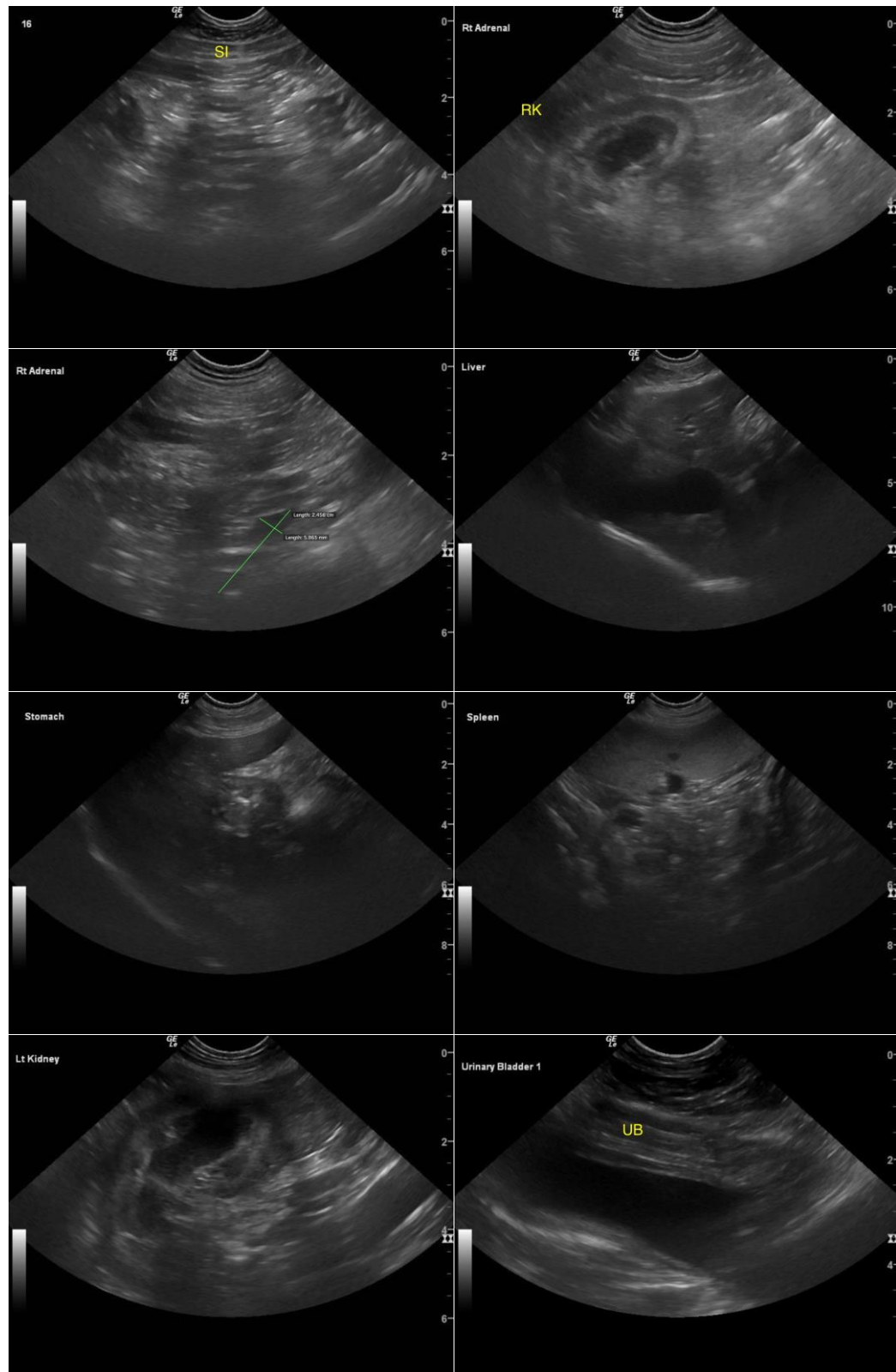
Tess Gannaway, DVM

INVOICE

13618ag

DATE

04/28/2023



The information and recommendations provided are based on the images presented by the referring veterinarian/sonographer. No evaluation can be communicated regarding pathology that was not



PATIENT

Ruthie Flannery

visible in the image/video clips provided.

Thank you for this referral. If the clinical or image interpretation does not parallel your findings or if I can be of any further assistance, please contact me.

SPECIES

Canine

R. McKenzie Daniel, DVM, DABVP (Canine/Feline Practice)
mac.daniel@sonopath.com

BREED

Australian Shepherd

SEX

FS

AGE

3yr

WEIGHT

50.2lb

INTERPRETED BY

R. McKenzie Daniel,
DVM, DABVP
(Canine and Feline)

**IMAGING
PERFORMED BY**

Graham Sager-
Gellerman, DVM

HOSPITAL NAME

Back Bay Veterinary
Clinic

REFERRING VET

Tess Gannaway, DVM

INVOICE

13618ag

DATE

04/28/2023