



<b>PATIENT</b>	<b>PRESENTING CLINICAL SIGNS</b>
"Dagney" Jakubowicz	1 year recheck, history of hyperthyroid, and renal disease. Current meds: Methimazole. Previous ultrasound performed on 5/24/22.
<b>SPECIES</b>	Abnormal PE/Chem/CBC/UA Results: Recheck blood work, ECG pending. Thyroid level 2/25/23 - WNL. Most recent blood work from CBC/Chem 1/4/23: RBC 7.03, SDMA 15, creat. 3.2, BUN 48, ALT 19, chol. 368, amylase 2629, Free T4 < 0.3, Free T4 < 3.9.
Feline	
<b>BREED</b>	<b>ULTRASONOGRAPHIC EXAMINATION OF THE ABDOMEN</b>
DSH	<b>Urinary System</b>
<b>SEX</b>	The urinary bladder, trigone, cystourethral junction, and visible pelvic urethra to a depth of 2 cm exhibited normal thickness and tone. Anechoic urine was present in the lumen with mild non-dependent particulate to mildly hyperechoic sediment. The sediment may indicate cellular debris / protein, crystalline debris, lipid, or mucus. The ureteral papillae were normal. The ureters were not visible which is normal. No evidence of inflammatory or neoplastic changes were noted.
FS	
<b>AGE</b>	Normal size and margination were present in the kidneys. A normal 1:3 cortex / medulla ratio was maintained. The medulla and cortices were uniform in texture with some increased echogenicity and moderate loss of corticomedullary symmetry and definition expected for the age of the patient. No evidence of pelvic dilation was present. Static previously noted cranial left kidney cortical cyst was present. The left kidney measured 3.5 cm in length. The right kidney measured 3.3 cm in length.
15yr	
<b>WEIGHT</b>	The area of the aortic trifurcation was free of pathology.
10lb	<b>Adrenal Glands</b>
<b>INTERPRETED BY</b>	No overt pathology in the area of the left adrenal gland. The right adrenal gland was uniform in size and contour with a uniformly hypoechoic parenchyma. The right adrenal gland measured 0.48 cm width.
R. McKenzie Daniel, DVM, DABVP (Canine and Feline)	<b>Spleen</b>
<b>IMAGING PERFORMED BY</b>	The spleen exhibited a finely textured and homogenous parenchyma which was hyperechoic to the liver and renal cortical parenchyma. The capsule was smooth and regular without apparent expansion. The splenic vasculature at the hilus was normal in volume with no evidence of congestion or thrombosis. Acute to chronic inflammatory, neoplastic, or benign parenchyma changes were not noted.
Kelly Vazquez	<b>Liver/Gallbladder</b>
<b>HOSPITAL NAME</b>	The liver presented normal in size. The parenchyma of the liver was subjectively normal in echogenicity compared to the spleen and renal cortices with mild parenchymal remodeling. The liver parenchyma was uniform with a mildly coarse echotexture. The capsule of the liver was symmetrically rounded to mildly swollen in margination. The hepatic and portal vasculature were normal in appearance without signs of congestion. The gallbladder was non-distended in size with primarily anechoic luminal content and mild non-organized echogenic debris in the caudal lumen of the gallbladder neck. The cystic and common bile ducts were normal.
Marsh Hospital for Animals	<b>Gastrointestinal</b>
<b>REFERRING VET</b>	The stomach presented intact wall layering with a normal wall layer ratio. The lumen of the stomach was empty with no signs of ileus, obstruction or foreign material.
Dr. Milwicki	
<b>INVOICE</b>	
13625ag	
<b>DATE</b>	
04/28/2023	



<b>PATIENT</b>	The small intestine presented intact wall layering with 1:3 muscularis/mucosa ratio. The lumen of the small intestine is empty with no signs of ileus, obstruction or foreign material.
"Dagney" Jakubowicz	Normal visible colon wall layers were present with apparent formed feces in lumen.
<b>SPECIES</b>	<b>Pancreas</b>
Feline	The pancreas base and left pancreatic limb exhibited mild variable prominent size with capsule asymmetry and non-uniform nodular parenchyma. No evidence of peri pancreatic omental reactivity or inflammation.
<b>BREED</b>	<b>Free Abdomen</b>
DSH	No omental masses, overt lymphadenopathy or peritoneal effusion was present.
<b>SEX</b>	<b>ULTRASONOGRAPHIC FINDINGS</b>
FS	<ul style="list-style-type: none"> <li>• Static chronic renal change with previously noted left kidney cortical cyst.</li> <li>• Variably prominent to irregular non-uniform/nodular pancreas.</li> <li>• Minor hepatic parenchyma remodeling with mild gallbladder debris.</li> <li>• Minor urinary bladder sediment.</li> </ul>
<b>AGE</b>	<b>INTERPRETATION OF THE FINDINGS &amp; FURTHER RECOMMENDATIONS</b>
15yr	Further renal staging to include urine C/S and protein: creatinine ratio on sterile urine sample may be considered.
<b>WEIGHT</b>	
10lb	The pancreas was non-specific and may indicate chronic to chronic active possibly mixed pattern pancreatitis with subtle areas of hyperplasia. Pancreatic neoplastic criteria is considered unlikely. Assessment for evidence of cranial abdominal/subxiphoid discomfort on palpation which may allude to low grade pancreatitis +/- spec fPL is recommended if clinal signs consistent with pancreatitis have been noted or develop.
<b>INTERPRETED BY</b>	Otherwise, a largely geriatric abdomen. CKD therapy if concurrent inadequate urinary concentration may be considered.
R. McKenzie Daniel, DVM, DABVP (Canine and Feline)	

**IMAGING PERFORMED BY**

Kelly Vazquez

**HOSPITAL NAME**

Marsh Hospital for Animals

**REFERRING VET**

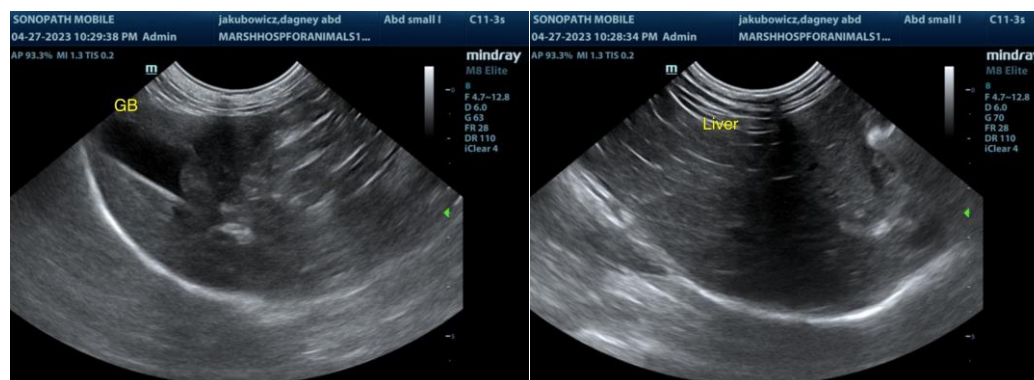
Dr. Milwicki

**INVOICE**

13625ag

**DATE**

04/28/2023





**PATIENT**  
"Dagney" Jakubowicz

**SPECIES**

Feline

**BREED**

DSH

**SEX**

FS

**AGE**

15yr

**WEIGHT**

10lb

**INTERPRETED BY**

R. McKenzie Daniel,  
DVM, DABVP  
(Canine and Feline)

**IMAGING PERFORMED BY**

Kelly Vazquez

**HOSPITAL NAME**

Marsh Hospital for  
Animals

**REFERRING VET**

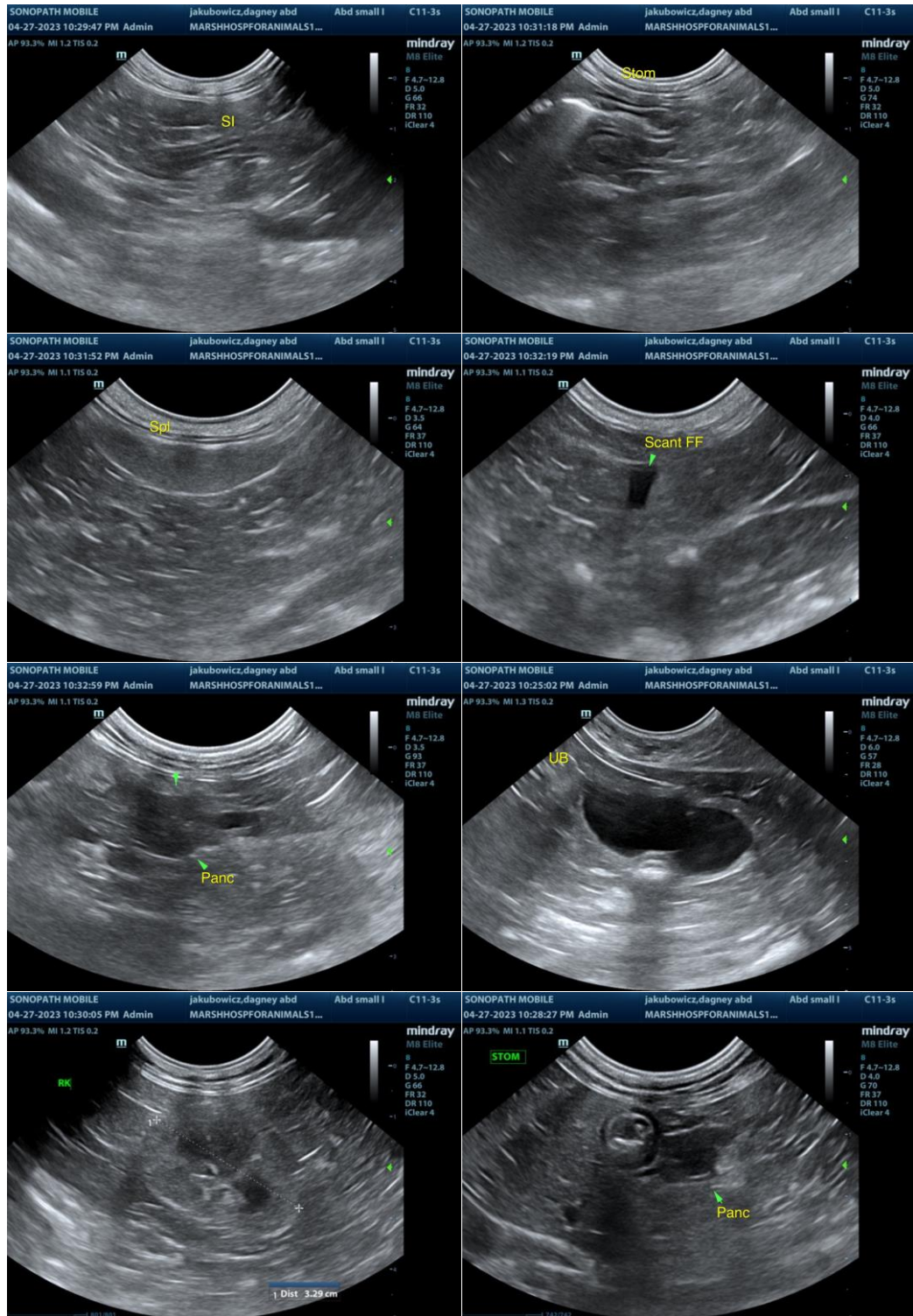
Dr. Milwicki

**INVOICE**

13625ag

**DATE**

04/28/2023





**PATIENT**

"Dagney" Jakubowicz

**SPECIES**

Feline

**BREED**

DSH

**SEX**

FS

**AGE**

15yr

**WEIGHT**

10lb

**INTERPRETED BY**

R. McKenzie Daniel,  
DVM, DABVP  
(Canine and Feline)

**IMAGING PERFORMED BY**

Kelly Vazquez

**HOSPITAL NAME**

Marsh Hospital for  
Animals

**REFERRING VET**

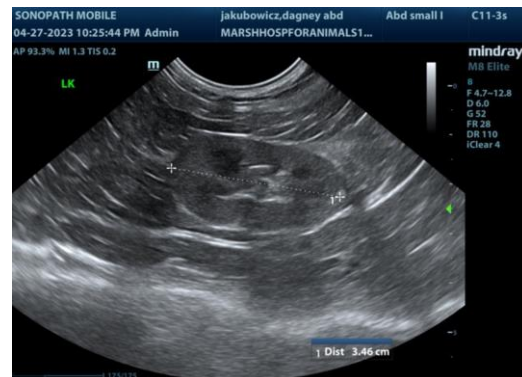Dr. Milwicki

**INVOICE**

13625ag

**DATE**

04/28/2023



The information and recommendations provided are based on the images presented by the referring veterinarian/sonographer. No evaluation can be communicated regarding pathology that was not visible in the image/video clips provided.

Thank you for this referral. If the clinical or image interpretation does not parallel your findings or if I can be of any further assistance, please contact me.

R. McKenzie Daniel, DVM, DABVP (Canine/Feline Practice)  
[mac.daniel@sonopath.com](mailto:mac.daniel@sonopath.com)