



PATIENT

Biggie Puglisi

PRESENTING CLINICAL SIGNS

3/6 murmur

SPECIES

Canine

BREED

Cavalier King Charles Spaniel

SEX

MN

AGE

6yr

WEIGHT

20.9lb

INTERPRETED BY

R. McKenzie Daniel,
DVM, DABVP
(Canine and Feline)

IMAGING PERFORMED BY

Diane McFadden

HOSPITAL NAME

Sova Animal Hospital

REFERRING VET

Dr Ammeraal

INVOICE

13621ag

DATE

04/28/2023

ULTRASONOGRAPHIC EXAMINATION OF THE HEART

CANINE CARDIAC PARAMETERS	MR VMAX (m/s)	TR VMAX (m/s)	LA/AO (Boon method)	LA/AO (Heart Base; Swe)	FS (%)	EF (%)	EPSS (cm)
NORMAL PARAMETER	4.5-5.5	<2.7	1.3	<1.3	28-40	40-100	<0.6
PATIENT	5.5			1.4	46	78.6	0.2
CANINE CARDIAC PARAMETERS	HR (BPM)	AV VMAX (m/s)	PV MAX (m/s)	BODY WEIGHT (kg)	LA 2D short axis Base view (cm)	LVIDd Avg; 2D and m-mode short axis (cm)	LVIDs Avg; 2D and m-mode short axis (cm)
NORMAL PARAMETER	50-100	0.7-1.7	0.7-1.6				
PATIENT	117	1.0	1.0		2.8	3.0	

Cardiac Presentation

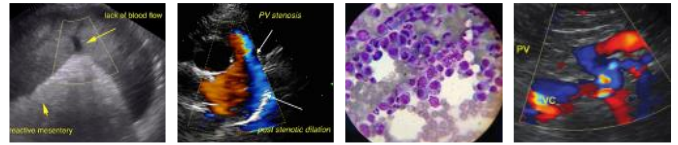
The echocardiogram in this patient demonstrated normal left atrial size based on 3 different LA measurement methods. Chamber volumes and echogenicity were normal. The cranial and caudal mitral valve leaflets presented vegetative thickening consistent with endocardiosis. Doppler indicated measurable insufficiency. The left ventricle presented thicknesses with linear contour and was not dilated nor restricted. The myocardium presented normal echogenicity without subjective evidence of significant fibrotic or ischemic disease. Contractility of the ventricular walls was adequate and in normal range for this patient evidenced by the fractional shortening measurement and subjective evaluation of the different regions of the myocardium. The left ventricular outflow tract demonstrated normal laminar flow and subjective structural integrity. The right atrium and auricle revealed normal size, structure and content. No evidence of masses was noted or chamber overload. Tricuspid valvular assessment demonstrated adequate linear morphology. The right ventricle was of normal size (1/3 diameter of LV), chordae structure, myocardial echogenicity and thickness. Pulmonic tract assessment revealed normal valve structure, laminar flow, and diameter (approx.1:1 pa/ao ratio). No visible pericardial or free pleura fluid was noted. No echographically detectable evidence of infiltrative disease was visible. The cranial mediastinum and pericardial regions were free of masses in the visible window.

ULTRASONOGRAPHIC FINDINGS

- Chronic mitral valve disease (ACVIM B1)

INTERPRETATION OF THE FINDINGS & FURTHER RECOMMENDATIONS

The cause of the murmur is chronic degenerative valvular changes with secondary eccentric mitral valve insufficiency. The lack of left atrial enlargement implies that the risk of complication secondary to mitral valve insufficiency is relatively low at this time and, without current clinical signs, indicates



PATIENT

Biggie Puglisi

that medical therapy is not required at this stage. Prognosis at this stage is highly variable and serial sonographic monitoring is recommended given the breed with a recheck echocardiogram in 6 months, sooner if clinically indicated.

SPECIES

Canine

BREED

Cavalier King Charles Spaniel

SEX

MN

AGE

6yr

WEIGHT

20.9lb

INTERPRETED BY

R. McKenzie Daniel, DVM, DABVP (Canine and Feline)

IMAGING PERFORMED BY

Diane McFadden

HOSPITAL NAME

Sova Animal Hospital

REFERRING VET

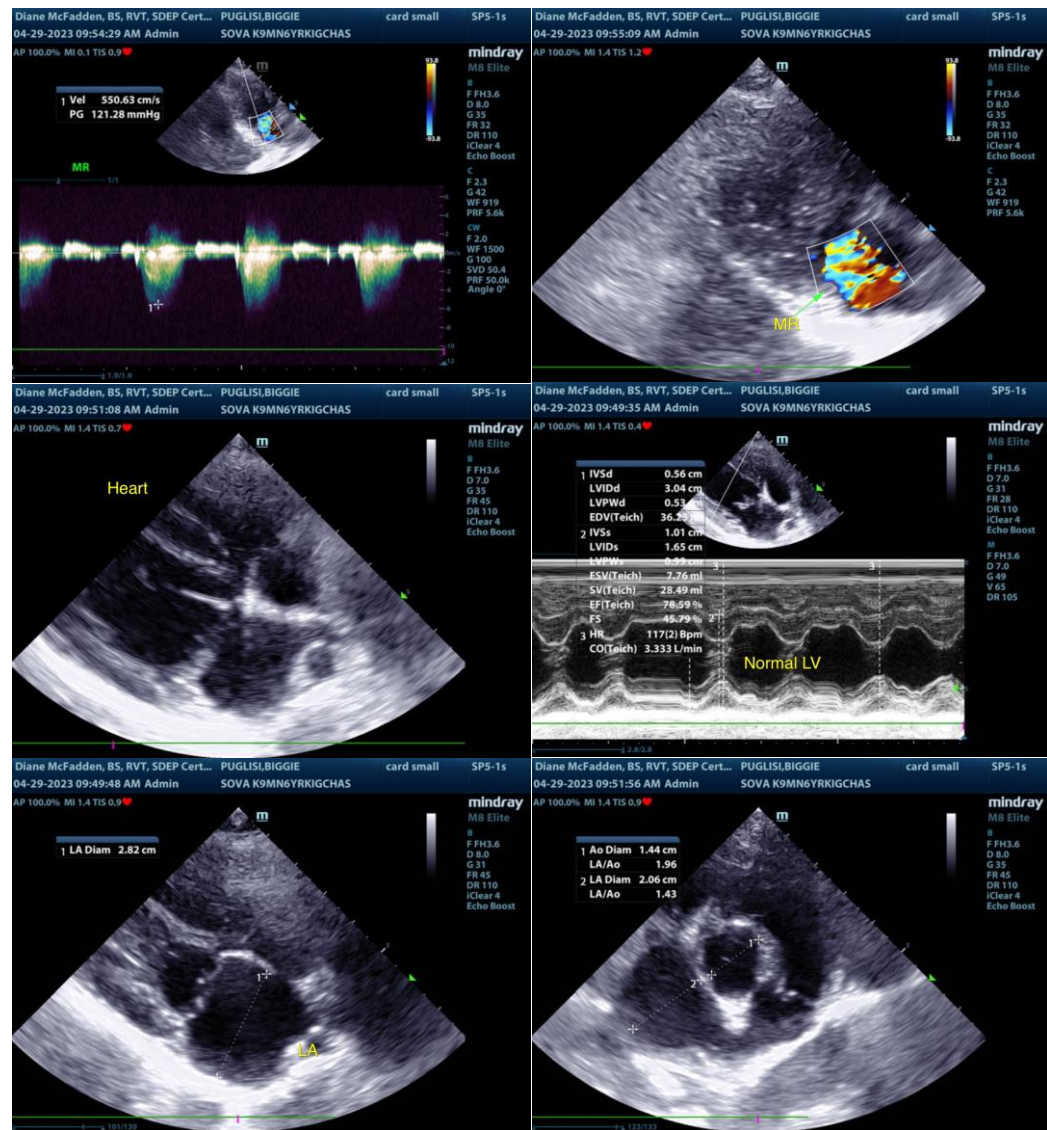
Dr Ammeraal

INVOICE

13621ag

DATE

04/28/2023



The information and recommendations provided are based on the images presented by the referring veterinarian/sonographer. No evaluation can be communicated regarding pathology that was not visible in the image/video clips provided.

Thank you for this referral. If the clinical or image interpretation does not parallel your findings or if I can be of any further assistance, please contact me.

R. McKenzie Daniel, DVM, DABVP (Canine/Feline Practice)
mac.daniel@sonopath.com



PATIENT

Biggie Puglisi

SPECIES

Canine

BREED

Cavalier King Charles
Spaniel

SEX

MN

AGE

6yr

WEIGHT

20.9lb

INTERPRETED BY

R. McKenzie Daniel,
DVM, DABVP
(Canine and Feline)

**IMAGING
PERFORMED BY**

Diane McFadden

HOSPITAL NAME

Sova Animal Hospital

REFERRING VET

Dr Ammeraal

INVOICE

13621ag

DATE

04/28/2023