

**PATIENT**

Tucker Puffer

**SPECIES**

Canine

**BREED**

Lab

**SEX**

NM

**AGE**

7 years

**WEIGHT**

110 lbs.

**INTERPRETED BY**R. McKenzie Daniel,  
DVM, DABVP  
(Canine and Feline)**IMAGING  
PERFORMED BY**

Sarah Pender, CVT

**HOSPITAL NAME**

SVS Imaging QC

**REFERRING VET**

Isaac Jepsen

**INVOICE**

13767

**DATE**

4/28/22

**PRESENTING CLINICAL SIGNS**

inappetence, heavy panting and drooling for the last 3 weeks. He is acting more lethargic and in general just not acting himself.

Abnormal PE/Chem/CBC/UA Results: overweight canine with a benign lipoma and perhaps slightly yellowed gums. Bloodwork revealed an inflammatory leukogram, with elevated liver enzymes

**ULTRASONOGRAPHIC EXAMINATION OF THE ABDOMEN****Urinary System**

The urinary bladder, trigone, and cystourethral junction exhibited normal thickness and tone. Anechoic urine was present in the lumen with no uroliths or sediment. The ureteral papillae were normal. The ureters were not visible which is normal. No evidence of inflammatory or neoplastic changes was noted.

The area of the aortic trifurcation was free of pathology.

Normal size and margination were present in the kidneys. A normal 1:3 cortex / medulla ratio and normal corticomedullary definition were maintained. The echogenicity of the cortex was similar to or slightly less than normal liver parenchyma while the medulla echogenicity was hypoechoic to the cortex with no evidence of pelvic dilation. The left kidney measured 7.2 cm in length. The right kidney measured 6.8 cm in length.

**Adrenal Glands**

The left adrenal gland exhibited mild subnormal size with normal position. The left adrenal gland measured 2.6 cm length x 0.36 cm width at the caudal pole. The right adrenal gland was uniform in size and contour with a uniformly hypoechoic parenchyma. The right adrenal gland measured 2.6 cm length x 0.47 cm width at the caudal pole.

**Spleen**

The spleen exhibited normal splenic contour and size with a primarily maintained finely textured and homogenous parenchyma which was hyperechoic to the liver and renal cortical parenchyma. The capsule was smooth and regular without apparent expansion. The splenic vasculature at the hilus was normal in volume with no evidence of congestion or thrombosis. Acute to chronic inflammatory, neoplastic, or benign parenchyma changes were not noted. A solitary, subtly hypoechoic, nondisruptive nodule was present in the medial spleen measuring 0.54 cm in diameter.

**Liver/ Gallbladder**

A large, expansive, nonhomogeneous mass occupying the majority of the mid to left liver extending caudally into the cranial to mid abdomen at the approximate level of the gastric axis was present. The liver mass measured approximately 12.0-13.0 cm in diameter. Normal-appearing hepatic parenchyma was present in the mid to right liver and adjacent to the gallbladder. No evidence of post hepatic obstruction was noted. The gallbladder was non-distended in size with thin walls and primarily anechoic luminal content. The cystic and common bile ducts were normal.

**PATIENT*****Gastrointestinal***

Tucker Puffer

The stomach presented intact wall layering with a normal wall layer ratio. The lumen of the stomach was empty with no signs of ileus, obstruction, or foreign material.

**SPECIES**

Canine

The small intestine presented intact wall layering with 1:3 muscularis/mucosa ratio. The lumen of the small intestine was empty with no signs of ileus, obstruction, or foreign material.

Normal visible colon wall layers were present with apparent formed feces in lumen.

**BREED**

Lab

***Pancreas***

The parenchyma of the left limb, body, and right limb of the pancreas presented isoechoic to the adjacent omental fat. A normal curvilinear capsule contour of the pancreas was present. The visible pancreatic duct was normal. No signs of active inflammation or neoplastic disease were evident.

**SEX**

NM

***Free Abdomen***

No evidence of lymphadenopathy or peritoneal effusion was present.

**AGE**

7 years

**ULTRASONOGRAPHIC FINDINGS**

- A large, expansive to nonhomogeneous mid to left liver mass
- A solitary, subtly hypoechoic nondisruptive splenic nodule
- Overtly normal gastrointestinal tract

**WEIGHT**

110 lbs.

**INTERPRETATION OF THE FINDINGS & FURTHER RECOMMENDATIONS****INTERPRETED BY**

R. McKenzie Daniel,  
DVM, DABVP  
(Canine and Feline)

Although sampling is required for further assessment, the liver mass is suggestive of neoplastic criteria, i.e., carcinoma or other with non-neoplastic etiology such as severe hyperplasia, hematopoiesis, and granuloma considered less likely. Assuming normal clotting status, ultrasound-guided FNA of the liver mass is recommended for screening cytology. A core surgical biopsy may be required for a definitive diagnosis. Complete surgical resectability of the hepatic mass is questionable, given its size and likely involvement of more than one liver lobe.

**IMAGING PERFORMED BY**

Sarah Pender, CVT

The splenic nodule, although nonspecific, is suggestive of a focal area of splenic lymphoid hyperplasia or hematopoiesis without overt evidence of neoplastic criteria, which is thought less likely.

**HOSPITAL NAME**

SVS Imaging QC

Continued gastrointestinal support is recommended. Three view chest radiographs are suggested if not done.

**REFERRING VET**

Isaac Jepsen

**INVOICE**

13767

**DATE**

4/28/22



**PATIENT**

Tucker Puffer

**SPECIES**

Canine

**BREED**

Lab

**SEX**

NM

**AGE**

7 years

**WEIGHT**

110 lbs.

**INTERPRETED BY**

R. McKenzie Daniel, DVM, DABVP (Canine and Feline)

**IMAGING PERFORMED BY**

Sarah Pender, CVT

**HOSPITAL NAME**

SVS Imaging QC

**REFERRING VET**

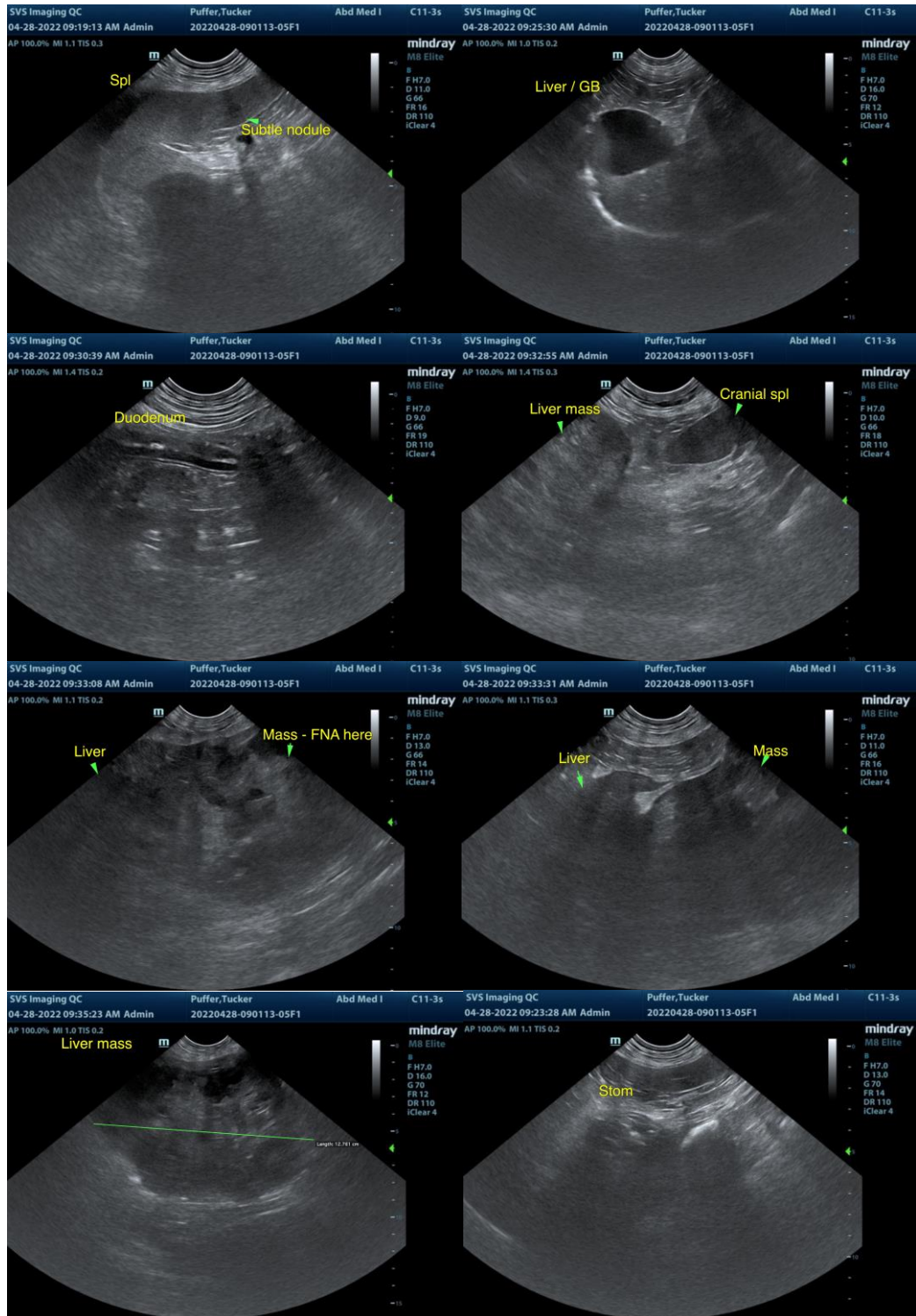
Isaac Jepsen

**INVOICE**

13767

**DATE**

4/28/22





**PATIENT**

Tucker Puffer

**SPECIES**

Canine

**BREED**

Lab

**SEX**

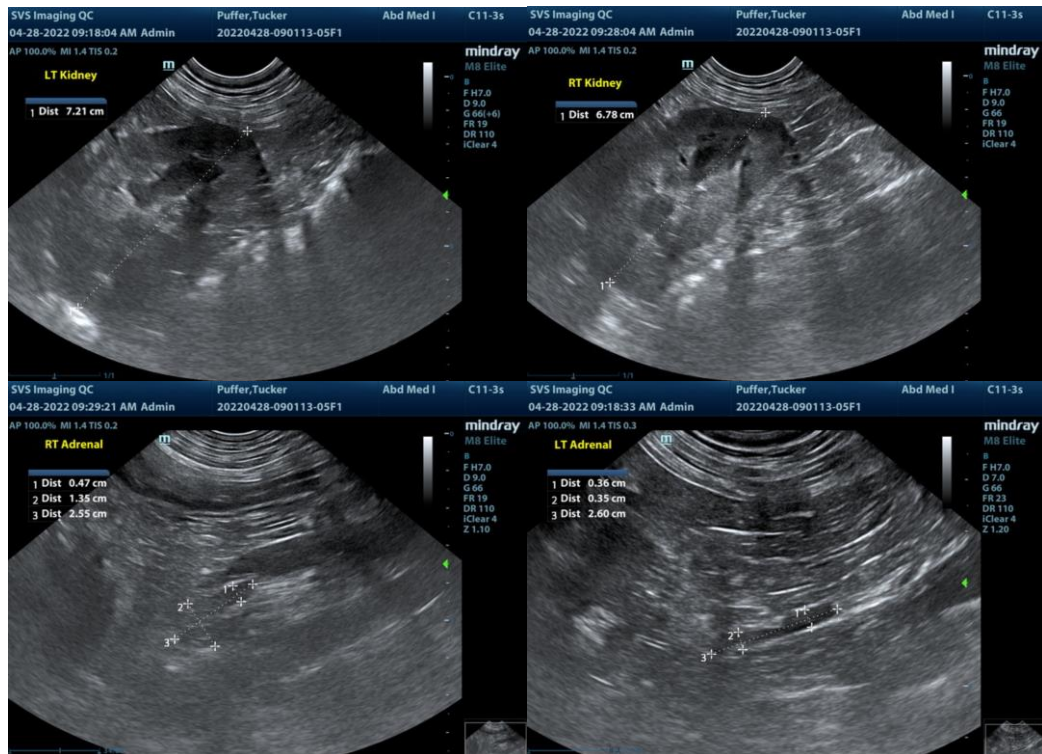
NM

**AGE**

7 years

**WEIGHT**

110 lbs.



**INTERPRETED BY**

R. McKenzie Daniel,  
DVM, DABVP  
(Canine and Feline)

**IMAGING PERFORMED BY**

Sarah Pender, CVT

**HOSPITAL NAME**

SVS Imaging QC

**REFERRING VET**

Isaac Jepsen

**INVOICE**

13767

**DATE**

4/28/22

**The information and recommendations provided are based on the images presented by the referring veterinarian/sonographer. No evaluation can be communicated regarding pathology that was not visible in the image/video clips provided.**

Thank you for this referral. If the clinical or image interpretation does not parallel your findings or if I can be of any further assistance please contact me.

**R. McKenzie Daniel, DVM, DABVP (Canine / Feline Practice)**  
**info@SonoPath.com**