



PATIENT

Apex Steindorf

SPECIES

Canine

BREED

Husky

SEX

MN

AGE

5 years

WEIGHT

68 lbs.

INTERPRETED BY

R. McKenzie Daniel,
DVM, DABVP
(Canine and Feline)

**IMAGING
PERFORMED BY**

Sara Hansen

HOSPITAL NAME

Albany Animal
Hospital

REFERRING VET

Dr. Fletcher

INVOICE

13756

DATE

4/28/22

PRESENTING CLINICAL SIGNS

Refusing food/appetite fluctuates/eating grass Vomiting Tacky/dark stool

ULTRASONOGRAPHIC EXAMINATION OF THE ABDOMEN

Urinary System

The urinary bladder, trigone, cystourethral junction, and visible pelvic urethra to a depth of 2.0 cm exhibited normal thickness and tone. Anechoic urine was present in the lumen with no uroliths or sediment. The ureteral papillae were normal. The ureters were not visible which is normal. No evidence of inflammatory or neoplastic changes was noted.

The residual prostate was normal in appearance measuring 0.97 cm in diameter.

The area of the aortic trifurcation was free of pathology and without evidence of medial iliac or sublumbar lymphadenopathy.

Normal size and margination were present in the kidneys. A normal 1:3 cortex / medulla ratio and normal corticomedullary definition were maintained. The echogenicity of the cortex was similar to or slightly less than normal liver parenchyma while the medulla echogenicity was hypoechoic to the cortex with no evidence of pelvic dilation. The left kidney measured 7.0 cm in length. The right kidney measured 7.2 cm in length.

Adrenal Glands

The left adrenal gland was uniform in size and contour with a uniformly hypoechoic parenchyma. The left adrenal gland measured 2.3 cm length x 0.52 cm width at the caudal pole. The right adrenal gland was uniform in size and contour with a uniformly hypoechoic parenchyma. The right adrenal gland measured 2.5 cm length x 0.35 cm width at the caudal pole.

Spleen

The spleen exhibited a finely textured and homogenous parenchyma which was hyperechoic to the liver and renal cortical parenchyma. The capsule was smooth and regular without apparent expansion. The splenic vasculature at the hilus was normal in volume with no evidence of congestion or thrombosis. Acute to chronic inflammatory, neoplastic, or benign parenchyma changes were not noted.

Liver/ Gallbladder

The liver was subjectively normal in size, structure, and contour. The liver parenchyma was uniform and hypoechoic to the spleen with a mild coarse echotexture. The hepatic and portal vasculature were normal in appearance without signs of congestion. The gallbladder was non-distended in size with thin walls and primarily anechoic luminal content. The cystic and common bile ducts were normal.



PATIENT

Apex Steindorf

SPECIES

Canine

BREED

Husky

SEX

MN

AGE

5 years

WEIGHT

68 lbs.

INTERPRETED BY

R. McKenzie Daniel,
DVM, DABVP
(Canine and Feline)

IMAGING PERFORMED BY

Sara Hansen

HOSPITAL NAME

Albany Animal
Hospital

REFERRING VET

Dr. Fletcher

INVOICE

13756

DATE

4/28/22

Gastrointestinal

The stomach presented intact wall layering with a normal wall layer ratio. The lumen of the stomach was empty with no signs of ileus, obstruction, or foreign material. The gastric body wall width measured 0.35 cm.

The small intestine presented intact wall layering with 1:3 muscularis/mucosa ratio. The lumen of the small intestine was empty with no signs of ileus, obstruction, or foreign material. The duodenum wall width measured 0.43 cm. The jejunum wall width measured 0.36 cm.

Normal visible colon wall layers were present with apparent formed feces in lumen.

Pancreas

The parenchyma of the left limb, body, and right limb of the pancreas presented isoechoic to the adjacent omental fat. A normal curvilinear capsule contour of the pancreas was present. The visible pancreatic duct was normal. No signs of active inflammation or neoplastic disease were evident.

Free Abdomen

Previously noted, midabdominal mesenteric lymph nodes were present subjectively in the area of the ileoceocolic junction and proximal colon. The lymph nodes exhibited symmetrical to rounded margination with abnormal width: length ratio (>0.5). The enlarged lymph nodes were bordered by echogenic to reactive mesentery. The mesenteric root lymph nodes measured 4.2 cm x 2.8 cm. No evidence of peritoneal free fluid was noted.

ULTRASONOGRAPHIC FINDINGS

- Persistent hypoechoic to asymmetrically swollen midabdominal mesenteric lymphadenopathy with perilymphatic reactive mesentery - inflammatory vs. neoplastic criteria possible
- Continued sonographically unremarkable gastrointestinal tract and colon

INTERPRETATION OF THE FINDINGS & FURTHER RECOMMENDATIONS

Pending lymphatic cytology, recommended for further clarification, potential for oncology consultation if neoplastic process is confirmed. No overt evidence of inflammatory or neoplastic gastrointestinal tract mural changes was noted. However, the sonographic appearance of the gastrointestinal tract does not always correlate with reported gastrointestinal signs.

Three view chest radiographs could be considered if not recently done. Continued gastrointestinal support, as well as gastroprotectant protocol, given potential for melena, is recommended. Pending cytology, potential lymphatic +/- gastrointestinal biopsies may be required for a definitive diagnosis.



PATIENT

Apex Steindorf

SPECIES

Canine

BREED

Husky

SEX

MN

AGE

5 years

WEIGHT

68 lbs.

INTERPRETED BY

R. McKenzie Daniel,
DVM, DABVP
(Canine and Feline)

IMAGING PERFORMED BY

Sara Hansen

HOSPITAL NAME

Albany Animal
Hospital

REFERRING VET

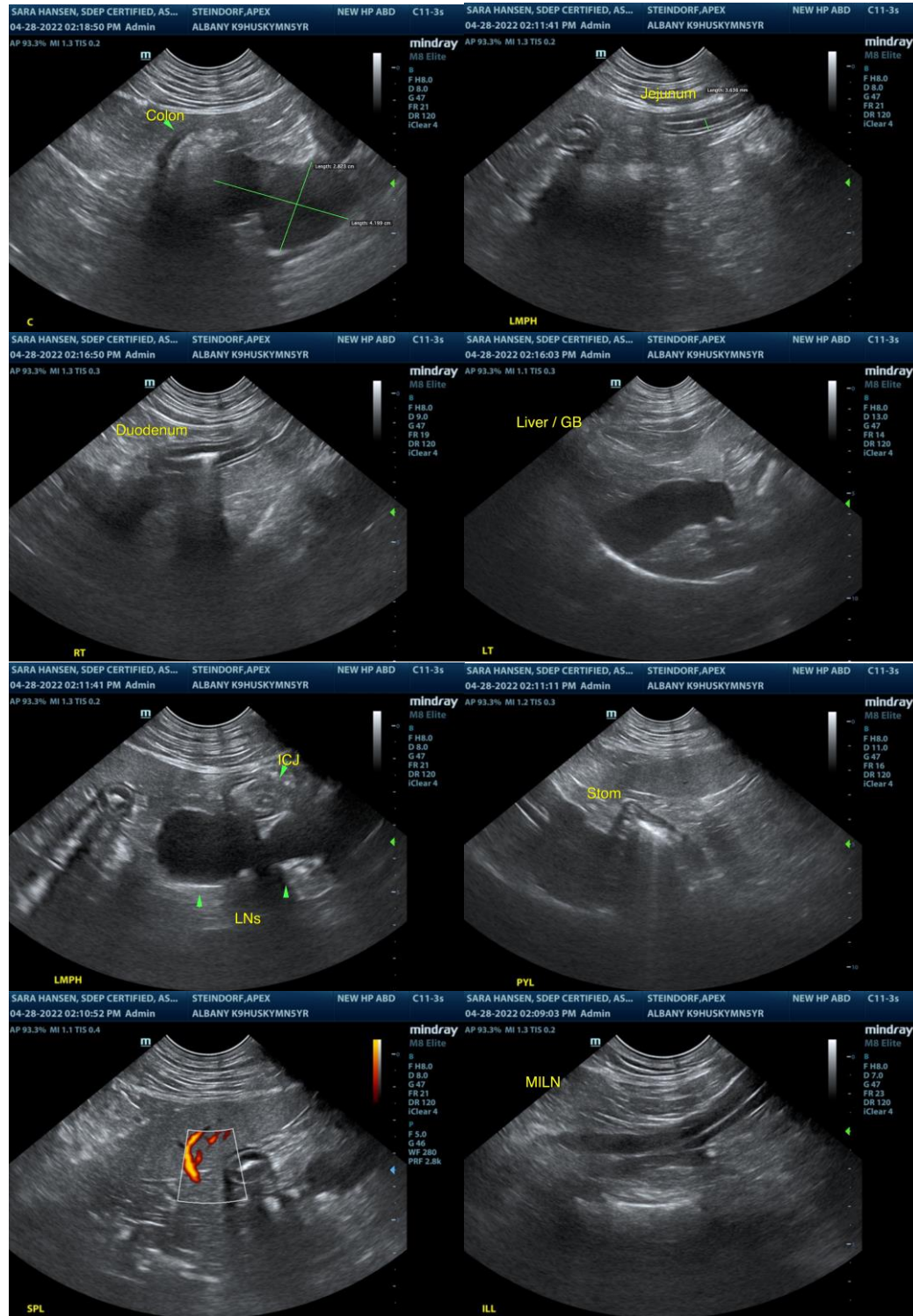
Dr. Fletcher

INVOICE

13756

DATE

4/28/22





PATIENT

Apex Steindorf

SPECIES

Canine

BREED

Husky

SEX

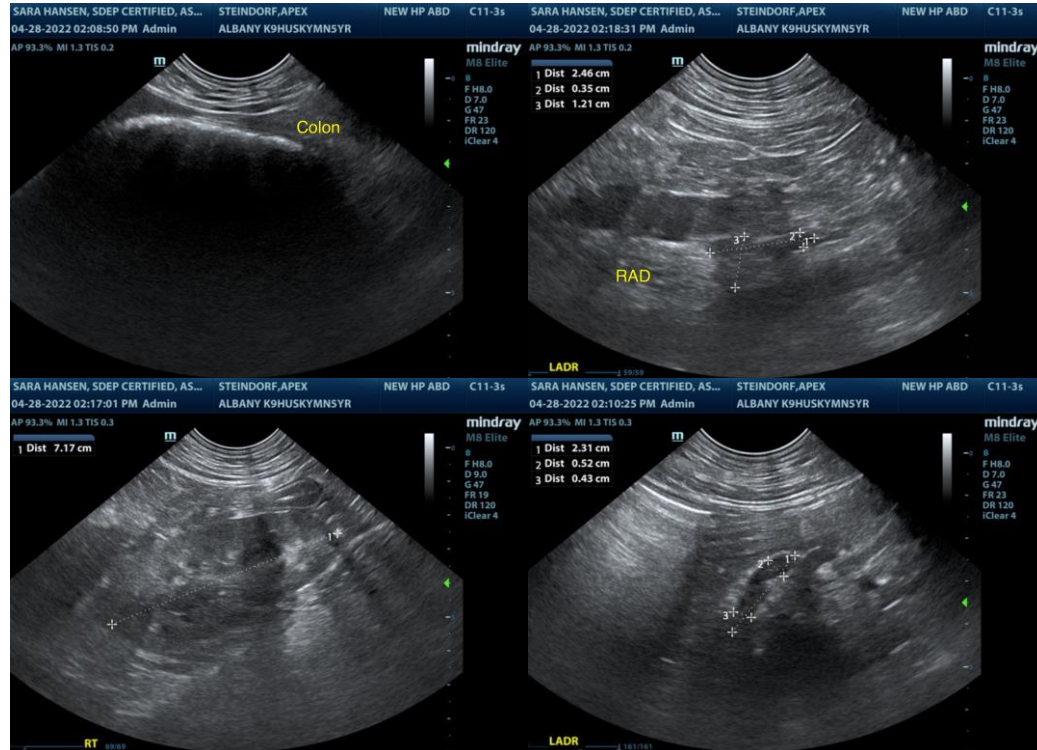
MN

AGE

5 years

WEIGHT

68 lbs.



INTERPRETED BY

R. McKenzie Daniel,
DVM, DABVP
(Canine and Feline)

IMAGING PERFORMED BY

Sara Hansen

The information and recommendations provided are based on the images presented by the referring veterinarian/sonographer. No evaluation can be communicated regarding pathology that was not visible in the image/video clips provided.

Thank you for this referral. If the clinical or image interpretation does not parallel your findings or if I can be of any further assistance please contact me.

HOSPITAL NAME

Albany Animal
Hospital

R. McKenzie Daniel, DVM, DABVP (Canine / Feline Practice)
info@SonoPath.com

REFERRING VET

Dr. Fletcher

INVOICE

13756

DATE

4/28/22