



PATIENT

Emma Tone

SPECIES

Canine

BREED

German Shepherd X

SEX

FS

AGE

13 yrs

WEIGHT

103 lbs

INTERPRETED BY

R. McKenzie Daniel,
DVM, DABVP
(Canine and Feline)

IMAGING PERFORMED BY

Jenna Walsh, CVT

HOSPITAL NAME

Santa Clara AH

REFERRING VET

Dr. Zulauf

INVOICE

16410

DATE

4/27/23

PRESENTING CLINICAL SIGNS

Edematous right leg with pain on palpation pale mucous membranes abdomen palpates normally FAST scan - no free fluid in the abdomen. nodules in liver Current Medications meloxicam

Radiographic Findings Possible mass in cranial abdomen. Lungs appear normal. hind legs appear normal Primary Question/Differential to Be Answered in This Exam evidence for cause of anemia?

Abnormal PE/Chem/CBC/UA Results: HCT 19.2% PLTs 74,000 but appeared adequate on blood smear WBCs elevated at 21,200

ULTRASONOGRAPHIC EXAMINATION OF THE ABDOMEN

Urinary System

The urinary bladder, trigone, cystourethral junction, and visible pelvic urethra to a depth of 4.0 cm exhibited normal thickness and tone. Anechoic urine was present in the lumen with no uroliths or sediment. The ureteral papillae were normal. The ureters were not visible which is normal. No evidence of inflammatory or neoplastic changes was noted.

The area of the aortic trifurcation was free of pathology.

Normal size and margination were present in the kidneys. A normal 1:3 cortex / medulla ratio was maintained. The medulla and cortices were uniform in texture with some increased echogenicity and mild loss of corticomedullary symmetry and definition expected for the age of the patient. No evidence of pelvic dilation was present. The left kidney measured 7.7 cm in length. The right kidney measured 8.0 cm in length.

Adrenal Glands

The left adrenal gland was uniform in size and contour with a uniformly hypoechoic parenchyma. The left adrenal gland measured 3.1 cm length x 0.78 cm width at the caudal pole. The right adrenal gland was uniform in size and contour with a uniformly hypoechoic parenchyma. The right adrenal gland measured 3.0 cm length x 0.64 cm width at the caudal pole.

Spleen

The spleen exhibited mild generalized enlargement with areas of capsule asymmetry and nonhomogeneous to mild moth-eaten parenchyma exhibiting diffuse hypoechoic micronodular parenchyma changes. Within the mid to caudal aspect of the medial spleen, a mild expansive, nonhomogeneous mass lesion was present measuring 4.6 cm in diameter. The mass lesion distorted the splenic capsule without overt evidence of parenchymal escape. Overall normal hepatic vascularity was noted on Doppler.

Liver/ Gallbladder

The liver was enlarged with an asymmetrical capsule contour. The liver exhibited marked nonhomogeneous / nodular parenchyma with intermittent intraparenchymal cysts. A small nonhomogeneous mildly expansive intraparenchymal mass lesion was present in the ventral left liver



PATIENT

Emma Tone

SPECIES

Canine

BREED

German Shepherd X

SEX

FS

AGE

13 yrs

WEIGHT

103 lbs

INTERPRETED BY

R. McKenzie Daniel,
DVM, DABVP
(Canine and Feline)

IMAGING PERFORMED BY

Jenna Walsh, CVT

HOSPITAL NAME

Santa Clara AH

REFERRING VET

Dr. Zulauf

INVOICE

16410

DATE

4/27/23

measuring 3.5 cm in diameter. Scant perihepatic free fluid was noted. The gallbladder was non-distended in size containing primarily anechoic content with mild subtly shadowing luminal debris. No evidence of gallbladder inflammatory criteria was noted. The cystic and common bile ducts were normal.

Gastrointestinal

The stomach presented intact wall layering with a primarily empty lumen with luminal gas. Non-specific ovoid-appearing shadowing echo was present in the gastric body measuring approximately 2.0-2.5 cm in diameter. This echo was not obstructive to pyloric outflow.

The small intestine presented intact wall layering with 1:3 muscularis/mucosa ratio. The lumen of the small intestine was empty with no signs of ileus, obstruction, or foreign material.

Normal visible colon wall layers were present with apparent formed feces in lumen.

Pancreas

The pancreas was normal in size and contour with isoechoic to heterogeneous parenchyma compared to adjacent omentum. No signs of active inflammation or neoplasia. Mild right limb pancreatic duct dilation was noted.

Free Abdomen

No omental masses or overt lymphadenopathy were noted.

ULTRASONOGRAPHIC FINDINGS

- Nonhomogeneous micronodular spleen with medial mildly expansive mass
- Hepatomegaly exhibiting marked nonhomogeneous / nodular parenchyma with small nonhomogeneous intraparenchymal mass
- Nondistended gallbladder with mild debris (non-mucocele)
- Heterogeneous pancreas with minor right limb pancreatic duct dilation
- Mild chronic renal changes
- Scant perihepatic free fluid
- Small nonspecific shadowing gastric luminal echo

INTERPRETATION OF THE FINDINGS & FURTHER RECOMMENDATIONS

Unfortunately, the hepatosplenic presentation meets sonographic criteria for multicentric neoplasia, i.e., multicentric sarcoma, round cell neoplasia, or other. Benign hepatosplenic etiologies such as hyperplasia, hematopoiesis, inflammatory disease, etc., are considered less likely.

Assuming normal clotting status, hepatosplenic FNA cytology could be considered with potential for oncology consultation. This case appears to be nonsurgical.



PATIENT

Emma Tone

SPECIES

Canine

BREED

German Shepherd X

SEX

FS

AGE

13 yrs

WEIGHT

103 lbs

INTERPRETED BY

R. McKenzie Daniel,
DVM, DABVP
(Canine and Feline)

IMAGING PERFORMED BY

Jenna Walsh, CVT

HOSPITAL NAME

Santa Clara AH

REFERRING VET

Dr. Zulauf

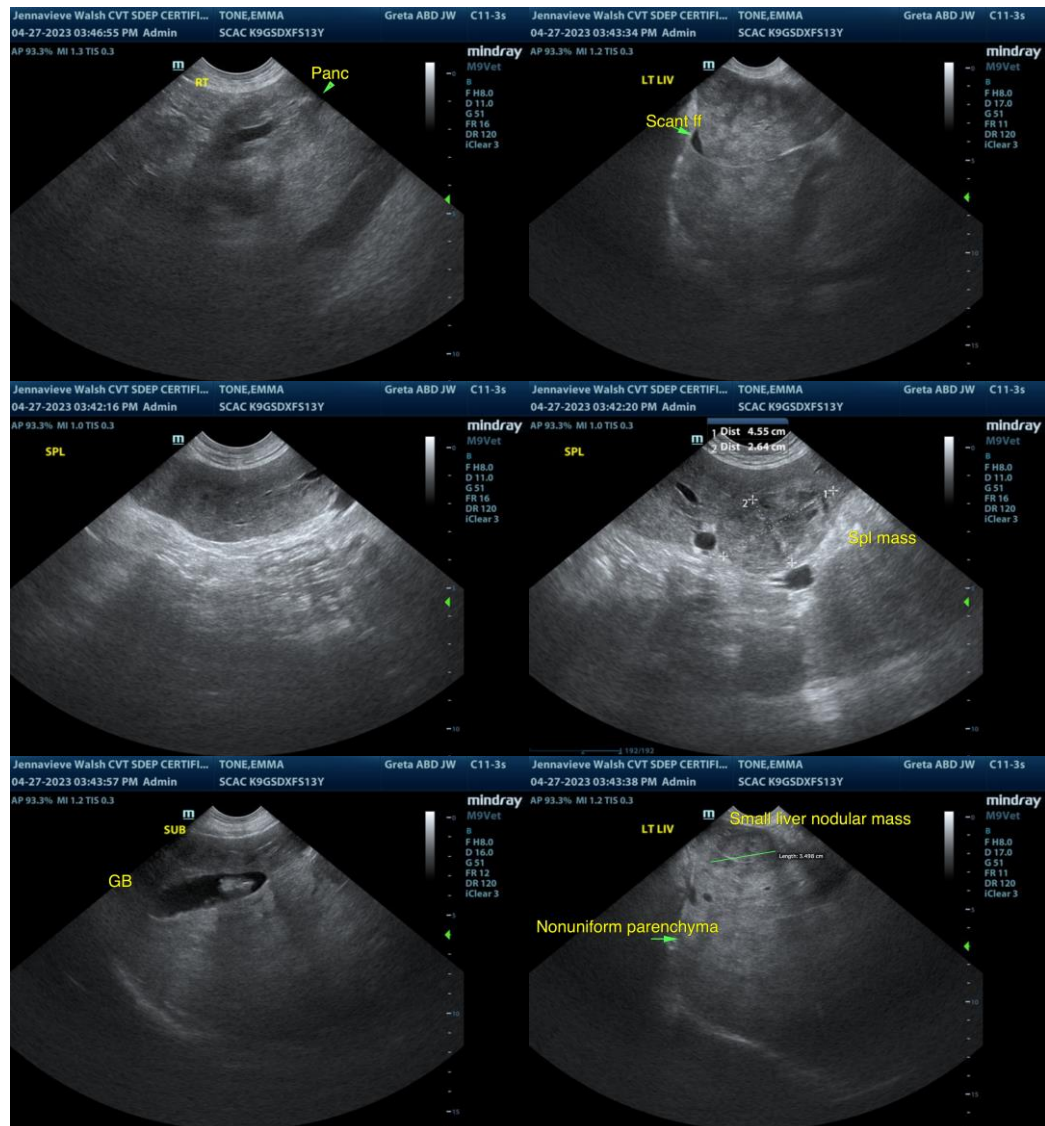
INVOICE

16410

DATE

4/27/23

Concern for a possible small nonobstructive gastric foreign body may be indicated, although dense ingesta, medication, etc., may present in a similar sonographic manner. Correlation with most recent meal ingestion is suggested with potential sonographic monitoring of the stomach for gastric emptying.





PATIENT

Emma Tone

SPECIES

Canine

BREED

German Shepherd X

SEX

FS

AGE

13 yrs

WEIGHT

103 lbs

INTERPRETED BY

R. McKenzie Daniel,
DVM, DABVP
(Canine and Feline)

IMAGING PERFORMED BY

Jenna Walsh, CVT

HOSPITAL NAME

Santa Clara AH

REFERRING VET

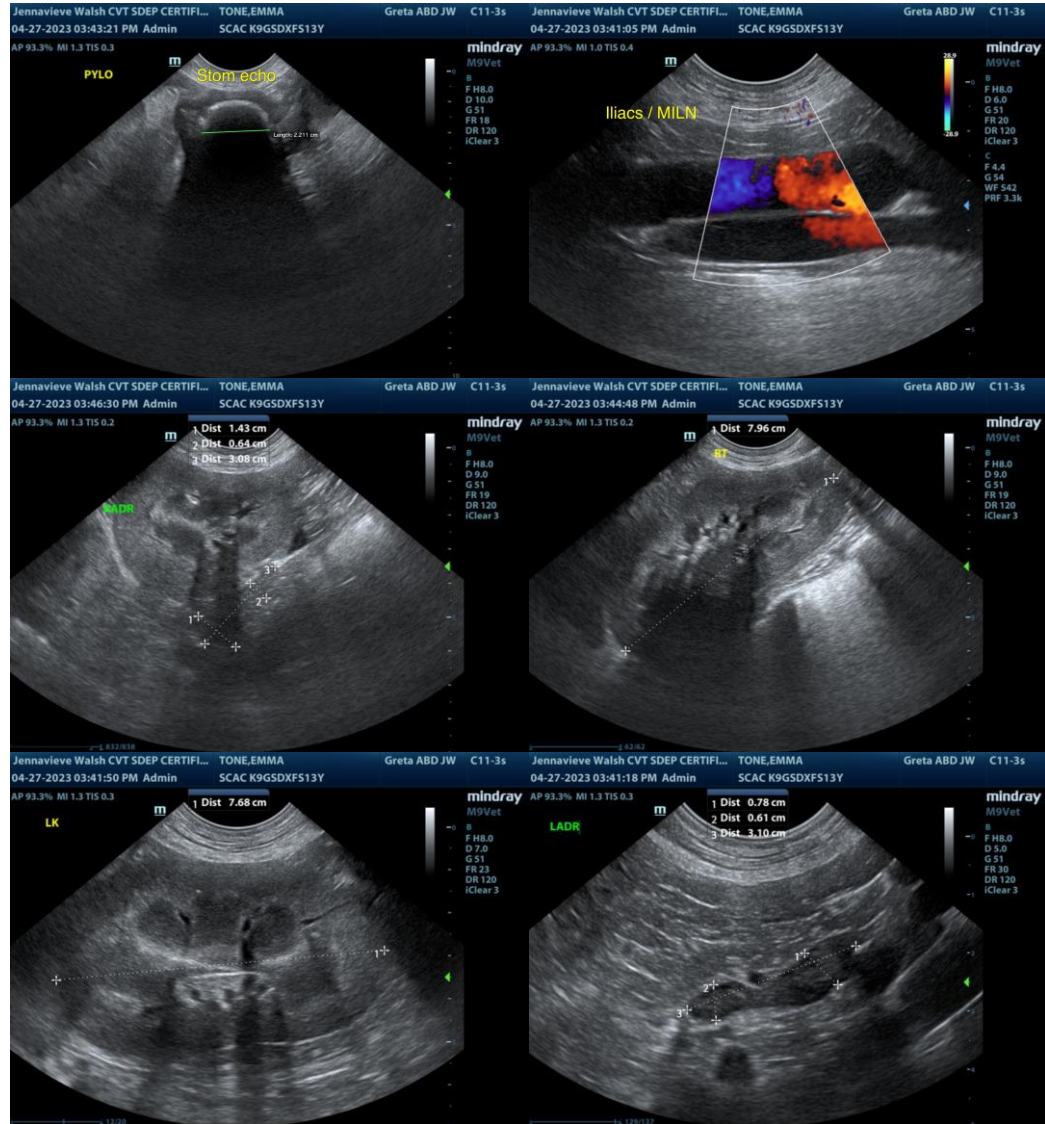
Dr. Zulauf

INVOICE

16410

DATE

4/27/23



The information and recommendations provided are based on the images presented by the referring veterinarian/sonographer. No evaluation can be communicated regarding pathology that was not visible in the image/video clips provided.

Thank you for this referral. If the clinical or image interpretation does not parallel your findings or if I can be of any further assistance please contact me.

R. McKenzie Daniel, DVM, DABVP (Canine / Feline Practice)
info@SonoPath.com