



PATIENT

Winnie Giunta

SPECIES

Feline

BREED

DSH

SEX

FS

AGE

12 years

WEIGHT

5.8 lbs.

INTERPRETED BY

R. McKenzie Daniel,
DVM, DABVP
(Canine and Feline)

**IMAGING
PERFORMED BY**

Kelly Vazquez

HOSPITAL NAME

Animal General on
Hudson

REFERRING VET

Dr. Stefanie Lang

INVOICE

13741

DATE

4/27/22

PRESENTING CLINICAL SIGNS

History of stranguria and weight loss, decreased appetite for a few days. Current meds: methimazole, gabapentin, mirtazapine, and may start Convenia if sterile urine sample acquired.

Abnormal PE/Chem/CBC/UA Results: ALT - 140, T4- 11.9, HCT 31%.

ULTRASONOGRAPHIC EXAMINATION OF THE ABDOMEN

Urinary System

The urinary bladder was normal in size and tone. The urinary bladder walls were sonographically unremarkable without obvious inflammatory or neoplastic criteria. Anechoic urine with moderate to marked, nondependent to congealed echogenic to pinpoint hyperechoic sediment and mucus was present with no evidence of macro calculi. The urinary bladder sediment appeared to be mobile. The urethra was normal in structure and tone to a depth of 2.0 cm.

The area of the aortic trifurcation was free of pathology.

Normal size and margination were present in the kidneys. A normal 1:3 cortex / medulla ratio was maintained. The medulla and cortices were uniform in texture with some increased echogenicity and mild loss of corticomedullary symmetry and definition expected for the age of the patient. No evidence of pelvic dilation was present. The left kidney measured 3.3 cm in length. The right kidney measured 3.0 cm in length.

Adrenal Glands

No overt pathology was noted in the area of the left or right adrenal glands.

Spleen

The spleen exhibited a finely textured and homogenous parenchyma which was hyperechoic to the liver and renal cortical parenchyma. The capsule was smooth and regular without apparent expansion. The splenic vasculature at the hilus was normal in volume with no evidence of congestion or thrombosis. Acute to chronic inflammatory, neoplastic, or benign parenchyma changes were not noted. The spleen measured 0.54 cm width.

Liver/ Gallbladder

The liver was subjectively normal in size, structure, and contour. The liver parenchyma was mildly nonuniform and hypoechoic to the spleen with a moderate coarse echotexture and subjective mild to benign parenchymal remodeling. The hepatic and portal vasculature were normal in appearance without signs of congestion. The gallbladder was non-distended in size containing anechoic content with very minor particulate luminal debris. The proximal common bile duct was mildly dilated to tortuous without overt post hepatic obstruction. The mildly dilated to tortuous common bile duct did not appear to extend to the level of the duodenal papilla. The common bile duct measured 0.17 cm diameter.

Gastrointestinal

The stomach presented intact wall layering with a normal wall layer ratio. Minor retained nonshadowing ingesta / chyme was present in the antrum and pylorus.



PATIENT	The small intestine presented intact wall layering with segmental to generalized propensity for mildly prominent muscularis layer. No evidence of loss of Intestinal wall layering or masses was noted. The duodenum wall width measured 0.33 cm. The jejunum wall width measured 0.29 cm. The ileocolic wall width measured 0.32 cm.
Winnie Giunta	
SPECIES	
Feline	Normal visible colon wall layers were present with apparent formed feces in lumen.
BREED	<i>Pancreas</i>
DSH	The pancreas was Indistinctly visualized with overall normal pancreatic size and contour and subjective mild nonhomogeneous to hypoechoic left pancreatic parenchyma.
SEX	<i>Free Abdomen</i>
FS	No omental masses, lymphadenopathy or effusion were present.
AGE	ULTRASONOGRAPHIC FINDINGS
12 years	<ul style="list-style-type: none"> • Moderate to marked urinary bladder sediment / mucus • Mild chronic renal changes - no evidence of pyelonephritis • Mild hepatopathy with nonobstructive proximal common bile duct dilation - suspect mild cholangitis / cholangiohepatitis • Possible low-grade chronic to chronic active pancreatitis • Intact yet segmental to generalized prominent small bowel wall layering
WEIGHT	
5.8 lbs.	
INTERPRETED BY	INTERPRETATION OF THE FINDINGS & FURTHER RECOMMENDATIONS
R. McKenzie Daniel, DVM, DABVP (Canine and Feline)	Cystocentesis for urine collection with full urinalysis, as well as urine culture and sensitivity if evidence of inflammatory cells, is suggested. No overt evidence of lower urinary tract neoplastic criteria was noted.
IMAGING PERFORMED BY	
Kelly Vazquez	The small intestine exhibited mild mural changes which although not definitive may suggest inflammatory enteropathy / IBD. Potential for Triad Disease may be considered in this patient, given potential for low-grade pancreatitis and suspect low-grade Inflammatory hepatobiliary disease. Further assessment may include a GI panel to include PLI/TLI/Cobalamin/Folate +/- hepatic FNA, assuming normal clotting status, to assess for evidence of inflammatory cells.
HOSPITAL NAME	
Animal General on Hudson	
REFERRING VET	
Dr. Stefanie Lang	The weight loss and mild elevated ALT may also be attributable to hyperthyroidism.
INVOICE	
13741	
DATE	
4/27/22	



PATIENT

Winnie Giunta

SPECIES

Feline

BREED

DSH

SEX

FS

AGE

12 years

WEIGHT

5.8 lbs.

INTERPRETED BY

R. McKenzie Daniel,
DVM, DABVP
(Canine and Feline)

IMAGING PERFORMED BY

Kelly Vazquez

HOSPITAL NAME

Animal General on
Hudson

REFERRING VET

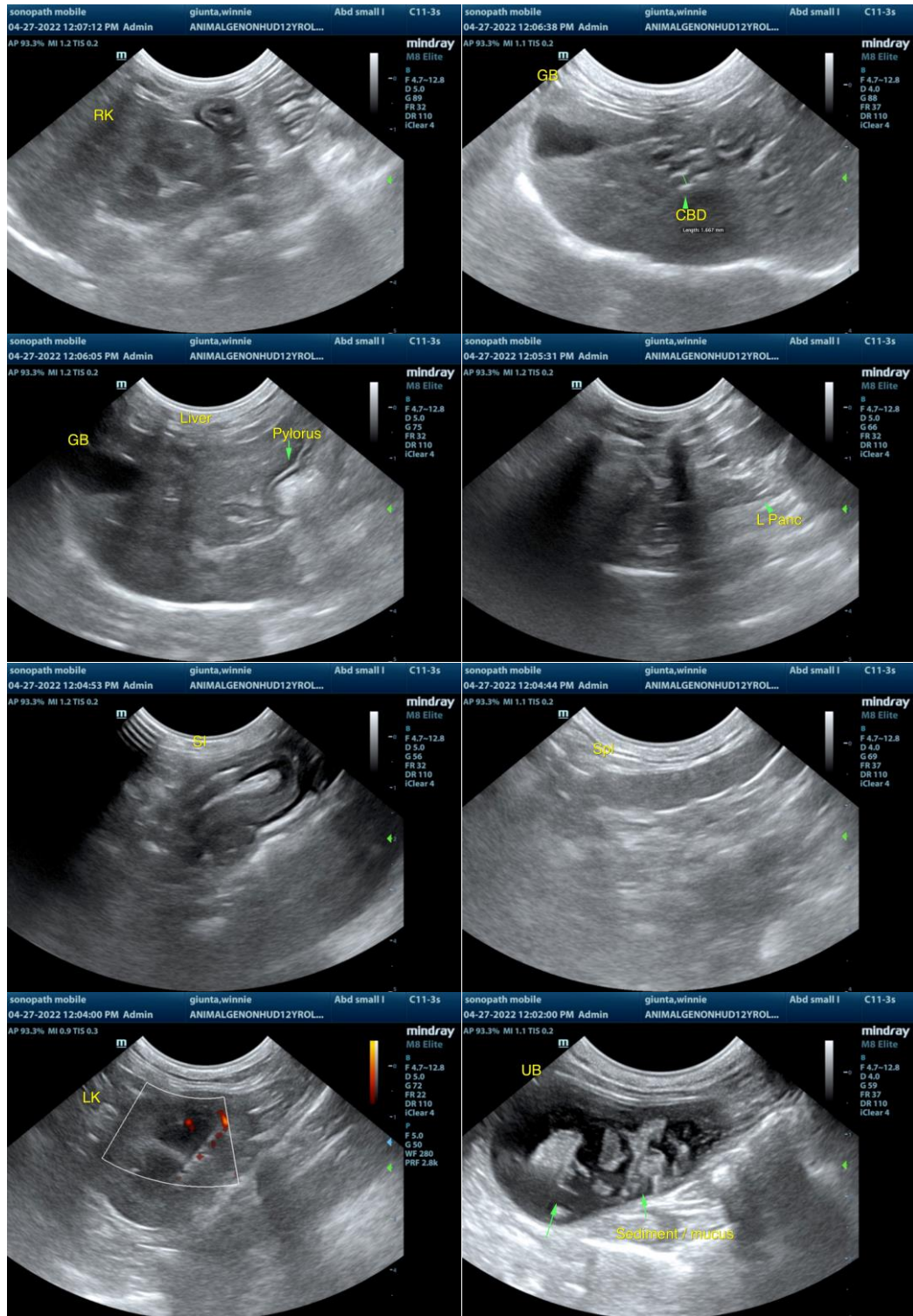
Dr. Stefanie Lang

INVOICE

13741

DATE

4/27/22





PATIENT

Winnie Giunta

SPECIES

Feline

BREED

DSH

SEX

FS

AGE

12 years

WEIGHT

5.8 lbs.

INTERPRETED BY

R. McKenzie Daniel,
DVM, DABVP
(Canine and Feline)

IMAGING PERFORMED BY

Kelly Vazquez

HOSPITAL NAME

Animal General on
Hudson

REFERRING VET

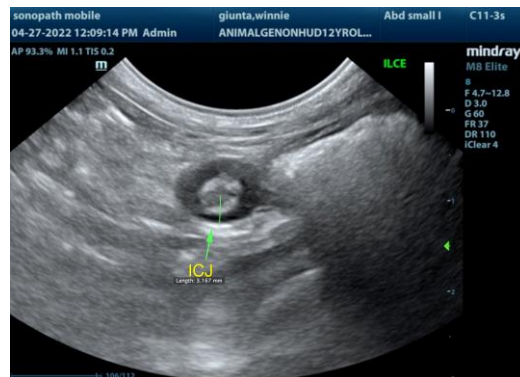
Dr. Stefanie Lang

INVOICE

13741

DATE

4/27/22



The information and recommendations provided are based on the images presented by the referring veterinarian/sonographer. No evaluation can be communicated regarding pathology that was not visible in the image/video clips provided.

Thank you for this referral. If the clinical or image interpretation does not parallel your findings or if I can be of any further assistance please contact me.

R. McKenzie Daniel, DVM, DABVP (Canine / Feline Practice)
info@SonoPath.com