SonoPath
Clinical Sonography & Telecytology
EDUCATIONAL TELECONSULTATION SERVICES™
1-800-838-4268 info@sonopath.com SonoPath.com

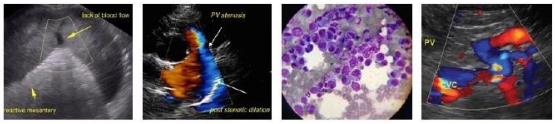

THE FOCAL ZONE
IMAGING PERFORMED BY
289-808-2608 info@thefocalzone.com

PATIENT
Sammy Devries

SPECIES
Canine

BREED
Shep X

SEX
MN

AGE
10 years

WEIGHT
35 kg

INTERPRETED BY
R. McKenzie Daniel, DVM, DABVP

IMAGING PERFORMED BY
Crystal Hill

HOSPITAL NAME
Hartzel AH

REFERRING VET
Dr. Hobbs

INVOICE
13727

DATE
4/26/22

PRESENTING CLINICAL SIGNS

Melena, frank blood in stool for about 2 weeks. Diarrhea.
Abnormal PE/Chem/CBC/UA Results: Platelets were decreased at 127(clumping) but were better on today's bloodwork. 4DX negative and Ova and parasite test was negative. Elevated Eosiniphils.

ULTRASONOGRAPHIC EXAMINATION OF THE ABDOMEN

Urinary System

The urinary bladder, trigone, and cystourethral junction exhibited normal thickness and tone. Anechoic urine was primarily present in the lumen with minor sediment or potential mucus was present. The ureteral papillae were normal. The ureters were not visible which is normal. No evidence of inflammatory or neoplastic changes was noted.

No overt pathology was noted In the area of the residual prostate.

The area of the aortic trifurcation was free of pathology.

Normal size and margination were present in the kidneys. A normal 1:3 cortex / medulla ratio and normal corticomedullary definition were maintained. The echogenicity of the cortex was similar to or slightly less than normal liver parenchyma while the medulla echogenicity was hypoechoic to the cortex with no evidence of pelvic dilation. The left kidney measured 6.2 cm in length. The right kidney measured 7.1 cm in length.

Adrenal Glands

The left adrenal gland was uniform in size and contour with a uniformly hypoechoic parenchyma. The left adrenal gland measured 2.2 cm length x 0.77 cm width at the caudal pole. The right adrenal gland was uniform in size and contour with a uniformly hypoechoic parenchyma. The right adrenal gland measured 2.8 cm length x 0.79 cm width at the caudal pole.

Spleen

The spleen exhibited a finely textured and homogenous parenchyma which was hyperechoic to the liver and renal cortical parenchyma. The capsule was smooth and regular without apparent expansion. The splenic vasculature at the hilus was normal in volume with no evidence of congestion or thrombosis. Acute to chronic inflammatory, neoplastic, or benign parenchyma changes were not noted.

Liver/ Gallbladder

The liver was subjectively normal in size, structure, and contour. The liver parenchyma was uniform and hypoechoic to the spleen with a mild coarse echotexture. The hepatic and portal vasculature were normal in appearance without signs of congestion. The gallbladder was non-distended in size with thin walls and primarily anechoic luminal content. The cystic and common bile ducts were normal.

Gastrointestinal

The stomach presented intact wall layering with a normal wall layer ratio. The lumen of the stomach was empty with no signs of ileus, obstruction, or foreign material. The stomach wall width measured 0.46 cm.

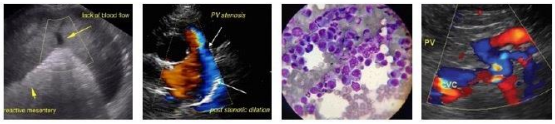

PATIENT

Sammy Devries

SPECIES

Canine

BREED

Shep X

SEX

MN

AGE

10 years

WEIGHT

35 kg

INTERPRETED BY

R. McKenzie Daniel, DVM, DABVP

IMAGING PERFORMED BY

Crystal Hill

HOSPITAL NAME

Hartzel AH

REFERRING VET

Dr. Hobbs

INVOICE

13727

DATE

4/26/22

The small intestine presented intact wall layering with 1:3 muscularis/mucosa ratio. The small intestine exhibited minor segmental nonobstructive ileus. The small intestinal wall width measured 0.35 cm.

Normal visible colon wall layers were present with apparent formed feces in lumen.

Pancreas

The parenchyma of the left limb, body, and right limb of the pancreas presented isoechoic to the adjacent omental fat. A normal curvilinear capsule contour of the pancreas was present. The visible pancreatic duct was normal. No signs of active inflammation or neoplastic disease were evident.

Free Abdomen

No omental masses, lymphadenopathy or peritoneal effusion were present.

ULTRASONOGRAPHIC FINDINGS

- Sonographically unremarkable gastrointestinal tract with minor, nonobstructive, small intestinal ileus

INTERPRETATION OF THE FINDINGS & FURTHER RECOMMENDATIONS

Overall, sonographically unremarkable abdomen without evidence of gastrointestinal mural pathology or mechanical obstructive pattern.

In patients with chronic gastrointestinal signs, low-grade to mild pancreatitis, dietary indiscretion / food intolerance, dysbiosis, structurally Insignificant inflammatory bowel disease, occult Addison's Disease, or less likely occult infiltrative neoplasia may be possible. Further assessment may include a GI panel to include PLI/TLI/Cobalamin/Folate, as well as resting cortisol level to assess for or rule out occult Addison's Disease given the reported melena, which may indicate intestinal microulceration, as well as eosinophilia.

Empirically, a limited antigen or hydrolyzed diet trial with potential long term dietary therapy, prophylactic deworming (Panacur 50 mg/kg SID x 5 consecutive days with repeat protocol in 3 weeks even if fecal testing is negative), high colony count probiotic (Proviable or Visbiome), an antibiotic trial which may Include Metronidazole or Tylosin, with as-needed gastroprotectant and assessment of clinical response would be reasonable. Sonographic reassessment of the gastrointestinal tract could be considered if persistent gastrointestinal signs are noted despite conservative therapy.

SonoPath
Clinical Sonography & Telecytology
EDUCATIONAL TELECONSULTATION SERVICES™
1-800-838-4268 info@sonopath.com SonoPath.com

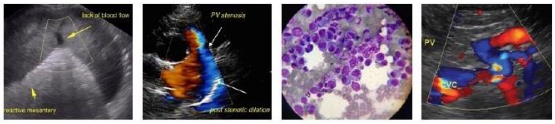

THE FOCAL ZONE
IMAGING PERFORMED BY
289-808-2608 info@thefocalzone.com

PATIENT

Sammy Devries

SPECIES

Canine

BREED

Shep X

SEX

MN

AGE

10 years

WEIGHT

35 kg

INTERPRETED BY

R. McKenzie Daniel, DVM, DABVP

IMAGING PERFORMED BY

Crystal Hill

HOSPITAL NAME

Hartzel AH

REFERRING VET

Dr. Hobbs

INVOICE

13727

DATE

4/26/22

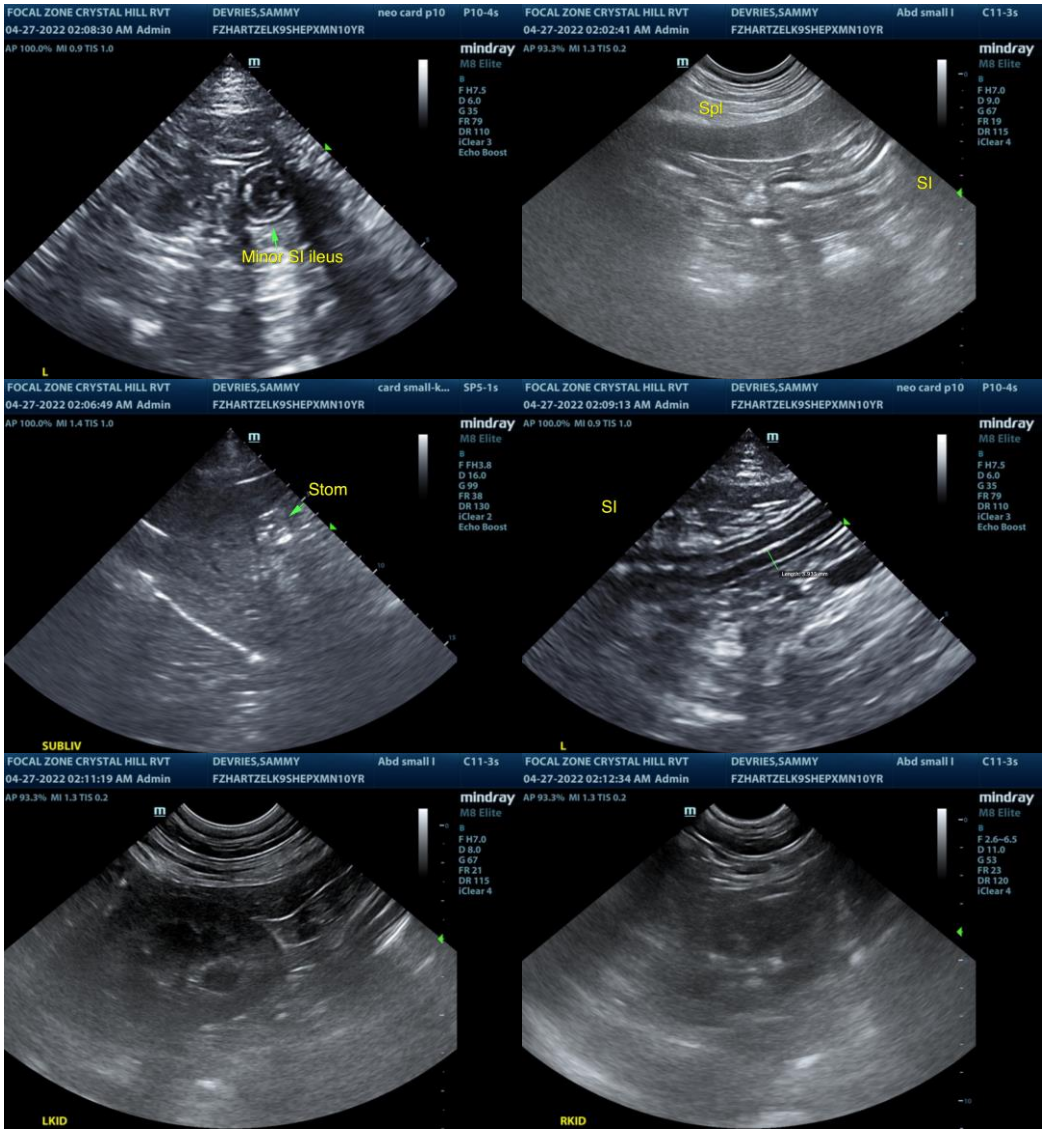

SonoPath
Clinical Sonography & Telecytology
EDUCATIONAL TELECONSULTATION SERVICES™
1-800-838-4268 info@sonopath.com SonoPath.com

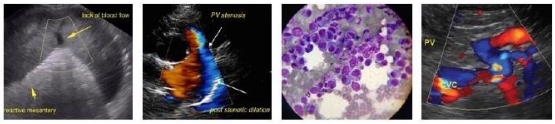

THE FOCAL ZONE
IMAGING PERFORMED BY
289-808-2608 info@thefocalzone.com

PATIENT

Sammy Devries

SPECIES

Canine

BREED

Shep X

SEX

MN

AGE

10 years

WEIGHT

35 kg

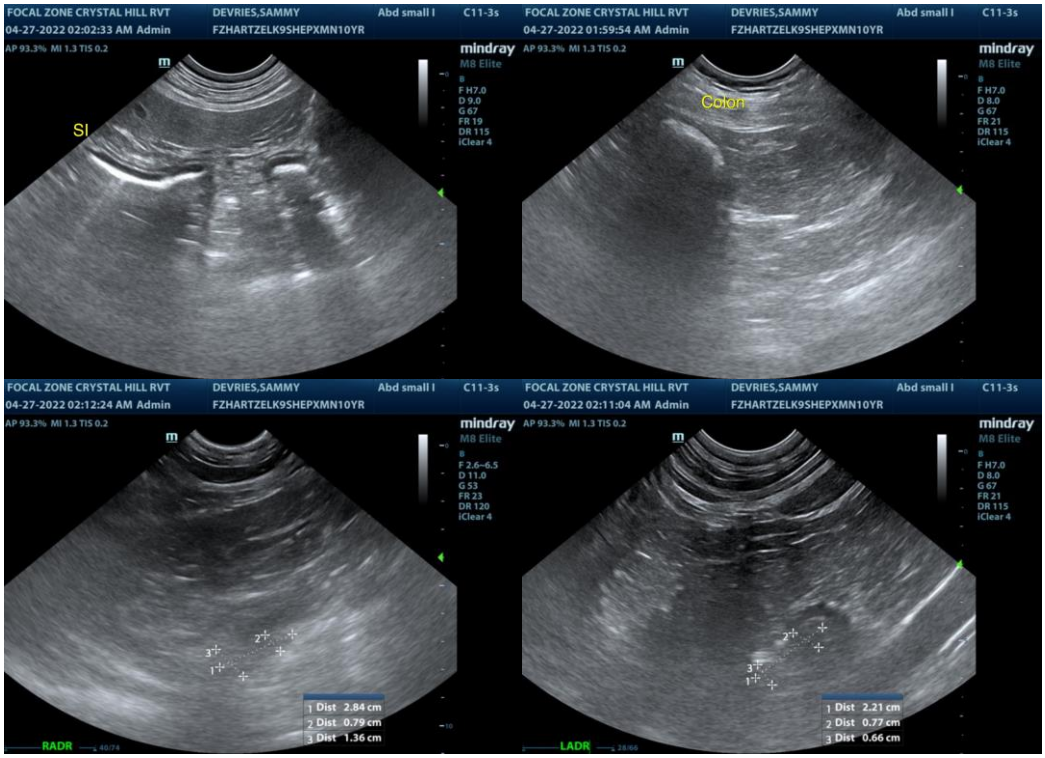

INTERPRETED BY

R. McKenzie Daniel, DVM, DABVP

IMAGING PERFORMED BY

Crystal Hill

HOSPITAL NAME

Hartzel AH

REFERRING VET

Dr. Hobbs

INVOICE

13727

DATE

4/26/22

The information and recommendations provided are based on the images presented by the referring veterinarian/sonographer. No evaluation can be communicated regarding pathology that was not visible in the image/video clips provided.

Thank you for this referral. If the clinical or image interpretation does not parallel your findings or if I can be of any further assistance please contact me.

R. McKenzie Daniel, DVM, DABVP (Canine / Feline Practice)
info@SonoPath.com