



PATIENT

Mouse Mulreay

SPECIES

Feline

BREED

DSH

SEX

FS

AGE

5 years

WEIGHT

5.74 kg

INTERPRETED BY

R. McKenzie Daniel,
DVM, DABVP
(Canine and Feline)

IMAGING PERFORMED BY

Dr. Belan

HOSPITAL NAME

McKnight 24 Hr. AH

REFERRING VET

Dr. Gruffydd

INVOICE

13729

DATE

4/26/22

PRESENTING CLINICAL SIGNS

Vaccinated 7 days ago has had fever of unknown origin since. Decreased appetite and lethargic
Abnormal PE/Chem/CBC/UA Results: CBC chem and UA normal

ULTRASONOGRAPHIC EXAMINATION OF THE ABDOMEN

Urinary System

The urinary bladder, trigone, cystourethral junction, and visible pelvic urethra to a depth of 2.0 cm exhibited normal thickness and tone. Anechoic urine was present in the lumen with no uroliths or sediment. The ureteral papillae were normal. The ureters were not visible which is normal. No evidence of inflammatory or neoplastic changes was noted.

A visualized, solitary medial iliac lymph node exhibited normal size, position, and shape with isoechoic echogenicity compared to the adjacent omentum and without evidence of inflammatory or neoplastic criteria. The medial iliac lymph node measured 0.65 cm x 0.25 cm.

Normal size and margination were present in the kidneys. A normal 1:3 cortex / medulla ratio and normal corticomedullary definition were maintained. The echogenicity of the cortex was similar to or slightly less than normal liver parenchyma while the medulla echogenicity was hypoechoic to the cortex with no evidence of pelvic dilation. The left kidney measured 3.9 cm in length. The right kidney measured 4.1 cm in length.

Adrenal Glands

The left adrenal gland was uniform in size and contour with a uniformly hypoechoic parenchyma. The left adrenal gland measured 0.37 cm width. The right adrenal gland was uniform in size and contour with a uniformly hypoechoic parenchyma. The right adrenal gland measured 0.31 cm width.

Spleen

The spleen exhibited a finely textured and homogenous parenchyma which was hyperechoic to the liver and renal cortical parenchyma. The capsule was smooth and regular without apparent expansion. The splenic vasculature at the hilus was normal in volume with no evidence of congestion or thrombosis. Acute to chronic inflammatory, neoplastic, or benign parenchyma changes were not noted. The spleen measured 1.0 cm width at the level of the hilus.

Liver/ Gallbladder

The liver was subjectively normal in size, structure, and contour. The liver parenchyma was uniform and hypoechoic to the spleen with a mild coarse echotexture. The hepatic and portal vasculature were normal in appearance without signs of congestion. The gallbladder was non-distended in size with thin walls and primarily anechoic luminal content. The cystic and common bile ducts were normal.

Gastrointestinal

The stomach presented intact wall layering with a normal wall layer ratio. The lumen of the stomach was empty with no signs of ileus, obstruction, or foreign material.

The small intestine presented intact wall layering with 1:3 muscularis/mucosa ratio. The lumen of the small intestine was empty with no signs of ileus, obstruction, or foreign material. The jejunum wall width



PATIENT

Mouse Mulreay

measured 0.20 cm. The ileocolic wall width measured 0.26 cm. The duodenum wall width measured 0.25 cm.

SPECIES

Feline

Normal visible colon wall layers were present with apparent formed feces in lumen.

BREED

DSH

Pancreas

The parenchyma of the left limb, body, and right limb of the pancreas presented isoechoic to the adjacent omental fat. A normal curvilinear capsule contour of the pancreas was present. The visible pancreatic duct was normal. No signs of active inflammation or neoplastic disease were evident.

SEX

FS

Free Abdomen

No omental masses, lymphadenopathy or peritoneal effusion were present.

AGE

5 years

ULTRASONOGRAPHIC FINDINGS

- Sonographically unremarkable abdomen

WEIGHT

5.74 kg

INTERPRETATION OF THE FINDINGS & FURTHER RECOMMENDATIONS

No evidence of abdominal visceral pathology as an obvious cause of the patient's fever of unknown origin and clinical signs.

INTERPRETED BY

R. McKenzie Daniel, DVM, DABVP (Canine and Feline)

Continued gastrointestinal supportive care is suggested. Recheck retroviral status may be considered if clinically applicable. Three view chest radiographs are suggested to rule out occult thoracic or esophageal pathology.

IMAGING PERFORMED BY

Dr. Belan

HOSPITAL NAME

McKnight 24 Hr. AH

REFERRING VET

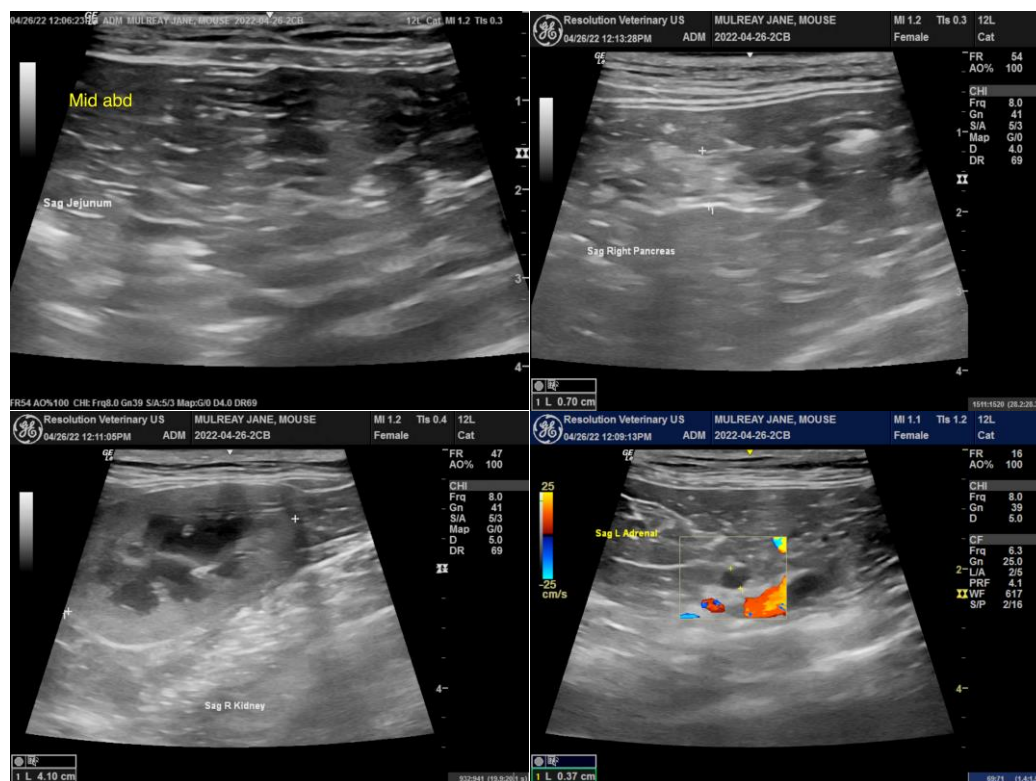
Dr. Gruffydd

INVOICE

13729

DATE

4/26/22





PATIENT

Mouse Mulreay

SPECIES

Feline

BREED

DSH

SEX

FS

AGE

5 years

WEIGHT

5.74 kg

INTERPRETED BY

R. McKenzie Daniel,
DVM, DABVP
(Canine and Feline)

IMAGING PERFORMED BY

Dr. Belan

HOSPITAL NAME

McKnight 24 Hr. AH

REFERRING VET

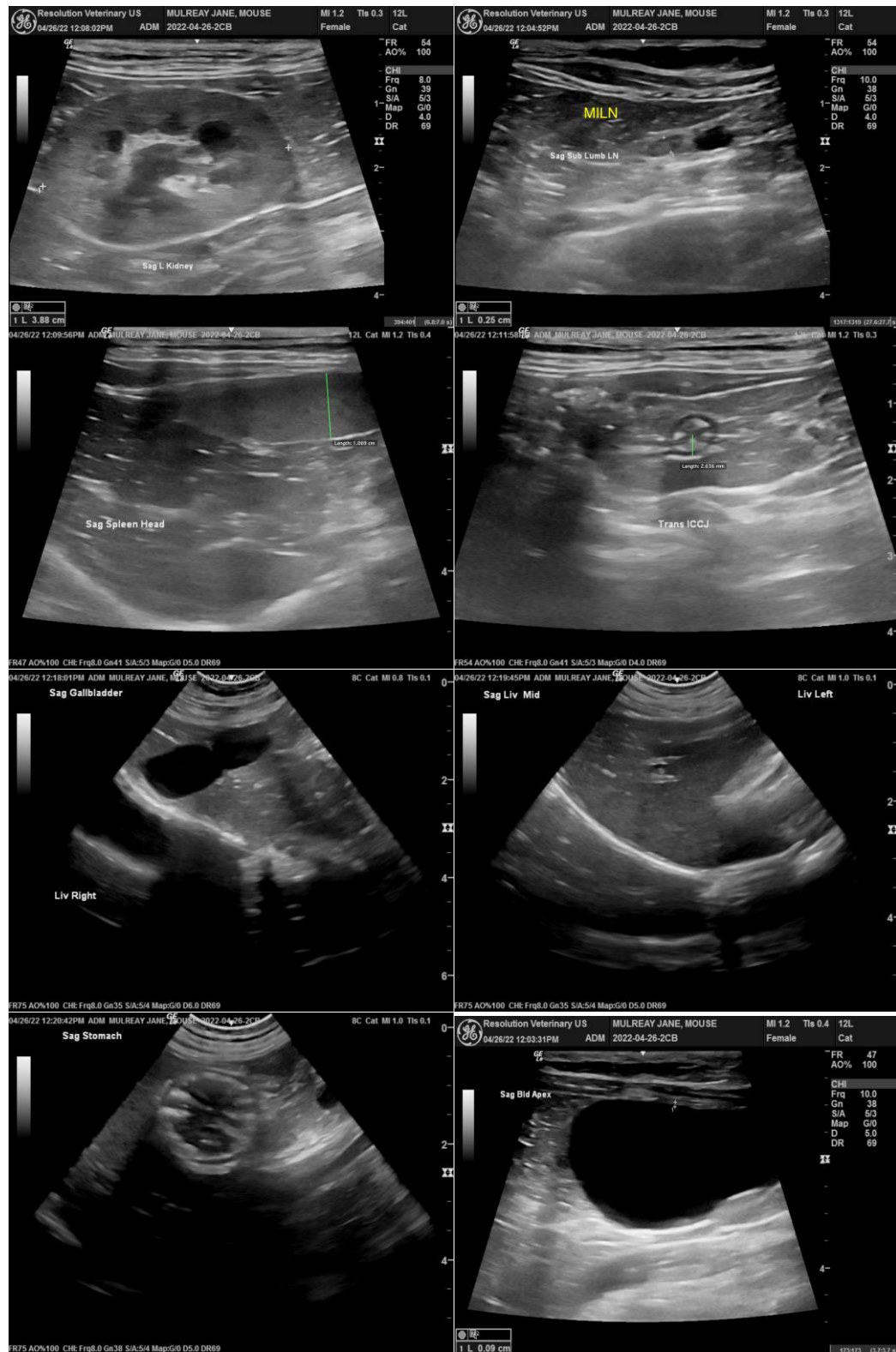
Dr. Gruffydd

INVOICE

13729

DATE

4/26/22





PATIENT

Mouse Mulreay

SPECIES

Feline

BREED

DSH

SEX

FS

AGE

5 years

WEIGHT

5.74 kg

INTERPRETED BY

R. McKenzie Daniel,
DVM, DABVP
(Canine and Feline)

**IMAGING
PERFORMED BY**

Dr. Belan

HOSPITAL NAME

McKnight 24 Hr. AH

REFERRING VET

Dr. Gruffydd

INVOICE

13729

DATE

4/26/22

The information and recommendations provided are based on the images presented by the referring veterinarian/sonographer. No evaluation can be communicated regarding pathology that was not visible in the image/video clips provided.

Thank you for this referral. If the clinical or image interpretation does not parallel your findings or if I can be of any further assistance please contact me.

R. McKenzie Daniel, DVM, DABVP (Canine / Feline Practice)
info@SonoPath.com