



PATIENT

Molly Tesla Murphy

SPECIES

Canine

BREED

CKCS

SEX

FS

AGE

8 years

WEIGHT

25.8 lbs

INTERPRETED BY

R. McKenzie Daniel,
DVM, DABVP
(Canine and Feline)

IMAGING PERFORMED BY

Dr. Sorbo

HOSPITAL NAME

Cambridge VC

REFERRING VET

Dr. Sorbo

INVOICE

16680

DATE

4/25/23

PRESENTING CLINICAL SIGNS

New low-grade murmur. No other concerns.

Abnormal PE/Chem/CBC/UA Results: I/VI systolic, left basilar, murmur.

ULTRASONOGRAPHIC EXAMINATION OF THE HEART

CANINE	MR	TR	LA/AO	LA/AO	FS	EF	EPSS
CARDIAC PARAMETERS	VMAX (m/s)	VMAX (m/s)	(Boon method)	(Heart Base; Swe)	(%)	(%)	(cm)
NORMAL PARAMETER	4.5-5.5	<2.7	1.3	<1.3	28-40	40-100	<0.6
PATIENT	5.3			1.4	48	80	0.2
CANINE	HR	AV	PV	BODY WEIGHT	LA	LVIDd	LVIDs
CARDIAC PARAMETERS	(BPM)	VMAX (m/s)	MAX (m/s)	(kg)	2D short axis Base view (cm)	Avg; 2D and m-mode short axis (cm)	Avg; 2D and m-mode short axis (cm)
NORMAL PARAMETER	50-100	0.7-1.7	0.7-1.6				
PATIENT	NM	1.3	1.0		3.0	2.6	

Cardiac Presentation

The echocardiogram in this patient demonstrated normal **left atrial** size based on 3 different LA measurement methods. Chamber volumes and echogenicity were normal. The cranial and caudal **mitral** valve leaflets presented mild thickening consistent with mild endocardiosis. No evidence of valvular prolapse was noted. Doppler indicated measurable mild to moderate eccentric insufficiency. The **left ventricle** presented thicknesses with linear contour and was not dilated nor restricted. The **myocardium** presented normal echogenicity without subjective evidence of significant fibrotic or ischemic disease. **Contractility** of the ventricular walls was adequate and in normal range for this patient evidenced by the fractional shortening measurement and subjective evaluation of the different regions of the myocardium. The **left ventricular outflow** tract demonstrated normal laminar flow and subjective structural integrity. The **right atrium** and auricle revealed normal size, structure and content. No evidence of masses was noted or chamber overload. **Tricuspid** valvular assessment demonstrated adequate linear morphology. The **right ventricle** was of normal size (1/3 diameter of LV), chordae structure, myocardial echogenicity and thickness. **Pulmonic** tract assessment revealed normal valve structure, laminar flow, and diameter (approx. 1:1 pa/ao ratio). No visible **pericardial** or free pleura fluid was noted. No echographically detectable evidence of infiltrative disease was visible. The cranial **mediastinum and pericardial regions** were free of masses in the visible window.

ULTRASONOGRAPHIC FINDINGS

- Chronic mitral valve disease (ACVIM B1)



PATIENT

Molly Tesla Murphy

SPECIES

Canine

BREED

CKCS

SEX

FS

AGE

8 years

WEIGHT

25.8 lbs

INTERPRETED BY

R. McKenzie Daniel,
DVM, DABVP
(Canine and Feline)

IMAGING PERFORMED BY

Dr. Sorbo

HOSPITAL NAME

Cambridge VC

REFERRING VET

Dr. Sorbo

INVOICE

16680

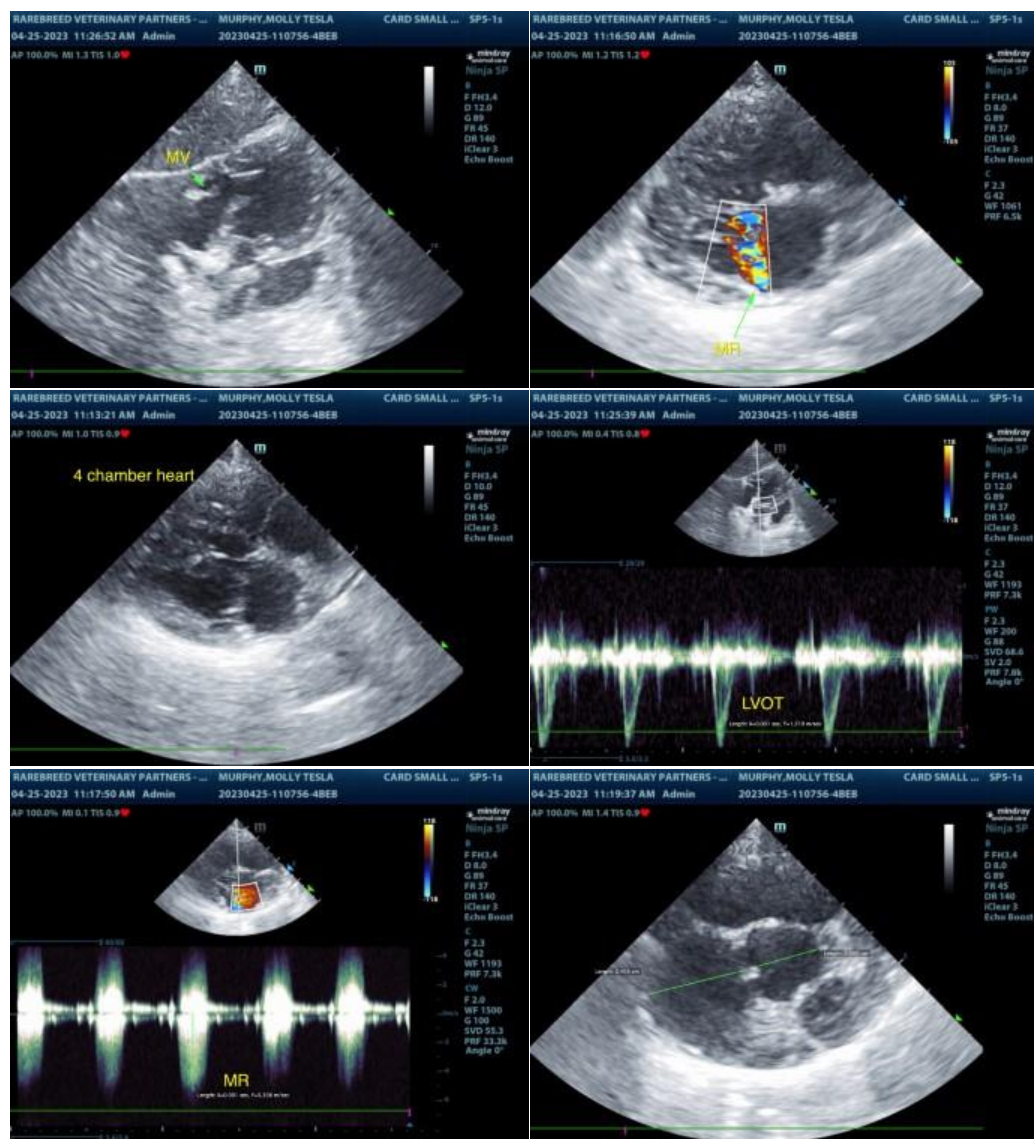
DATE

4/25/23

INTERPRETATION OF THE FINDINGS & FURTHER RECOMMENDATIONS

The lack of left atrium enlargement at this stage indicates that the current and future risk secondary to MR is low. However, given the breed, prognosis is highly variable and serial sonographic monitoring is recommended. No indication for cardiac medications. Recheck echocardiogram is suggested in 6-8 months, sooner if clinically indicated. No anesthetic contraindications if anesthesia is required.

Suggested anesthetic protocol may include opioid or Benzodiazepine pre-med, induction with Propofol or Alfaxalone, and appropriate gas anesthesia with avoidance of alpha 2 agonists.



The information and recommendations provided are based on the images presented by the referring veterinarian/sonographer. No evaluation can be communicated regarding pathology that was not visible in the image/video clips provided.



PATIENT

Molly Tesla Murphy

Thank you for this referral. If the clinical or image interpretation does not parallel your findings or if I can be of any further assistance please contact me.

SPECIES

Canine

R. McKenzie Daniel, DVM, DABVP (Canine / Feline Practice)
info@SonoPath.com

BREED

CKCS

SEX

FS

AGE

8 years

WEIGHT

25.8 lbs

INTERPRETED BY

R. McKenzie Daniel,
DVM, DABVP
(Canine and Feline)

**IMAGING
PERFORMED BY**

Dr. Sorbo

HOSPITAL NAME

Cambridge VC

REFERRING VET

Dr. Sorbo

INVOICE

16680

DATE

4/25/23