



PATIENT

Kylie Dietz

PRESENTING CLINICAL SIGNS

re check prev u/w on 4/21 showed 1.0 structure in pyloric antrum

SPECIES

Canine

RECHECK ULTRASONOGRAPHIC EXAMINATION OF THE ABDOMEN

Urinary System

The urinary bladder, trigone, cystourethral junction, and visible pelvic urethra exhibited normal thickness and tone. Anechoic urine was present in the lumen with no uroliths or sediment. The ureteral papillae were normal. The ureters were not visible which is normal. No evidence of inflammatory or neoplastic changes were noted.

BREED

Boxer

Normal size and margination were present in the kidneys. A normal 1:3 cortex / medulla ratio and normal corticomedullary definition were maintained. The echogenicity of the cortex was similar to or slightly less than normal liver parenchyma while the medulla echogenicity was hypoechoic to the cortex with no evidence of pelvic dilation. The left kidney measured 6.9 cm in length. The right kidney measured 5.7 cm in length, likely underestimation of right kidney size.

SEX

F

AGE

2

The area of the aortic trifurcation was free of pathology.

Adrenal Glands

The left adrenal gland was uniform in size and contour with a uniformly hypoechoic parenchyma. The left adrenal gland measured 0.57 cm width at the caudal pole. The right adrenal gland was uniform in size and contour with a uniformly hypoechoic parenchyma. The right adrenal gland measured 0.63 cm width at the caudal pole.

WEIGHT

66

Spleen

The spleen exhibited a finely textured and homogenous parenchyma which was hyperechoic to the liver and renal cortical parenchyma. The capsule was smooth and regular without apparent expansion. The splenic vasculature at the hilus was normal in volume with no evidence of congestion or thrombosis. Acute to chronic inflammatory, neoplastic, or benign parenchyma changes were not noted.

INTERPRETED BY

R. McKenzie Daniel,
DVM, DABVP
(Canine and Feline)

IMAGING PERFORMED BY

Jenn

Liver/Gallbladder

The liver was subjectively normal in size, structure, and contour. The liver parenchyma was uniform and hypoechoic to the spleen with a mild coarse echotexture. The hepatic and portal vasculature were normal in appearance without signs of congestion. The gallbladder was non-distended in size with thin walls and primarily anechoic luminal content. The cystic and common bile ducts were normal.

HOSPITAL NAME

Rockaway Animal
Hospital

Gastrointestinal

REFERRING VET

Dr. Maniar

The stomach was non-distended with minor non-shadowing ingesta/chyme. Overtly normal stomach wall was present.

The small intestine presented intact wall layering with 1:3 muscularis/mucosa ratio. The lumen of the small intestine contained mild segmental non-shadowing ingesta/chyme with no signs of ileus, obstruction or foreign material.

INVOICE

13597ag

Normal visible colon wall layers were present with apparent formed feces in lumen.

DATE

04/25/2023

Pancreas



PATIENT

Kylie Dietz

The parenchyma of the left limb, body and right limb of the pancreas presented isoechoic to the adjacent omental fat. A normal curvilinear capsule contour of the pancreas was present. The visible pancreatic duct was normal. No signs of active inflammation or neoplastic disease was evident.

SPECIES

Canine

Free Abdomen

No omental masses, overt lymphadenopathy or peritoneal effusion was present.

BREED

Boxer

ULTRASONOGRAPHIC FINDINGS

- Sonographically unremarkable GI tract with mild non-shadowing gastric and segmental intestinal ingesta/chyme.

SEX

F

INTERPRETATION OF THE FINDINGS & FURTHER RECOMMENDATIONS

The previously noted 1.0 cm structure within the pyloric antrum was not visualized. No evidence of GI obstructive pattern.

AGE

2

WEIGHT

66

INTERPRETED BY

R. McKenzie Daniel,
DVM, DABVP
(Canine and Feline)

IMAGING PERFORMED BY

Jenn

HOSPITAL NAME

Rockaway Animal
Hospital

REFERRING VET

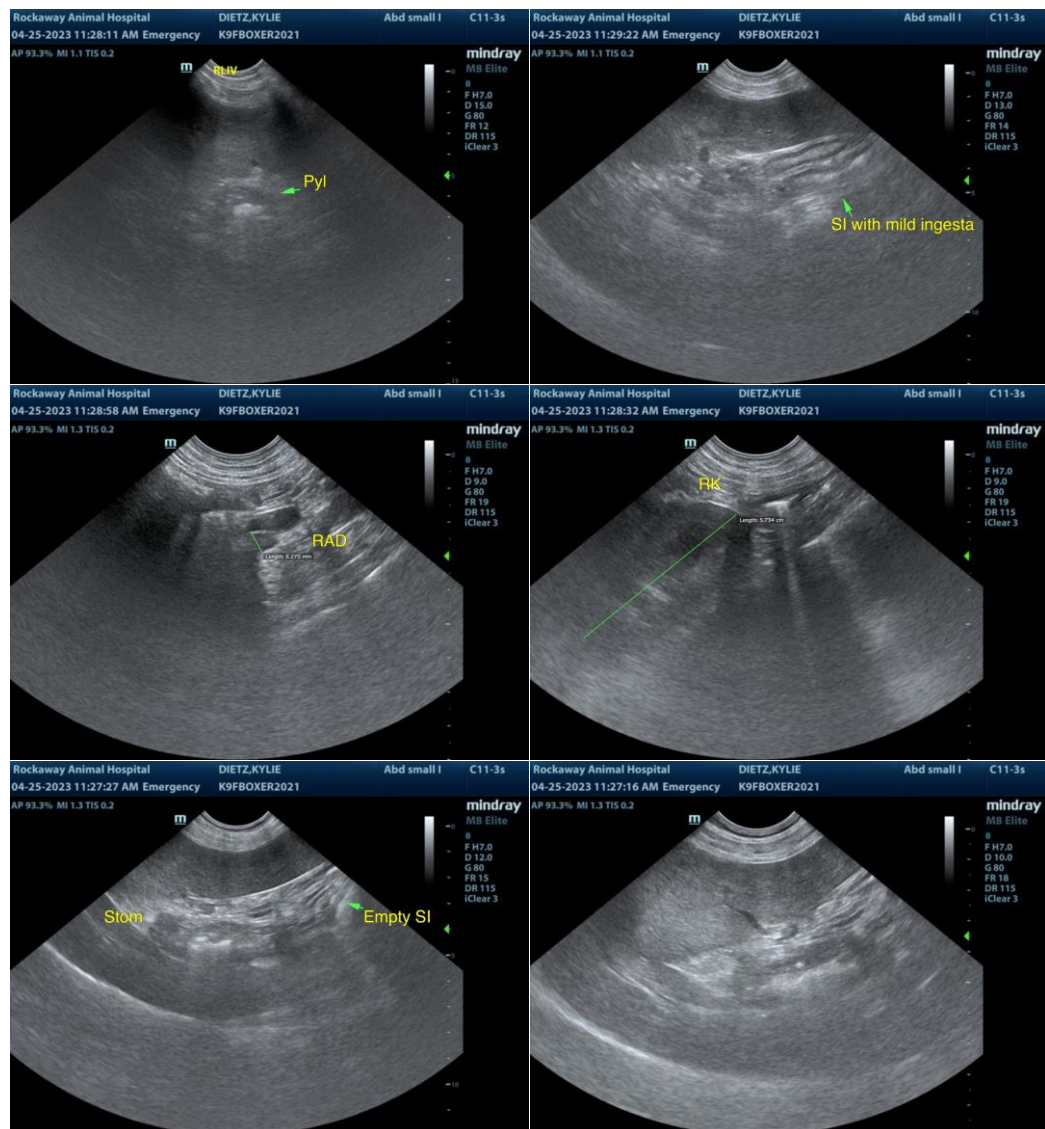
Dr. Maniar

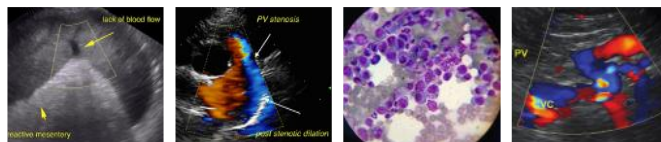
INVOICE

13597ag

DATE

04/25/2023





PATIENT

Kylie Dietz

SPECIES

Canine

BREED

Boxer

SEX

F

AGE

2

WEIGHT

66

INTERPRETED BY

R. McKenzie Daniel,
DVM, DABVP
(Canine and Feline)

IMAGING PERFORMED BY

Jenn

HOSPITAL NAME

Rockaway Animal
Hospital

REFERRING VET

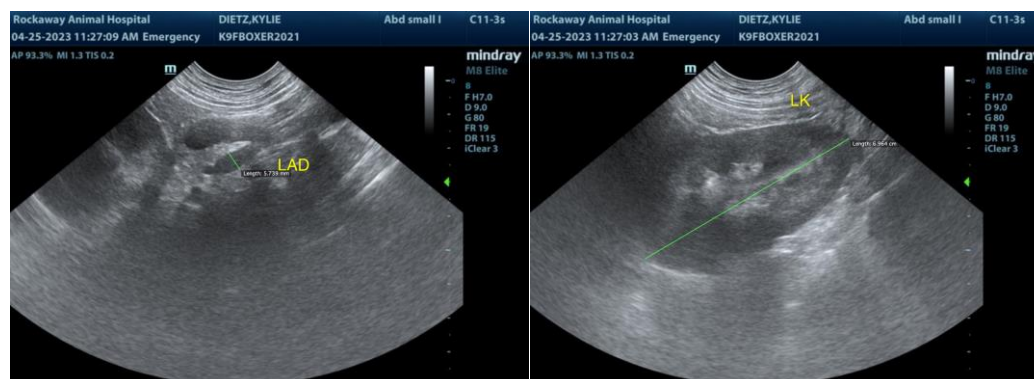
Dr. Maniar

INVOICE

13597ag

DATE

04/25/2023



The information and recommendations provided are based on the images presented by the referring veterinarian/sonographer. No evaluation can be communicated regarding pathology that was not visible in the image/video clips provided.

Thank you for this referral. If the clinical or image interpretation does not parallel your findings or if I can be of any further assistance, please contact me.

R. McKenzie Daniel, DVM, DABVP (Canine/Feline Practice)
mac.daniel@sonopath.com