



PATIENT

Sadie Cantu-Castillo

SPECIES

Canine

BREED

German Shepherd

SEX

Spayed Female

AGE

12 Years 2 Months

WEIGHT

58.5

INTERPRETED BY

R. McKenzie Daniel,
DVM, DABVP (Canine
/ Feline Practice)

IMAGING PERFORMED BY

Dr. Mych

HOSPITAL NAME

Craig Road Animal
Hospital

REFERRING VET

Cameron Johnson
DVM

INVOICE

15355

DATE

04/24/26

PRESENTING CLINICAL SIGNS

P is a 12yr 2mo old FS German Shepherd presenting for a CT today of the abdomen and chest. Per the last radiology report, there was an alleged ill-defined mass caudal to the stomach that was not historically appreciated with P's previous U/S. P presenting for advanced imaging to investigate this suspected abnormality. P was fasted 12 hours before presentation.

Abnormal PE/Chem/CBC/UA Results: HCT 33.1 Low 36.9-60.0 % HGB 12.4 Low 13.2-22.0 g/dL RBC 4.66 Low 5.82-8.90 $10^6/uL$ MPV 7.3 Low 8.0-14.1 fL BUN 8.7 Low 9.0-29.0 mg/dl Phosphorus 5.2 High 1.9-5.0 mg/dl Total Protein 7.9 High Globulin 5.3 High

ULTRASONOGRAPHIC EXAMINATION OF THE ABDOMEN

Urinary System

The urinary bladder, trigone, cystourethral junction, and visible pelvic urethra to a depth of 3.0 cm exhibited normal thickness and tone. Anechoic urine was present in the lumen with no uroliths or sediment. The ureteral papillae were normal. The ureters were not visible which is normal. No evidence of inflammatory or neoplastic change were noted.

Normal size and margination was present in the kidneys. A normal 1:3 cortex / medulla ratio was maintained. The medulla and cortices were uniform in texture with some increased echogenicity and mild loss of corticomedullary symmetry and definition expected for the age of the patient. No evidence of pelvic dilation was present. The left kidney measured 7/4 cm in length. The right kidney measured 7.9 cm in length.

Adrenal Glands

The left adrenal gland was uniform in size and contour with a uniformly hypoechoic parenchyma. The left adrenal gland measured 0.54 cm width at the caudal pole.

The right adrenal gland was uniform in size and contour with a uniformly hypoechoic parenchyma. The right adrenal gland measured 0.72 cm width at the caudal pole.

Spleen

The spleen presented subjectively normal in size with primarily symmetrical contour. A solitary to possibly intermittent mildly expansive yet nondisruptive nonhomogenous hypoechoic splenic nodule/nodules was present. with an example measuring 1.2 cm in diameter.

Liver & Gallbladder

The liver presented subjective mild to possible moderately enlarged in size. The parenchyma of the liver was subjectively normal in echogenicity compared to the spleen and renal cortices. The liver parenchyma was uniform with a mildly coarse echotexture. The capsule of the liver was symmetrically rounded to mildly swollen in margination. The hepatic and portal vasculature were normal in appearance without signs of congestion. A fluid filled lesion was present in the left liver parenchyma exhibiting potential for mild encapsulation and containing echogenic fluid measuring approximately 4.6 cm in diameter.

The gallbladder was non distended in size with mild gravity dependent nonorganized to possibly adhered luminal surface debris. The common bile duct was not visualized. No evidence of peripheral gallbladder inflammation.



PATIENT

Sadie Cantu-Castillo

SPECIES

Canine

BREED

German Shepherd

SEX

Spayed Female

AGE

12 Years 2 Months

WEIGHT

58.5

INTERPRETED BY

R. McKenzie Daniel,
DVM, DABVP (Canine
/ Feline Practice)

IMAGING PERFORMED BY

Dr. Mych

HOSPITAL NAME

Craig Road Animal
Hospital

REFERRING VET

Cameron Johnson
DVM

INVOICE

15355

DATE

04/24/26

Gastrointestinal

The stomach presented intact wall layering with a normal wall layer ratio. The lumen of the stomach was empty with no signs of ileus, obstruction or foreign material.

The small intestine presented intact wall layering with 1:3 muscularis/mucosa ratio. The lumen of the small intestine was empty with no signs of ileus, obstruction or foreign material.

Normal visible colon wall layers were present with apparent formed feces in lumen.

Pancreas

The pancreas presented enlarged in size with capsule asymmetry and nonhomogenous hypoechoic parenchyma.

Free Abdomen

No overt lymphadenopathy was present. Hyperechoic fluid filled omentum in the ventral abdomen measuring approximately 7.0 cm to 8.0 cm in diameter with mild associated regional inflammation and minor peritoneal effusion.

ULTRASONOGRAPHIC FINDINGS

Primary Findings

- Hepatomegaly with intraparenchymal fluid filled lesion containing echogenic fluid- consistent with hepatic abscess.
- Nonorganized hyperechoic gallbladder debris (non-mucocele).
- Mildly expansive splenic nodule/nodules.
- Concurrent omental abscess versus necrotic lipoma or similar with associated mild to regional peritonitis.
- Enlarged nonhomogenous hypoechoic pancreas- pancreatitis, potential for pancreatic neoplasia is not excluded.

Secondary Findings

- Mild age-related renal changes.

INTERPRETATION OF THE FINDINGS & FURTHER RECOMMENDATIONS

Multicentric inflammation/infection or potential neoplasia are primary considerations. Further assessment may include (assuming normal clotting status) FNA cytology/centesis into liver and omental abscess as well as splenic nodule and pancreatic FNA cytology using a 25-gauge needle.

Correlation with a spec cPL is warranted. Gastrointestinal support if clinical signs are consistent with active pancreatitis as well as empirical therapy for peritonitis or systemic infection could be considered.



PATIENT

Sadie Cantu-Castillo

SPECIES

Canine

BREED

German Shepherd

SEX

Spayed Female

AGE

12 Years 2 Months

WEIGHT

58.5

INTERPRETED BY

R. McKenzie Daniel,
DVM, DABVP (Canine
/ Feline Practice)

IMAGING PERFORMED BY

Dr. Mych

HOSPITAL NAME

Craig Road Animal
Hospital

REFERRING VET

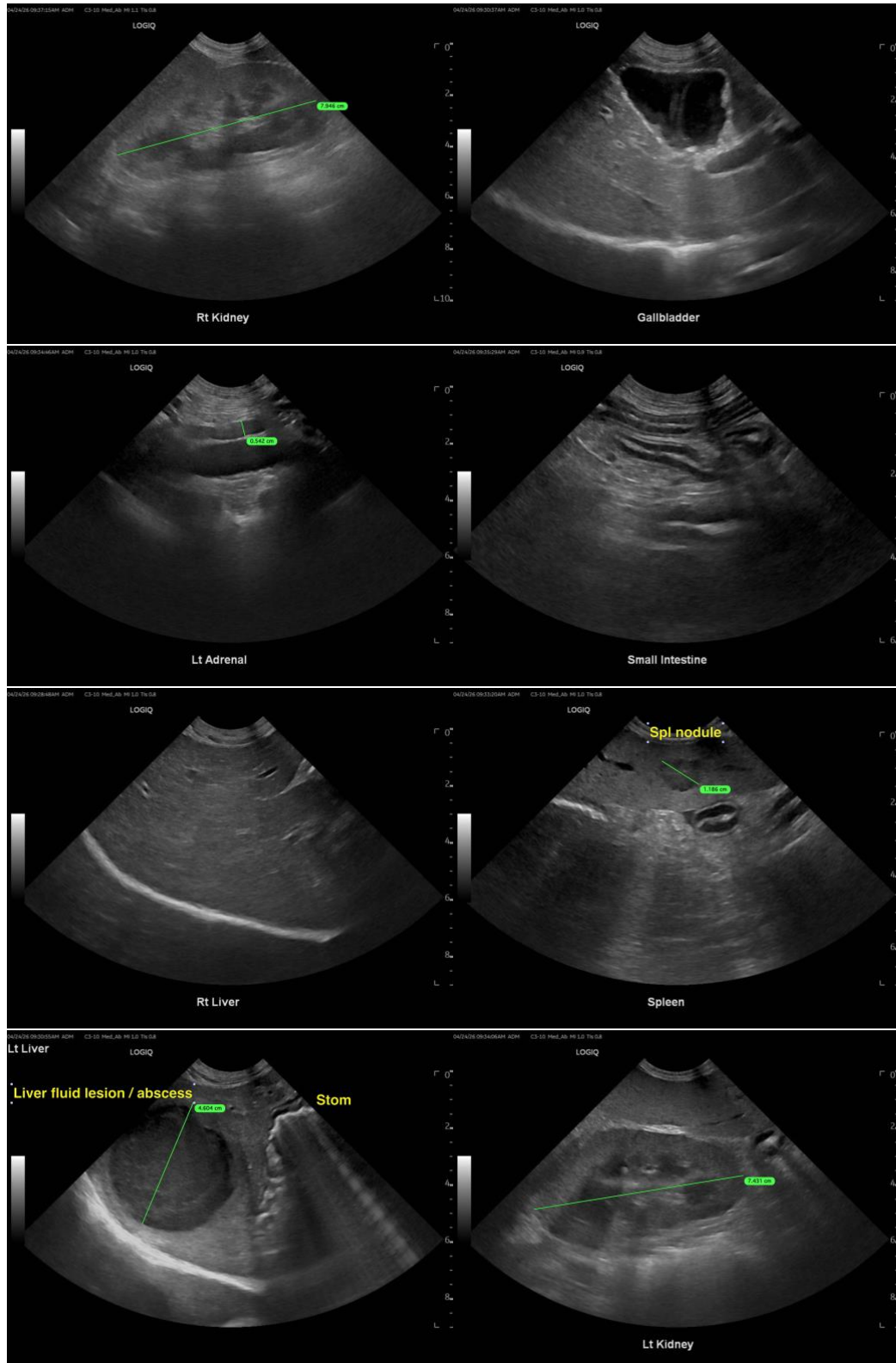
Cameron Johnson
DVM

INVOICE

15355

DATE

04/24/26





PATIENT

Sadie Cantu-Castillo

SPECIES

Canine

BREED

German Shepherd

SEX

Spayed Female

AGE

12 Years 2 Months

WEIGHT

58.5

INTERPRETED BY

R. McKenzie Daniel,
DVM, DABVP (Canine
/ Feline Practice)

IMAGING PERFORMED BY

Dr. Mych

HOSPITAL NAME

Craig Road Animal
Hospital

REFERRING VET

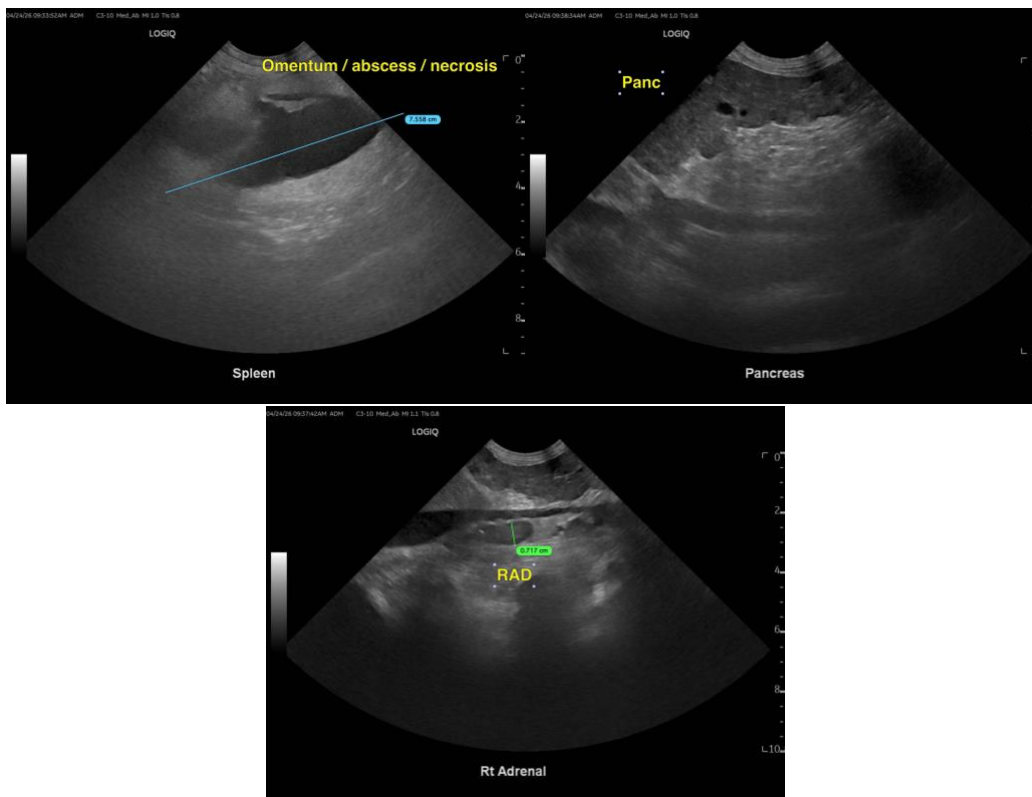
Cameron Johnson
DVM

INVOICE

15355

DATE

04/24/26



The information and recommendations provided are based on the images presented by the referring veterinarian/sonographer. No evaluation can be communicated regarding pathology that was not visible in the image/video clips provided.

Thank you for this referral. If the clinical or image interpretation does not parallel your findings or if I can be of any further assistance, please contact me.

R. McKenzie Daniel, DVM, DABVP (Canine / Feline Practice)

info@SonoPath.com