



## PATIENT

Batista Wallace

## SPECIES

Canine

## BREED

Boxer Mix

## SEX

Neutered Male

## AGE

13 Years

## WEIGHT

66 pounds

## INTERPRETED BY

R. McKenzie Daniel,  
DVM, DABVP (Canine  
/ Feline Practice)

## IMAGING PERFORMED BY

Dr. Meaghan Godwin

## HOSPITAL NAME

Wellesley Animal  
Hospital

## REFERRING VET

Dr. Meaghan Godwin

## INVOICE

15437

## DATE

04/24/26

## PRESENTING CLINICAL SIGNS

Submitted study contained 15 videos of the urinary bladder and prostate only.

History of weakness and straining to urinate per o.

Abnormal PE/Chem/CBC/UA Results: 15 pound weight loss in 1 year UA: significant hematuria and some WBCs present CBC/chem: Mild monocytosis, hyperglobulinemia, elevated ALP

## LIMITED ULTRASONOGRAPHIC EXAMINATION

The prostate was mildly enlarged in size with capsule asymmetry and nonhomogenous, hypoechoic, mineralized parenchyma. Mild surrounding periprostatic inflammation. The prostate measured 4.6 cm x 3.0 cm.

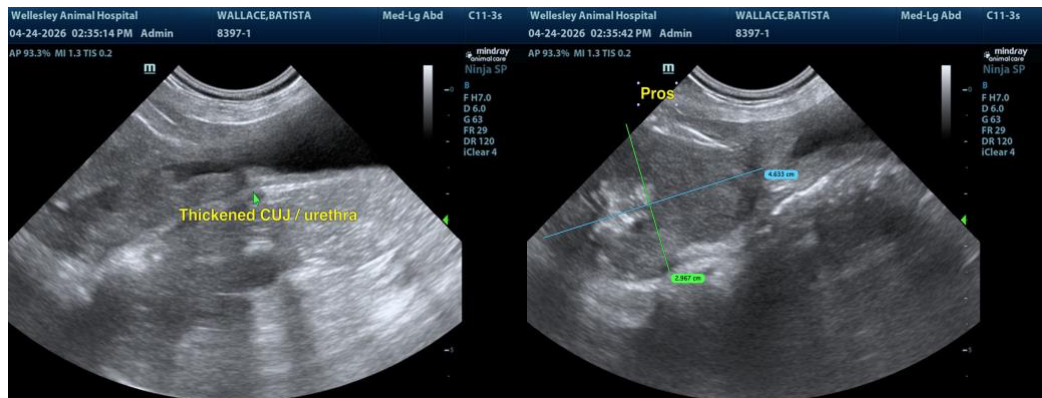
Thickened periprostatic urethra extending into the cystourethral junction. The cystourethral junction wall measured 0.42 cm. Overall bladder exhibited normal size and tone with primarily normal nonthickened urinary bladder body and apical wall. The bladder contained anechoic urine with no mineral or calculi.

## ULTRASONOGRAPHIC FINDINGS

- Residual prostatomegaly exhibiting nonhomogenous mineralized parenchyma most consistent with prostatic neoplasia i.e. prostatic or transitional cell carcinoma.
- Nondistended urinary bladder.
- Mildly thickened periprostatic urethra and cystourethral junction- concern for extension of neoplasia versus inflammation.

## INTERPRETATION OF THE FINDINGS & FURTHER RECOMMENDATIONS

Prostatic sampling could be considered for further clarification either via ultrasound guided FNA cytology or prostatic wash. Concurrent BRAF assay if possible is warranted.





## PATIENT

Batista Wallace

## SPECIES

Canine

## BREED

Boxer Mix

## SEX

Neutered Male

## AGE

13 Years

## WEIGHT

66 pounds

## INTERPRETED BY

R. McKenzie Daniel,  
DVM, DABVP (Canine  
/ Feline Practice)

## IMAGING PERFORMED BY

Dr. Meaghan Godwin

## HOSPITAL NAME

Wellesley Animal  
Hospital

## REFERRING VET

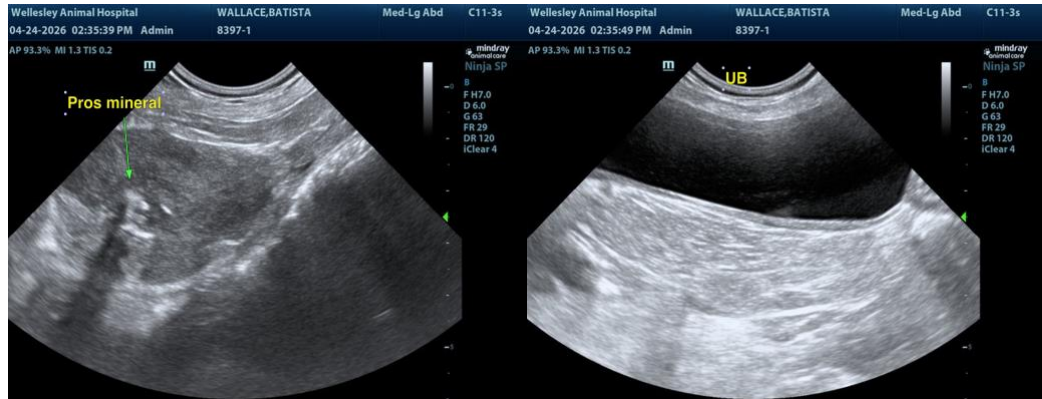
Dr. Meaghan Godwin

## INVOICE

15437

## DATE

04/24/26



The information and recommendations provided are based on the images presented by the referring veterinarian/sonographer. No evaluation can be communicated regarding pathology that was not visible in the image/video clips provided.

Thank you for this referral. If the clinical or image interpretation does not parallel your findings or if I can be of any further assistance, please contact me.

R. McKenzie Daniel, DVM, DABVP (Canine / Feline Practice)

[info@SonoPath.com](mailto:info@SonoPath.com)