



PATIENT

Max Morrison

SPECIES

Canine

BREED

Labrador Retriever

SEX

MN

AGE

5 yrs

WEIGHT

84.1 lbs.

INTERPRETED BY

R. McKenzie Daniel,
DVM, DABVP
(Canine and Feline)

IMAGING PERFORMED BY

Harold Mike Beard

HOSPITAL NAME

Animal Care
Veterinary Center

REFERRING VET

Kayla Anthony

INVOICE

10826

DATE

4/22/26

PRESENTING CLINICAL SIGNS

Non therapeutic Phenobarb, uncontrolled seizures.

Abnormal PE/Chem/CBC/UA Results: Mildly elevated ALT, ALKP, GGT.

ULTRASONOGRAPHIC EXAMINATION OF THE ABDOMEN

Urinary System

The urinary bladder, trigone, and cystourethral junction exhibited normal thickness and tone. Anechoic urine was present in the lumen with no uroliths or sediment. The ureteral papillae were normal. The ureters were not visible which is normal. No evidence of inflammatory or neoplastic changes were noted.

The area of the residual prostate appeared normal and free of pathology

No evidence of pathology in the area of the aortic trifurcation.

Normal size and margination were present in the kidneys. A normal 1:3 cortex / medulla ratio and normal corticomedullary definition were maintained. The echogenicity of the cortex was similar to or slightly less than normal liver parenchyma while the medulla echogenicity was hypoechoic to the cortex with no evidence of pelvic dilation. The left kidney measured 7.3 cm in length. The right kidney measured 7.9 cm in length.

Adrenal Glands

The left adrenal gland was uniform in size and contour with a uniformly hypoechoic parenchyma. The left adrenal gland measured 0.62 cm width at the caudal pole. The right adrenal gland was indistinctly visualized without overt pathology. Subjectively, the right adrenal gland measured 0.58 cm width.

Spleen

The spleen exhibited a finely textured and homogenous parenchyma which was hyperechoic to the liver and renal cortical parenchyma. The capsule was smooth and regular without apparent expansion. The splenic vasculature at the hilus was normal in volume with no evidence of congestion or thrombosis. Acute to chronic inflammatory, neoplastic, or benign parenchyma changes were not noted.

Liver/ Gallbladder

The liver was subjectively normal in size, structure, and contour. Normal hepatic vascular volume was present. The liver parenchyma was uniform and hypoechoic to the spleen with a mild coarse echotexture. The hepatic and portal vasculature were normal in appearance without signs of congestion. The gallbladder was non-distended in size containing primarily anechoic content with minor nonorganized gallbladder debris. The cystic and common bile ducts were normal.

Gastrointestinal

The stomach presented intact wall layering with a normal wall layer ratio. The lumen of the stomach contained mild, nonshadowing ingesta, consistent with food echogenicity without signs of obstruction or foreign material.



PATIENT

Max Morrison

SPECIES

Canine

BREED

Labrador Retriever

SEX

MN

AGE

5 yrs

WEIGHT

84.1 lbs.

The small intestine presented intact wall layering with 1:3 muscularis/mucosa ratio. The lumen of the small intestine was empty with no signs of ileus, obstruction, or foreign material.

Normal visible colon wall layers were present with formed feces in lumen.

Pancreas

The parenchyma of the left limb, body and right limb of the pancreas presented isoechoic to the adjacent omental fat. A normal curvilinear capsule contour of the pancreas was present. The visible pancreatic duct was normal. No signs of active inflammation or neoplastic disease was evident.

Free Abdomen

No overt lymphadenopathy or peritoneal effusion was present.

ULTRASONOGRAPHIC FINDINGS

- Sonographically unremarkable normal volume liver
- Minor gallbladder debris (non-mucocele)
- Gastric ingesta – consistent with food echogenicity

INTERPRETATION OF THE FINDINGS & FURTHER RECOMMENDATIONS

There is no evidence of significant visceral pathology as a definitive cause of the uncontrolled seizures. There is no overt evidence of hepatic vascular anomaly or intrahepatic / extrahepatic macroscopic shunt. Correlation with bile acid profile may be considered.

For an additional charge, internal medicine consult can be utilized through SonoPath.com. You can select the internal medicine drop down at <http://spa.sonopath.com/>.

One of the world's top internists & SonoPath associate Dr. Remo Lobetti BVSc, MMedVet, PhD, DECVIM can evaluate your case through SonoPath. <https://sonopath.com/resources/sonopath-services/internal-medicine-teleconsultation-services>

INTERPRETED BY

R. McKenzie Daniel,
DVM, DABVP
(Canine and Feline)

IMAGING PERFORMED BY

Harold Mike Beard

HOSPITAL NAME

Animal Care
Veterinary Center

REFERRING VET

Kayla Anthony

INVOICE

10826

DATE

4/22/26



PATIENT

Max Morrison

SPECIES

Canine

BREED

Labrador Retriever

SEX

MN

AGE

5 yrs

WEIGHT

84.1 lbs.

INTERPRETED BY

R. McKenzie Daniel,
DVM, DABVP
(Canine and Feline)

IMAGING PERFORMED BY

Harold Mike Beard

HOSPITAL NAME

Animal Care Veterinary Center
Veterinary Center

REFERRING VET

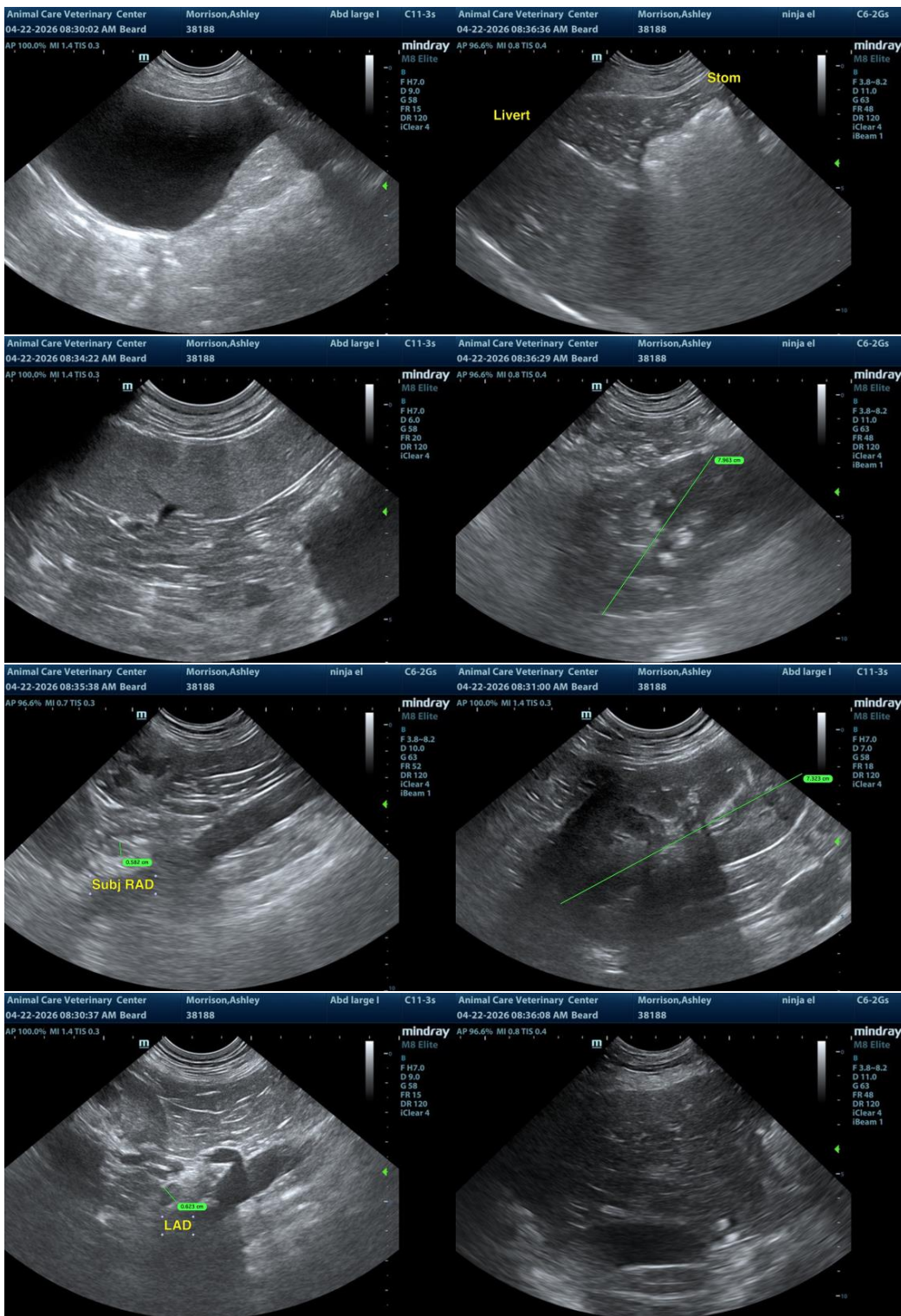
Kayla Anthony

INVOICE

10826

DATE

4/22/26





PATIENT

Max Morrison

SPECIES

Canine

BREED

Labrador Retriever

SEX

MN

AGE

5 yrs

WEIGHT

84.1 lbs.

INTERPRETED BY

R. McKenzie Daniel,
DVM, DABVP
(Canine and Feline)

IMAGING PERFORMED BY

Harold Mike Beard

HOSPITAL NAME

Animal Care
Veterinary Center

REFERRING VET

Kayla Anthony

INVOICE

10826

DATE

4/22/26

The information and recommendations provided are based on the images presented by the referring veterinarian/sonographer. No evaluation can be communicated regarding pathology that was not visible in the image/video clips provided.

Thank you for this referral. If the clinical or image interpretation does not parallel your findings or if I can be of any further assistance, please contact me.

R. McKenzie Daniel, DVM, DABVP (Canine/Feline Practice)
info@sonopath.com