



PATIENT

Enola Cozzi

SPECIES

Feline

BREED

DSH

SEX

FS

AGE

5Y

WEIGHT

8.2lbs

INTERPRETED BY

R. McKenzie Daniel,
DVM, DABVP
(Canine and Feline)

IMAGING PERFORMED BY

Heather Platzer

HOSPITAL NAME

Hershire Animal
Hospital

REFERRING VET

Laura Wojcik, DVM

INVOICE

74721

DATE

4-22-26

PRESENTING CLINICAL SIGNS

Seen for intermittent vomiting, severe periodontal dz, no diarrhea. CBC/chem/T4--wnl except mild neutropenia 2.22K. Getting AUS while here for dental procedure in case it's not periodontal dz related.

ULTRASONOGRAPHIC EXAMINATION OF THE ABDOMEN

Urinary System

The urinary bladder, trigone, cystourethral junction, and visible pelvic urethra exhibited normal thickness and tone. Anechoic urine was present in the lumen with no uroliths or sediment. The ureteral papillae were normal. The ureters were not visible, which is normal. No evidence of inflammatory or neoplastic changes were noted.

No evidence of pathology in the area of the aortic trifurcation.

Normal size and margination were present in the kidneys. A normal 1:3 cortex / medulla ratio and normal corticomedullary definition were maintained. The echogenicity of the cortex was similar to or slightly less than normal liver parenchyma while the medulla echogenicity was hypoechoic to the cortex with no evidence of pelvic dilation. The left kidney measured 3.3 cm in length. The right kidney measured 3.5 cm in length.

Adrenal Glands

The left adrenal gland was uniform in size and contour with a uniformly hypoechoic parenchyma. The left adrenal gland measured 0.30 cm width. The right adrenal gland was uniform in size and contour with a uniformly hypoechoic parenchyma. The right adrenal gland measured 0.34 cm width.

Spleen

The spleen exhibited a finely textured and homogenous parenchyma which was hyperechoic to the liver and renal cortical parenchyma. The capsule was smooth and regular without apparent expansion. The splenic vasculature at the hilus was normal in volume with no evidence of congestion or thrombosis. Acute to chronic inflammatory, neoplastic, or benign parenchyma changes were not noted.

Liver/ Gallbladder

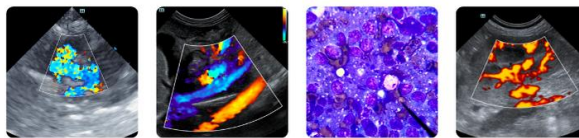
The liver was subjectively normal in size, structure, and contour. Normal hepatic vascular volume was present. The liver parenchyma was uniform and hypoechoic to the spleen with a mild coarse echotexture. The hepatic and portal vasculature were normal in appearance without signs of congestion. The gallbladder was non-distended in size with thin walls and primarily anechoic luminal content. The cystic and common bile ducts were normal.

Gastrointestinal

The stomach presented intact wall layering with a normal wall layer ratio. Minor retained pyloric fluid was present. The lumen of the stomach was empty without evidence of retained ingesta or foreign material.

The small intestine presented intact wall layering with 1:3 muscularis/mucosa ratio. The lumen of the small intestine was empty with no signs of ileus, obstruction, or foreign material. The duodenum wall measured 0.24 cm wall width. The jejunum wall measured 0.25 cm wall width.

Normal visible colon wall layers were present with formed feces in lumen.



PATIENT

Enola Cozzi

SPECIES

Feline

BREED

DSH

SEX

FS

AGE

5Y

WEIGHT

8.2lbs

Pancreas

The parenchyma of the left limb, body and right limb of the pancreas presented isoechoic to the adjacent omental fat. A normal curvilinear capsule contour of the pancreas was present. The visible pancreatic duct was normal. No signs of active inflammation or neoplastic disease was evident.

Free Abdomen

No overt lymphadenopathy or peritoneal effusion was present.

ULTRASONOGRAPHIC FINDINGS

- Normal gastrointestinal tract with minor retained pyloric fluid.
- Normal pancreas.

INTERPRETATION OF THE FINDINGS & FURTHER RECOMMENDATIONS

No evidence of visceral, specifically gastrointestinal or pancreatic, pathology.

Dietary trial and as needed gastroprotectants may prove beneficial.

Sonographic reassessment is recommended if progressive gastrointestinal signs.

INTERPRETED BY

R. McKenzie Daniel,
DVM, DABVP
(Canine and Feline)

IMAGING PERFORMED BY

Heather Platzer

HOSPITAL NAME

Hershire Animal
Hospital

REFERRING VET

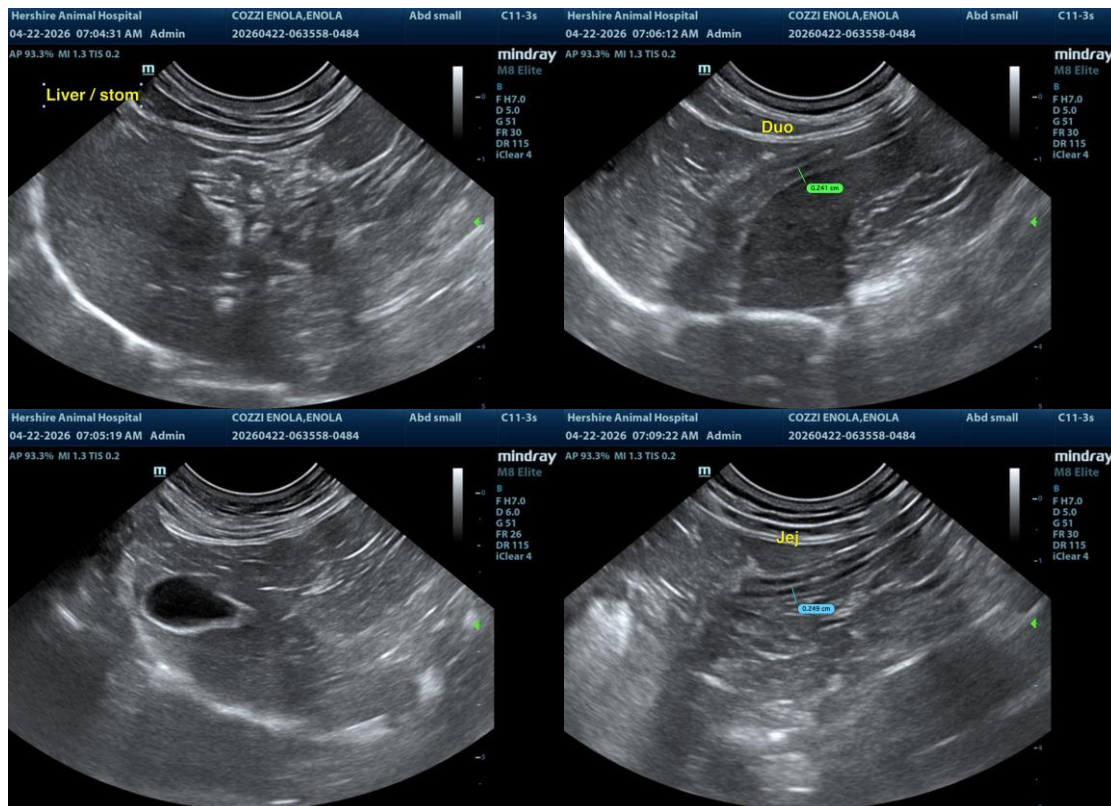
Laura Wojcik, DVM

INVOICE

74721

DATE

4-22-26





PATIENT

Enola Cozzi

SPECIES

Feline

BREED

DSH

SEX

FS

AGE

5Y

WEIGHT

8.2lbs

INTERPRETED BY

R. McKenzie Daniel,
DVM, DABVP
(Canine and Feline)

IMAGING PERFORMED BY

Heather Platzer

HOSPITAL NAME

Hershire Animal
Hospital

REFERRING VET

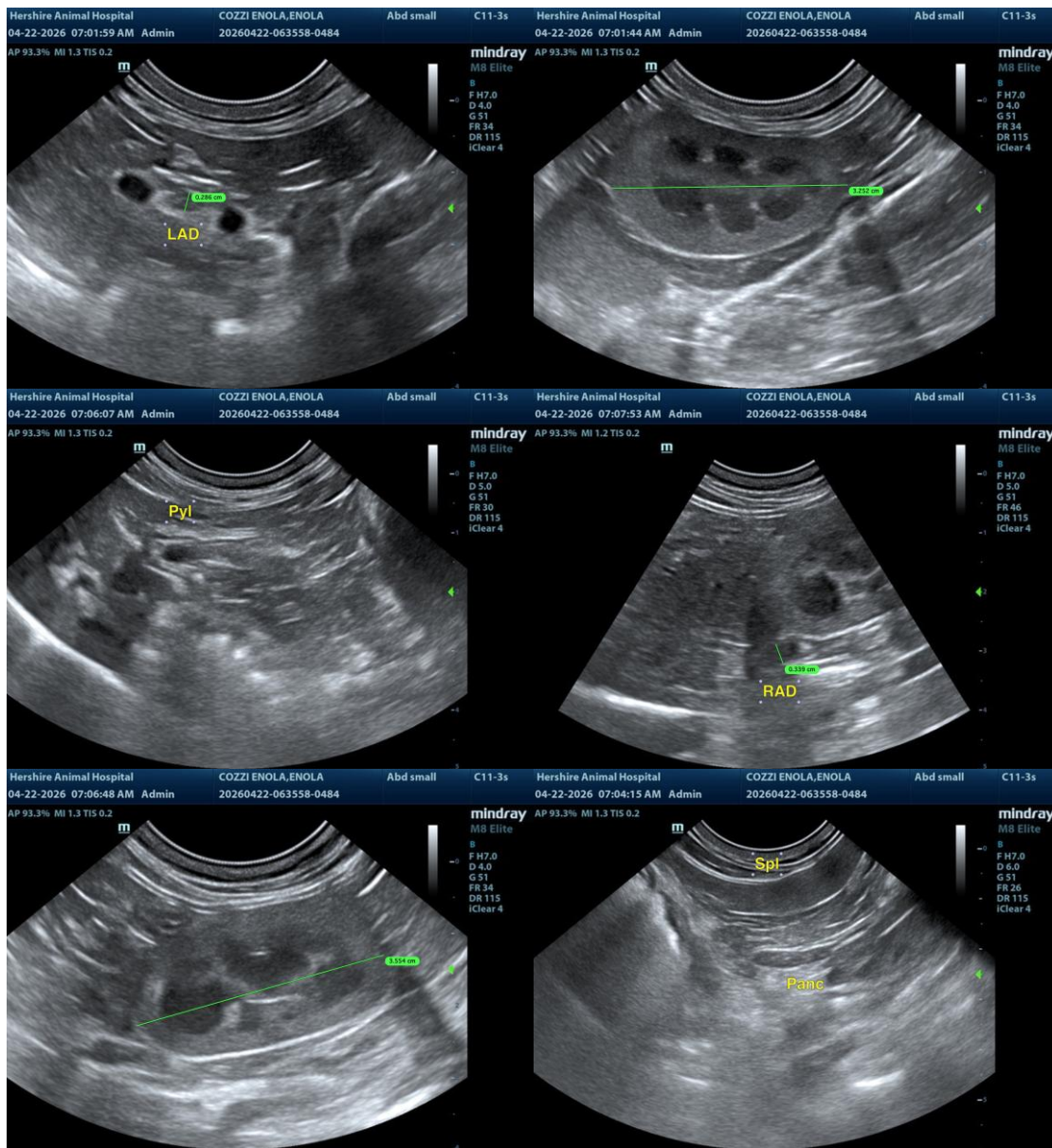
Laura Wojcik, DVM

INVOICE

74721

DATE

4-22-26



The information and recommendations provided are based on the images presented by the referring veterinarian/sonographer. No evaluation can be communicated regarding pathology that was not visible in the image/video clips provided.

Thank you for this referral. If the clinical or image interpretation does not parallel your findings or if I can be of any further assistance, please contact me.

R. McKenzie Daniel, DVM, DABVP (Canine/Feline Practice)
info@sonopath.com