



PATIENT

Winston Karr

SPECIES

Canine

BREED

Terrier

SEX

MN

AGE

7 years

WEIGHT

18 lbs.

INTERPRETED BY

R. McKenzie Daniel,
DVM, DABVP
(Canine and Feline)

**IMAGING
PERFORMED BY**

Sara Hansen

HOSPITAL NAME

The Veterinary
Hospital

REFERRING VET

Dr. Johnson

INVOICE

13711

DATE

4/22/22

PRESENTING CLINICAL SIGNS

recurrent episodes of vomiting

Abnormal PE/Chem/CBC/UA Results: CBC & Chem were unremarkable - mild elevation in TP (4.2) and low K+(3.) consistent with vomiting and dehydration Current Medications had cerenia by injection 4/21/ 4:30 PM

ULTRASONOGRAPHIC EXAMINATION OF THE ABDOMEN

Urinary System

The urinary bladder, trigone, cystourethral junction, and visible pelvic urethra to a depth of 4.0 cm exhibited normal thickness and tone. Anechoic urine was present in the lumen with no uroliths or sediment. The ureteral papillae were normal. The ureters were not visible which is normal. No evidence of inflammatory or neoplastic changes was noted.

The residual prostate was symmetrically normal in size with uniform parenchyma and slight coarse echotexture measuring 0.83 cm in diameter.

The area of the aortic trifurcation was free of pathology.

Normal size and margination were present in the kidneys. A normal 1:3 cortex / medulla ratio and normal corticomedullary definition were maintained. The echogenicity of the cortex was similar to or slightly less than normal liver parenchyma while the medulla echogenicity was hypoechoic to the cortex with no evidence of pelvic dilation. The left kidney measured 4.2 cm in length. The right kidney measured 4.3 cm in length.

Adrenal Glands

The left adrenal gland was uniform in size and contour with a uniformly hypoechoic parenchyma. The left adrenal gland measured 1.8 cm length x 0.56 cm width at the caudal pole. The right adrenal gland was uniform in size and contour with a uniformly hypoechoic parenchyma. The right adrenal gland measured 1.7 cm length x 0.80 cm width at the caudal pole.

Spleen

The spleen exhibited a finely textured and homogenous parenchyma which was hyperechoic to the liver and renal cortical parenchyma. The capsule was smooth and regular without apparent expansion. The splenic vasculature at the hilus was normal in volume with no evidence of congestion or thrombosis. Acute to chronic inflammatory, neoplastic, or benign parenchyma changes were not noted.

Liver/ Gallbladder

The liver was subjectively normal in size, structure, and contour. The liver parenchyma was uniform and hypoechoic to the spleen with a mild coarse echotexture. The hepatic and portal vasculature were normal in appearance without signs of congestion. The gallbladder was non-distended in size with thin walls and primarily anechoic luminal content. The cystic and common bile ducts were normal.



PATIENT

Gastrointestinal

Winston Karr

The stomach presented intact yet mildly prominent wall layering primarily in the area of the antrum and pylorus. The stomach exhibited moderate distention with retained primarily anechoic fluid. No evidence of retained gastric ingesta, shadowing echo suggestive of foreign material, or evidence of mechanical pyloric outflow obstruction. The ventral pylorus wall width measured 0.43 cm.

SPECIES

Canine

BREED

Terrier

SEX

MN

AGE

7 years

Minor fluid distention of the upper duodenum was present with the mid to distal duodenum empty exhibiting intact and sonographically unremarkable duodenal wall layering. The duodenum wall width measured 0.29 cm. The jejunum to the level of the ileum exhibited primarily intact wall layering and maintained a 1:3 muscularis/mucosa ratio. Segmental intact yet mildly prominent to thickened, likely jejunum in the mid to cranial abdomen caudal to the stomach was present, measuring potentially 4.0-5.0 cm in length and exhibiting wall width up to 0.47 cm. Within this segmentally thickened segment of likely jejunum was increased gas artifact with potential for small focally shadowing nonspecific luminal echo measuring approximately 0.7-0.8 cm in diameter. By comparison, normal empty jejunum measured 0.26 cm. No overt evidence of mechanical obstructive pattern i.e., no evidence of segmental small intestinal fluid, dilation, or distention.

WEIGHT

18 lbs.

Normal visible colon wall layers were present with apparent formed feces in lumen.

Pancreas

The parenchyma of the left limb, body, and right limb of the pancreas presented isoechoic to the adjacent omental fat. A normal curvilinear capsule contour of the pancreas was present. The visible pancreatic duct was normal. No signs of active inflammation or neoplastic disease were evident.

INTERPRETED BY

R. McKenzie Daniel,
DVM, DABVP
(Canine and Feline)

Free Abdomen

Regional segmental peri intestinal reactive mesentery was noted around the segmentally thickened segment of likely jejunum without evidence of concurrent or significant lymphadenopathy, as well as no evidence of peritoneal free fluid.

IMAGING PERFORMED BY

Sara Hansen

ULTRASONOGRAPHIC FINDINGS

- Subjective hypomotile gastritis and likely concurrent mild upper duodenitis
- Segmentally thickened subjective jejunum with increased luminal gas and potential for focal small shadowing luminal echo
- Associated mild peri-jejunal reactive mesentery

HOSPITAL NAME

The Veterinary Hospital

REFERRING VET

Dr. Johnson

INTERPRETATION OF THE FINDINGS & FURTHER RECOMMENDATIONS

INVOICE

13711

DATE

4/22/22

The stomach, upper duodenal, and segmental jejunal presentation may indicate acute segmental inflammatory bowel episode potentially owing to dietary indiscretion, infectious gastroenterocolitis, IBD, or other gastroenteropathy. However, the possibility of a potential small nonobstructive passing foreign body could be present and cannot be excluded. No overt evidence of a mechanical obstructive pattern was present at this time. 24-hour hospitalization with IV fluid and gastrointestinal support with sonographic monitoring to assess for potential nonobstructive to passing small foreign



PATIENT

Winston Karr

SPECIES

Canine

BREED

Terrier

SEX

MN

AGE

7 years

WEIGHT

18 lbs.

INTERPRETED BY

R. McKenzie Daniel,
DVM, DABVP
(Canine and Feline)

IMAGING PERFORMED BY

Sara Hansen

HOSPITAL NAME

The Veterinary
Hospital

REFERRING VET

Dr. Johnson

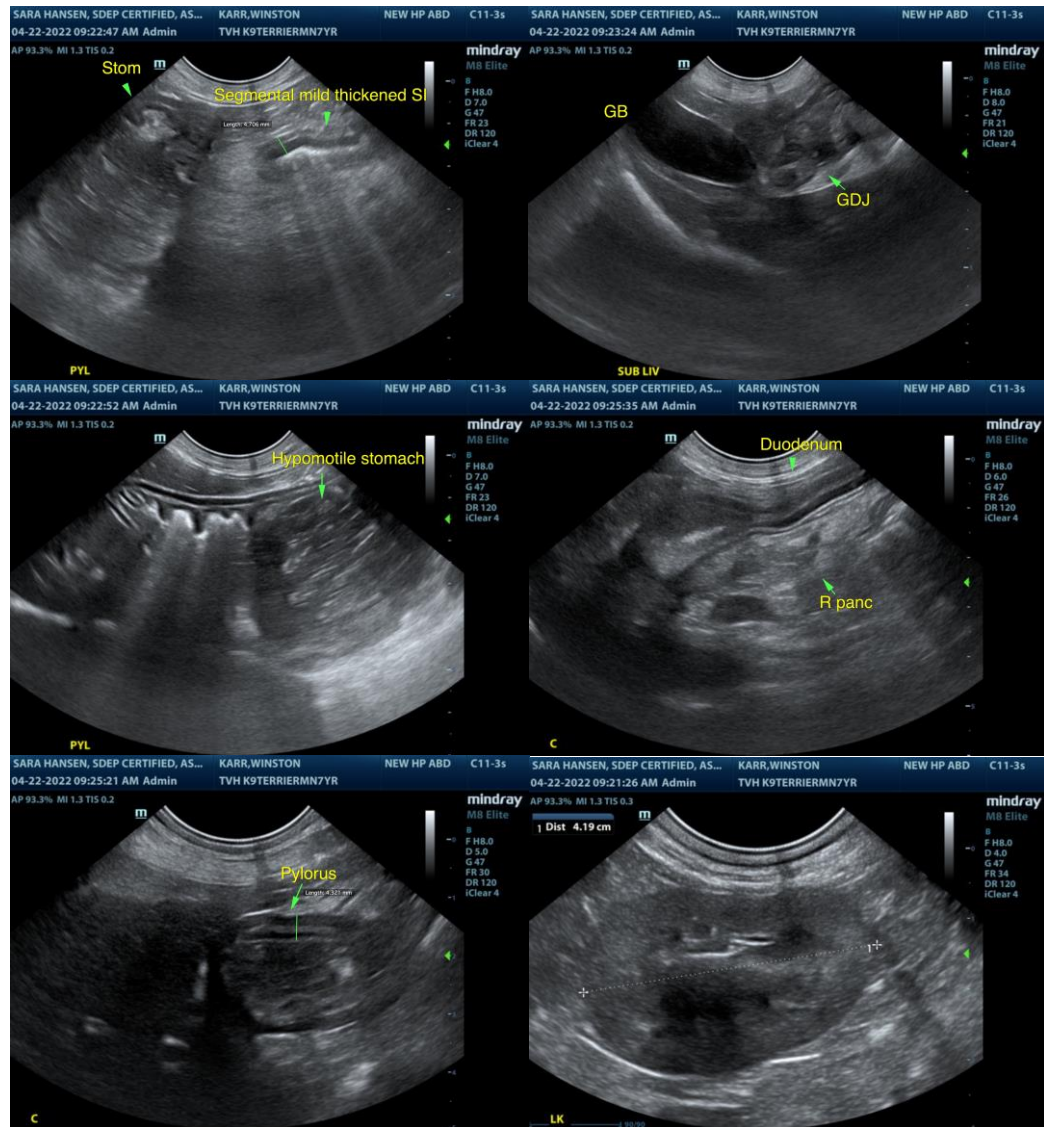
INVOICE

13711

DATE

4/22/22

body would be reasonable. Depending upon further reassessment or if continued episodes of vomiting, exploratory laparotomy for gross inspection of the intestinal tract with Intestinal biopsies considered essential despite exploratory findings may be indicated.





PATIENT

Winston Karr

SPECIES

Canine

BREED

Terrier

SEX

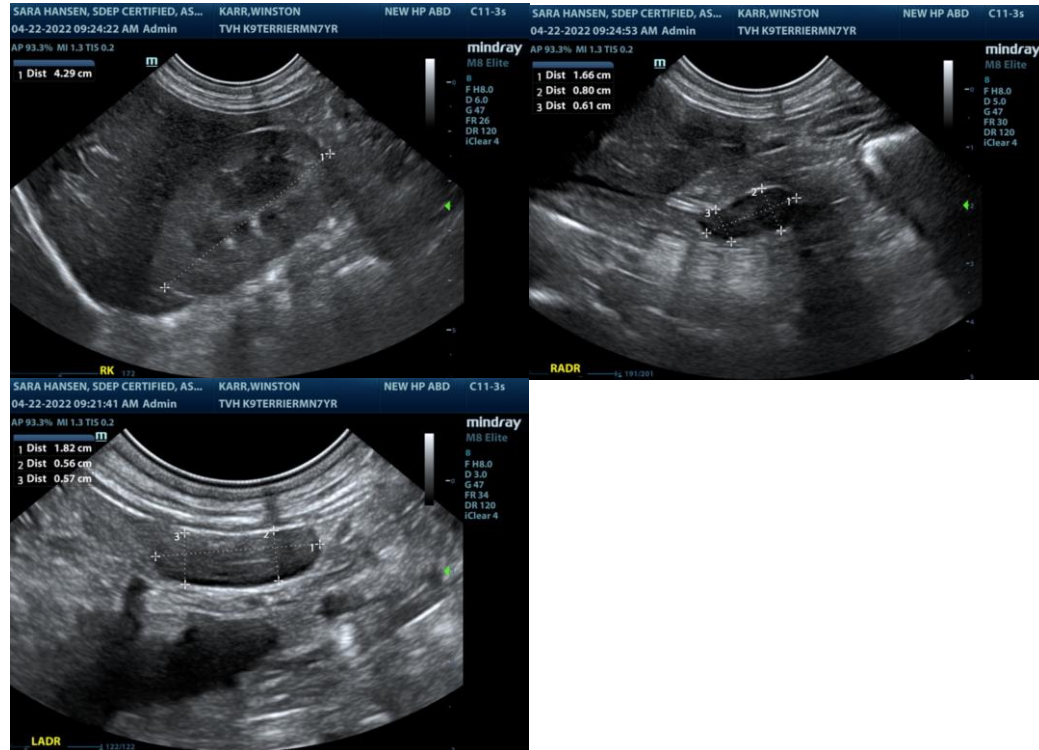
MN

AGE

7 years

WEIGHT

18 lbs.



INTERPRETED BY

R. McKenzie Daniel,
DVM, DABVP
(Canine and Feline)

IMAGING PERFORMED BY

Sara Hansen

The information and recommendations provided are based on the images presented by the referring veterinarian/sonographer. No evaluation can be communicated regarding pathology that was not visible in the image/video clips provided.

Thank you for this referral. If the clinical or image interpretation does not parallel your findings or if I can be of any further assistance please contact me.

HOSPITAL NAME

The Veterinary
Hospital

R. McKenzie Daniel, DVM, DABVP (Canine / Feline Practice)
info@SonoPath.com

REFERRING VET

Dr. Johnson

INVOICE

13711

DATE

4/22/22