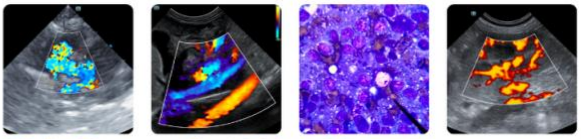

PATIENT
Prince Jem

SPECIES
Canine

BREED
Chihuahua Mix

SEX
Intact Male

AGE
13 Years 2 Months

WEIGHT
23.5 pounds

INTERPRETED BY
R. McKenzie Daniel, DVM, DABVP (Canine / Feline Practice)

IMAGING PERFORMED BY
Dr. Adrienne Hou

HOSPITAL NAME
Marina Village Veterinary & Integrative Care

REFERRING VET
Dr. Adrienne Hou

INVOICE
15322

DATE
04/21/26

PRESENTING CLINICAL SIGNS

Decreased appetite, lethargic for the past ten days. Acute large bowel diarrhea after starting oral Clavamox to treat eyelid infection.

PE- Right eye: moderate swelling of superior lid. Left submandibular subcutaneous swelling, firm, ~3cm (cytology consistent with reactive lymphoid hyperplasia). Unremarkable thoracic radiographs. Mild non-regenerative anemia (PCV=32.9%), ALP=325 Abdominal rads two weeks ago: diffuse hepatomegaly and splenomegaly. Given that both organs are enlarged in size, the possibility of an infiltrative process (lymphoma), could be considered. Separate etiologies for these changes are also considered (liver - endocrinopathy, prior drug therapy, inflammatory disease. Spleen - EMH, lymphoid hyperplasia). Correlate with ultrasound, if indicated

ULTRASONOGRAPHIC EXAMINATION OF THE ABDOMEN

Urinary System

The urinary bladder, trigone, cystourethral junction, and visible pelvic urethra exhibited normal thickness and tone. Anechoic urine was present in the lumen with no uroliths or sediment. The ureteral papillae were normal. The ureters were not visible which is normal. No evidence of inflammatory or neoplastic change were noted.

The area of the aortic trifurcation was free of pathology.

The prostate was enlarged in size with intact, symmetrical capsule contour. The margins of the gland were intact and able to be differentiated from the surrounding tissue. The prostatic parenchyma was mildly echogenic to heteroechoic without parenchymal mineralization. The prostate measured 3.1 cm.

Normal size and margination was present in the kidneys. A normal 1:3 cortex / medulla ratio and normal corticomedullary definition were maintained. The echogenicity of the cortex was similar to or slightly less than normal liver parenchyma while the medulla echogenicity was hypoechoic to the cortex with no evidence of pelvic dilation. The left kidney measured 5.2 cm in length. The right kidney measured 5.3 cm in length.

Adrenal Glands

The left adrenal gland was uniform in size and contour with a uniformly hypoechoic parenchyma. The left adrenal gland measured 0.56 cm width at the caudal pole.

The right adrenal gland was uniform in size and contour with a uniformly hypoechoic parenchyma. The right adrenal gland measured 0.48 cm width at the caudal pole.

Spleen

The spleen was subjective borderline enlarged and exhibited a finely textured and homogenous parenchyma which was hyperechoic to the liver and renal cortical parenchyma. The capsule was smooth and regular without apparent expansion. The splenic vasculature at the hilus was normal in volume with no evidence of congestion or thrombosis. Acute to chronic inflammatory, neoplastic, or benign parenchyma changes were not noted.

Liver & Gallbladder

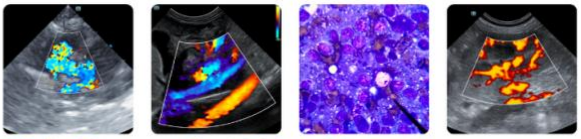

PATIENT
Prince Jem

SPECIES
Canine

BREED
Chihuahua Mix

SEX
Intact Male

AGE
13 Years 2 Months

WEIGHT
23.5 pounds

INTERPRETED BY
R. McKenzie Daniel, DVM, DABVP (Canine / Feline Practice)

IMAGING PERFORMED BY
Dr. Adrienne Hou

HOSPITAL NAME
Marina Village Veterinary & Integrative Care

REFERRING VET
Dr. Adrienne Hou

INVOICE
15322

DATE
04/21/26

The liver presented enlarged in size. The parenchyma of the liver was subjectively normal in echogenicity compared to the spleen and renal cortices. The liver parenchyma was uniform with a mildly coarse echotexture. The capsule of the liver was symmetrically rounded to mildly swollen in margination. The hepatic and portal vasculature were normal in appearance without signs of congestion.

The gallbladder was non-distended in size with thin walls and primarily anechoic luminal content. The cystic and common bile ducts were normal.

Gastrointestinal

The stomach presented intact wall layering with a normal wall layer ratio. The lumen of the stomach was empty with no signs of ileus, obstruction or foreign material.

The small intestine presented intact wall layering with 1:3 muscularis/mucosa ratio. The lumen of the small intestine was empty with no signs of ileus, obstruction or foreign material.

The colon walls presented intact yet mildly prominent wall layering. Semiformed fecal matter was present in the colon lumen.

Pancreas

The left pancreas presented mildly prominent in size exhibiting mild nonhomogenous parenchyma. No evidence of peripancreatic inflammation.

Free Abdomen

No overt lymphadenopathy or peritoneal effusion was present.

ULTRASONOGRAPHIC FINDINGS

- Sonographically unremarkable gastrointestinal tract, mild colitis pattern.
- Mildly prominent nonhomogenous left pancreas.
- Hepatomegaly with borderline splenomegaly- nonspecific.
- Benign prostatic hyperplasia, minor potential for prostatitis.

INTERPRETATION OF THE FINDINGS & FURTHER RECOMMENDATIONS

The hepatosplenic enlargement did not overtly meet neoplastic criteria with benign etiologies i.e. hyperplasia, inflammation, vacuolar or cholestatic hepatopathy given ALP elevation or other favored.

Assuming normal clotting status and using a 25-gauge needle, hepatosplenic FNA cytology is warranted to assess for occult disease as a contributing factor to the patient's clinical signs. A spec cPL is suggested to correlate with pancreas and assess for possible mild to chronic pancreatitis. Gastrointestinal support is recommended pending additional diagnostics. No overt adrenal pathology as a contributing factor to the hepatopathy. A GI panel to include PLI/TLI/Cobalamin/Folate and cortisol level are recommended.

SonoPath
FOSTERING THE ART OF VETERINARY MEDICINE™

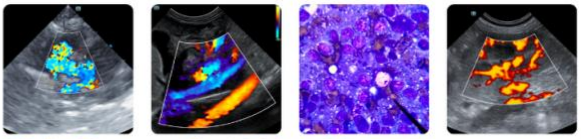

Clinical Sonography & Telecytology
Educational Teleconsultation Services™

SonoPath.com info@sonopath.com 1.800.838.4268

PATIENT

Prince Jem

SPECIES

Canine

BREED

Chihuahua Mix

SEX

Intact Male

AGE

13 Years 2 Months

WEIGHT

23.5 pounds

INTERPRETED BY

R. McKenzie Daniel, DVM, DABVP (Canine / Feline Practice)

IMAGING PERFORMED BY

Dr. Adrienne Hou

HOSPITAL NAME

Marina Village Veterinary & Integrative Care

REFERRING VET

Dr. Adrienne Hou

INVOICE

15322

DATE

04/21/26

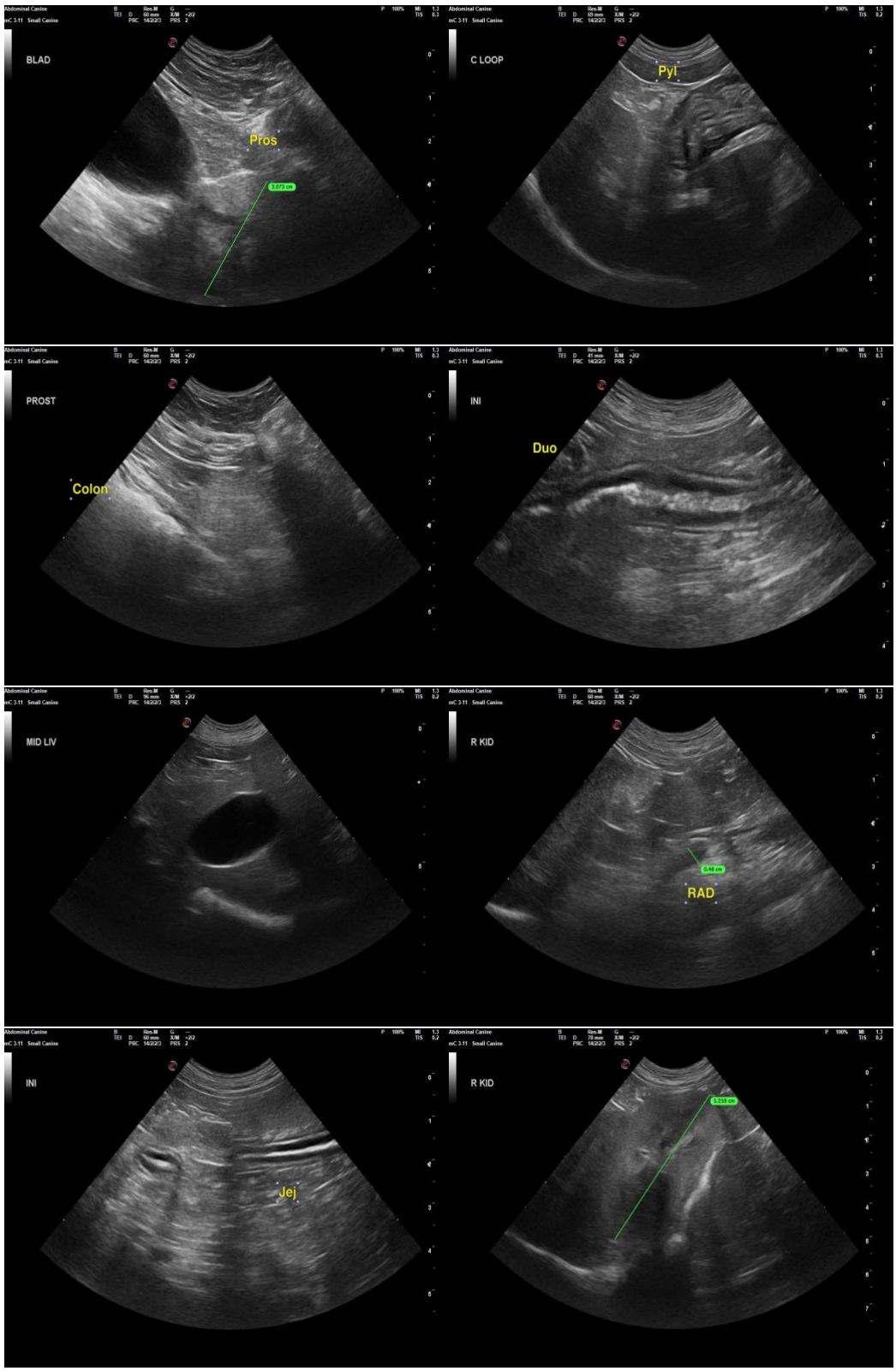

SonoPath
FOSTERING THE ART OF VETERINARY MEDICINE™

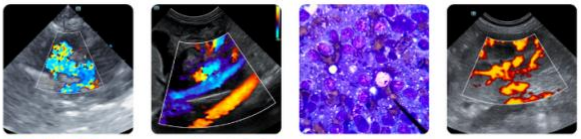

Clinical Sonography & Telecytology
Educational Teleconsultation Services™

SonoPath.com info@sonopath.com 1.800.838.4268

PATIENT

Prince Jem

SPECIES

Canine

BREED

Chihuahua Mix

SEX

Intact Male

AGE

13 Years 2 Months

WEIGHT

23.5 pounds

INTERPRETED BY

R. McKenzie Daniel, DVM, DABVP (Canine / Feline Practice)

IMAGING PERFORMED BY

Dr. Adrienne Hou

HOSPITAL NAME

Marina Village Veterinary & Integrative Care

REFERRING VET

Dr. Adrienne Hou

INVOICE

15322

DATE

04/21/26

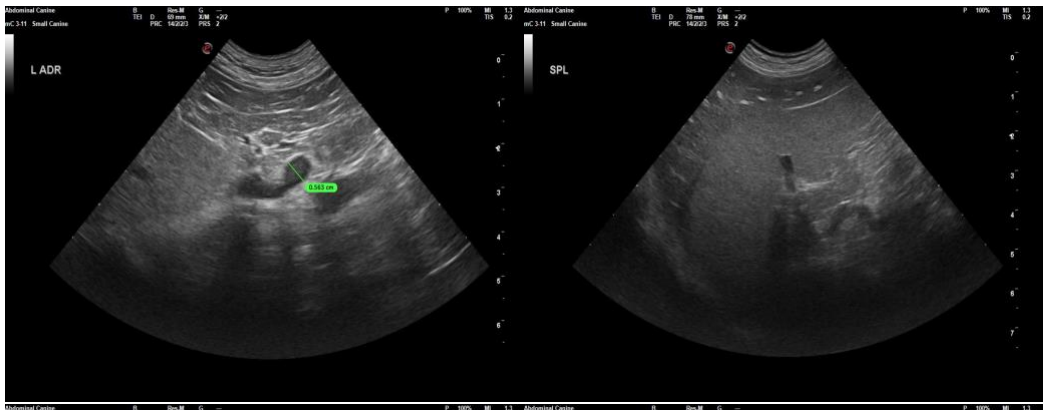

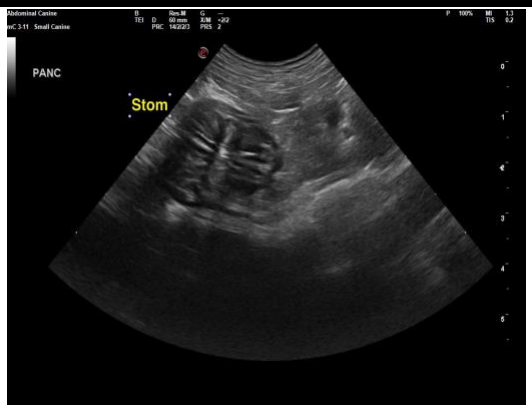

The information and recommendations provided are based on the images presented by the referring veterinarian/sonographer. No evaluation can be communicated regarding pathology that was not visible in the image/video clips provided.

Thank you for this referral. If the clinical or image interpretation does not parallel your findings or if I can be of any further assistance, please contact me.

R. McKenzie Daniel, DVM, DABVP (Canine / Feline Practice)

info@SonoPath.com