



## PATIENT

Cola Wong

## SPECIES

Canine

## BREED

Dachshund

## SEX

FS

## AGE

1yr

## WEIGHT

4.8kg

## INTERPRETED BY

R. McKenzie Daniel,  
DVM, DABVP  
(Canine and Feline)

## IMAGING PERFORMED BY

Dr Sarah Barthelemy

## HOSPITAL NAME

Woodlands Veterinary  
Hospital

## REFERRING VET

Dr Leboldus

## INVOICE

24550

## DATE

04/21/2026

## PRESENTING CLINICAL SIGNS

Recurrent vomiting with increased intensity and some blood over past couple weeks. Diet is now hypo for past month

## ULTRASONOGRAPHIC EXAMINATION OF THE ABDOMEN

### *Urinary System*

The urinary bladder, trigone, cystourethral junction, and visible pelvic urethra to a depth of 3 cm exhibited normal thickness and tone. Anechoic urine was present in the lumen with no evidence of urine/lumen sediment, mineral, or calculi. The ureteral papillae were normal. The ureters were not visible which is normal. No evidence of inflammatory or neoplastic changes was noted.

Normal size and margination were present in the kidneys. A normal 1:3 cortex / medulla ratio and normal corticomedullary definition were maintained. The echogenicity of the cortex was similar to or slightly less than normal liver parenchyma while the medulla echogenicity was hypoechoic to the cortex with no evidence of pelvic dilation. The left kidney measured 4.2 cm in length. The right kidney measured 4.3 cm in length.

The area of the aortic trifurcation was free of pathology.

### *Adrenal Glands*

The left adrenal gland was uniform in size and contour with a uniformly hypoechoic parenchyma. The left adrenal gland measured 0.42 cm width at the caudal pole. The right adrenal gland was uniform in size and contour with a uniformly hypoechoic parenchyma. The right adrenal gland measured 0.42 cm width at the caudal pole.

### *Spleen*

The spleen exhibited a finely textured and homogenous parenchyma which was hyperechoic to the liver and renal cortical parenchyma. The capsule was smooth and regular without apparent expansion. The splenic vasculature at the hilus was normal in volume with no evidence of congestion or thrombosis. Acute to chronic inflammatory, neoplastic, or benign parenchyma changes were not noted.

### *Liver/Gallbladder*

The liver was subjectively normal in size, structure, and contour. The liver parenchyma was uniform and hypoechoic to the spleen with a mild coarse echotexture. Normal vascular volume. The hepatic and portal vasculature were normal in appearance without signs of congestion. The gallbladder was non-distended in size with thin walls and primarily anechoic luminal content. The cystic and common bile ducts were normal.

### *Gastrointestinal*

The stomach presented subjective mild prominent, yet non-thickened wall. The stomach contained a mild amount of retained fluid with no evidence of obstruction to pyloric outflow. The gastric body wall measured 0.38 cm in width. The pylorus wall measured 0.40 cm in width.

The generalized small intestine presented intact subjective mild altered wall layer ratio owing to subjective propensity for mildly thickened intestinal mucosa and muscularis layers. No evidence of mechanical /metabolic ileus to the level of the colon. No evidence of pathology in the area of the



## PATIENT

Cola Wong

ileocolic junction. The duodenum wall measured 0.51 cm width. The jejunum wall measured 0.35 cm width.

Normal visible colon wall layers were present with apparent formed feces in lumen.

## SPECIES

Canine

### **Pancreas**

The parenchyma of the left limb, body and right limb of the pancreas presented isoechoic to the adjacent omental fat. A normal curvilinear capsule contour of the pancreas was present. The visible pancreatic duct was normal. No signs of active inflammation or neoplastic disease was evident.

## BREED

Dachshund

### **Free Abdomen**

No evidence of peritoneal effusion was present.

## SEX

FS

Intermittent mildly prominent elongated mesenteric lymph nodes were present. The lymph nodes were essentially isoechoic to adjacent omentum without evidence of peripheral inflammation and maintaining a normal width: length ratio (<0.5). An example measured 3.2 cm x 0.27 cm.

## ULTRASONOGRAPHIC FINDINGS

### AGE

1yr

### Primary

- Gastroenteropathy exhibiting minor retained gastric fluid and intact mildly thickened small intestinal wall- dietary intolerance/ hypersensitivity, non-specific inflammatory bowel, occult parasitism, occult Addison's disease or other
- Sonographically normal pancreas
- Formed fecal matter in colon

## WEIGHT

4.8kg

## INTERPRETED BY

R. McKenzie Daniel,  
DVM, DABVP  
(Canine and Feline)

## INTERPRETATION OF THE FINDINGS & FURTHER RECOMMENDATIONS

No evidence of mechanical gastrointestinal obstruction, foreign material or obstructive mural pathology such as intussusception. Continued dietary trial with as needed gastroprotectants omeprazole 1 mg/kg PO SID, and suggested empirical deworming even with negative fecal testing Panacur 50 mg/kg PO SID for 5 consecutive days may prove beneficial. Screening cortisol level to assess for occult Addison's disease is suggested. Upper gastrointestinal endoscopy with potential biopsies, pending additional diagnostics may be indicated if non-response to supportive care.

## IMAGING PERFORMED BY

Dr Sarah Barthelemy

## HOSPITAL NAME

Woodlands Veterinary  
Hospital

## REFERRING VET

Dr Leboldus

## INVOICE

24550

## DATE

04/21/2026



**PATIENT**

Cola Wong

**SPECIES**

Canine

**BREED**

Dachshund

**SEX**

FS

**AGE**

1yr

**WEIGHT**

4.8kg

**INTERPRETED BY**

R. McKenzie Daniel,  
DVM, DABVP  
(Canine and Feline)

**IMAGING PERFORMED BY**

Dr Sarah Barthelemy

**HOSPITAL NAME**

Woodlands Veterinary  
Hospital

**REFERRING VET**

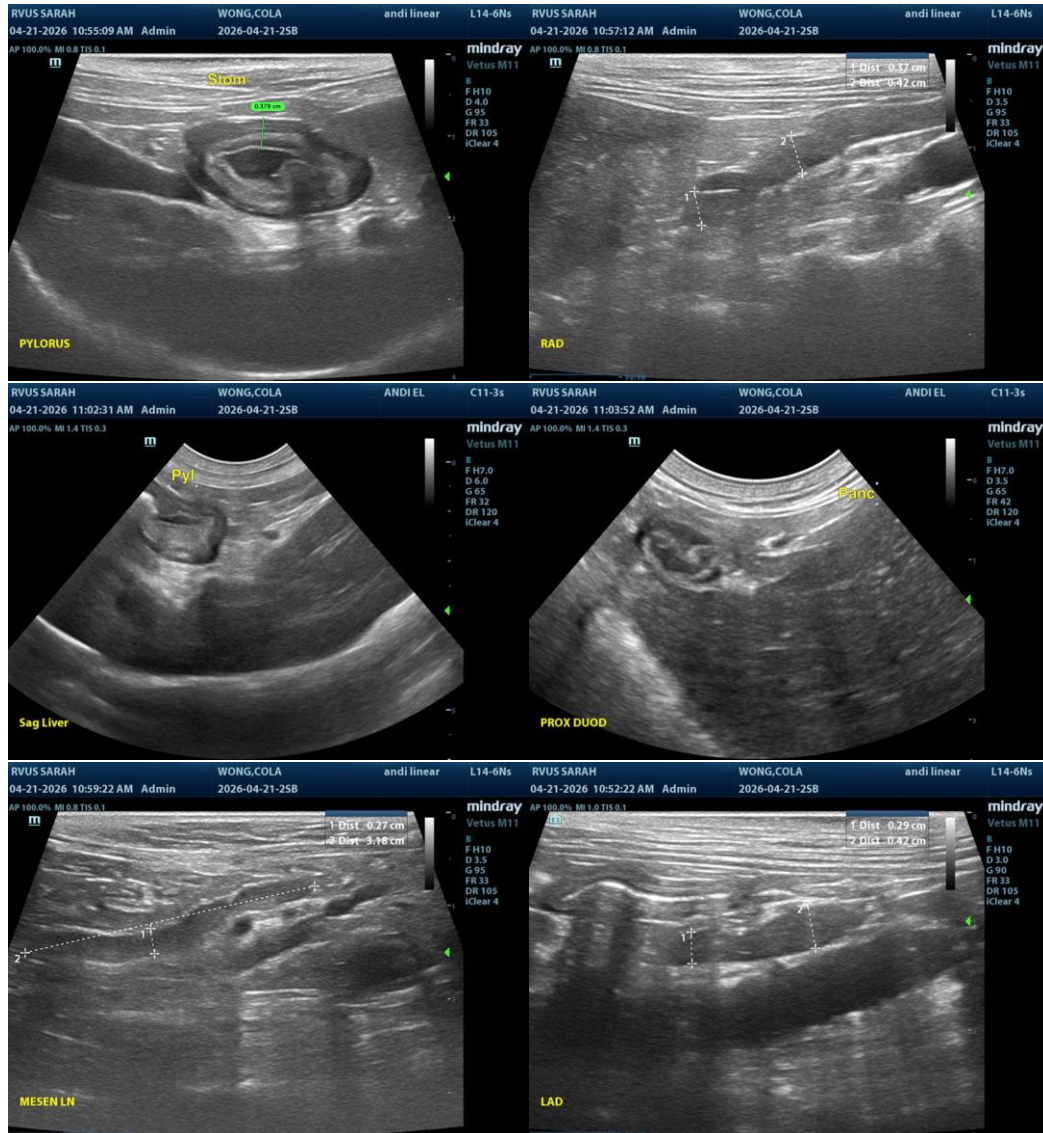
Dr Leboldus

**INVOICE**

24550

**DATE**

04/21/2026





**PATIENT**

Cola Wong

**SPECIES**

Canine

**BREED**

Dachshund

**SEX**

FS

**AGE**

1yr

**WEIGHT**

4.8kg

**INTERPRETED BY**

R. McKenzie Daniel,  
DVM, DABVP  
(Canine and Feline)

**IMAGING PERFORMED BY**

Dr Sarah Barthelemy

**HOSPITAL NAME**

Woodlands Veterinary  
Hospital

**REFERRING VET**

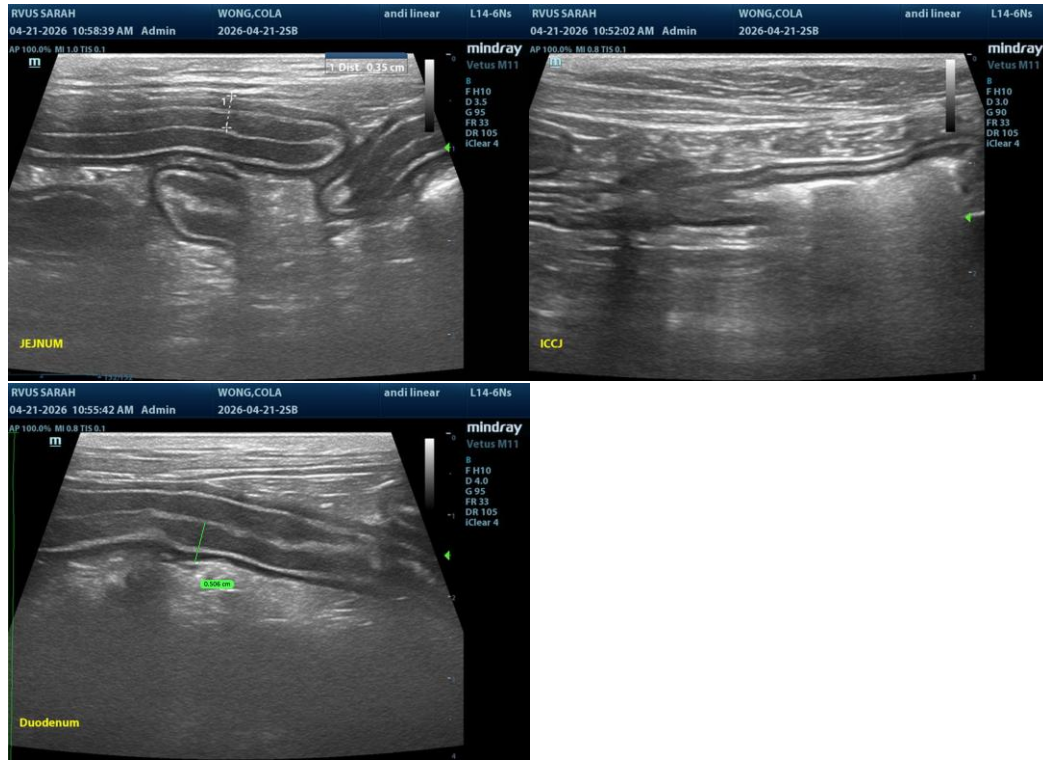
Dr Leboldus

**INVOICE**

24550

**DATE**

04/21/2026



The information and recommendations provided are based on the images presented by the referring veterinarian/sonographer. No evaluation can be communicated regarding pathology that was not visible in the image/video clips provided.

Thank you for this referral. If the clinical or image interpretation does not parallel your findings or if I can be of any further assistance, please contact me.

R. McKenzie Daniel, DVM, DABVP (Canine/Feline Practice)  
[info@sonopath.com](mailto:info@sonopath.com)