

PATIENT

Jack Ford

SPECIES

Canine

BREED

Lab Ret

SEX

MN

AGE

10

WEIGHT

40kg

INTERPRETED BY

R. McKenzie Daniel,
DVM, DABVP
(Canine and Feline)

IMAGING PERFORMED BY

Dr. Belan

HOSPITAL NAME

Alpine 24/7

REFERRING VET

Dr. Nelson

INVOICE

13543ag

DATE

04/21/2023

PRESENTING CLINICAL SIGNS

Had back issues 1 month prior on Onsier and gabapentin for pain control has been PU PD since even though now off meds. Back is now normal. On meds for suspect UTI Patient given butorphanol IV for scan

Abnormal PE/Chem/CBC/UA Results: Non diagnostic UA isosinuria SG 1006 ph 8 moderate glucose . 9 WBC HPF Moderate elevation of liver values

ULTRASONOGRAPHIC EXAMINATION OF THE ABDOMEN

Urinary System

The urinary bladder, trigone, cystourethral junction, and visible pelvic urethra to a depth of 4 cm exhibited normal thickness and tone. Anechoic urine was present in the lumen with no uroliths or sediment. The ureteral papillae were normal. The ureters were not visible which is normal. No evidence of inflammatory or neoplastic changes were noted.

Normal size and margination were present in the kidneys. A normal 1:3 cortex / medulla ratio and normal corticomedullary definition were maintained. The echogenicity of the cortex was similar to or slightly less than normal liver parenchyma while the medulla echogenicity was hypoechoic to the cortex with no evidence of pelvic dilation. The left kidney measured 6.2 cm in length. The right kidney measured 7.1 cm in length.

The area of the aortic trifurcation was free of pathology.

The area of the residual prostate appeared normal and free of pathology measuring 0.95 cm in diameter.

Adrenal Glands

The left adrenal gland was uniform in size and contour with a uniformly hypoechoic parenchyma. The left adrenal gland measured 0.52 cm width at the caudal pole and 0.39 cm width at the cranial pole. The right adrenal gland was uniform in size and contour with a uniformly hypoechoic parenchyma. The right adrenal gland measured 0.58 cm width at the caudal pole.

Spleen

The spleen exhibited normal size and primarily symmetrical capsule contour. Mild non-homogenous parenchyma exhibiting discrete hypoechoic nodules was present. The splenic vasculature at the hilus was normal in volume with no evidence of congestion or thrombosis. No masses noted.

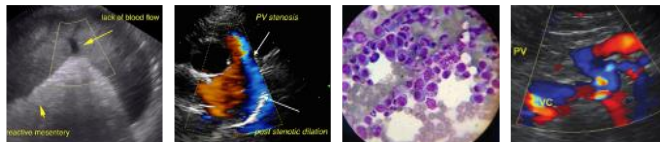
Liver/Gallbladder

The liver was subjectively normal in size, structure, and contour. The liver parenchyma was uniform and hypoechoic to the spleen with a mild coarse echotexture. The hepatic and portal vasculature were normal in appearance without signs of congestion. The gallbladder was non-distended in size with thin walls and primarily anechoic luminal content. The cystic and common bile ducts were normal.

Gastrointestinal

The stomach presented intact wall layering with a normal wall layer ratio. The lumen of the stomach was empty with no signs of ileus, obstruction or foreign material.

The small intestine presented intact wall layering with 1:3 muscularis/mucosa ratio. The lumen of the small intestine was empty with no signs of ileus, obstruction or foreign material.



PATIENT Normal visible colon wall layers were present with apparent formed feces in lumen.

Jack Ford **Pancreas**

SPECIES The parenchyma of the left limb, body and right limb of the pancreas presented isoechoic to the adjacent omental fat. A normal curvilinear capsule contour of the pancreas was present. The visible pancreatic duct was normal. No signs of active inflammation or neoplastic disease was evident.

Canine

Free Abdomen

BREED No omental masses, overt lymphadenopathy or peritoneal effusion was present.

Lab Ret

ULTRASONOGRAPHIC FINDINGS

SEX

- Sonographically normal kidneys/adrenal glands.
- Mild heterogenous discretely nodular spleen.
- Non-specific subjective benign hepatopathy.
- Sonographically normal gallbladder.

MN

AGE

INTERPRETATION OF THE FINDINGS & FURTHER RECOMMENDATIONS

10

A definitive cause of the reported PU/PD was not obvious given normal renal/adrenal/hepatic appearance. A urine C/S 7 days post completion of current medications for suspect UTI is suggested.

WEIGHT

The subtle splenic parenchyma changes are not suggestive of neoplastic criteria, considerations may include hyperplasia, hematopoiesis, or similar with neoplastic criteria considered unlikely. Sonographic monitoring of the spleen for progressive parenchyma changes +/- screening FNA cytology assuming normal clotting status and using a 25g needle would be reasonable.

40kg

INTERPRETED BY

Concurrent hepatic FNA cytology could be considered primarily to assess for evidence of inflammatory criteria. A leptospirosis titer/PCR may be considered if clinically indicated or if potential exposure/endemic to the area. Monitoring for persistent glucosuria may be indicated. Assessment for possible jerky treat administration and/or less likely idiopathic Fanconi syndrome may be considered.

R. McKenzie Daniel,
DVM, DABVP
(Canine and Feline)

IMAGING PERFORMED BY

Dr. Belan

HOSPITAL NAME

Alpine 24/7

REFERRING VET

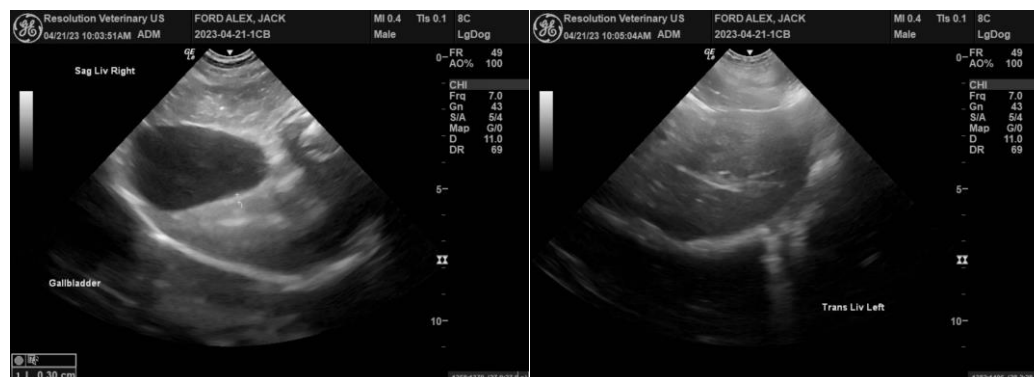
Dr. Nelson

INVOICE

13543ag

DATE

04/21/2023





PATIENT

Jack Ford

SPECIES

Canine

BREED

Lab Ret

SEX

MN

AGE

10

WEIGHT

40kg

INTERPRETED BY

R. McKenzie Daniel,
DVM, DABVP
(Canine and Feline)

IMAGING PERFORMED BY

Dr. Belan

HOSPITAL NAME

Alpine 24/7

REFERRING VET

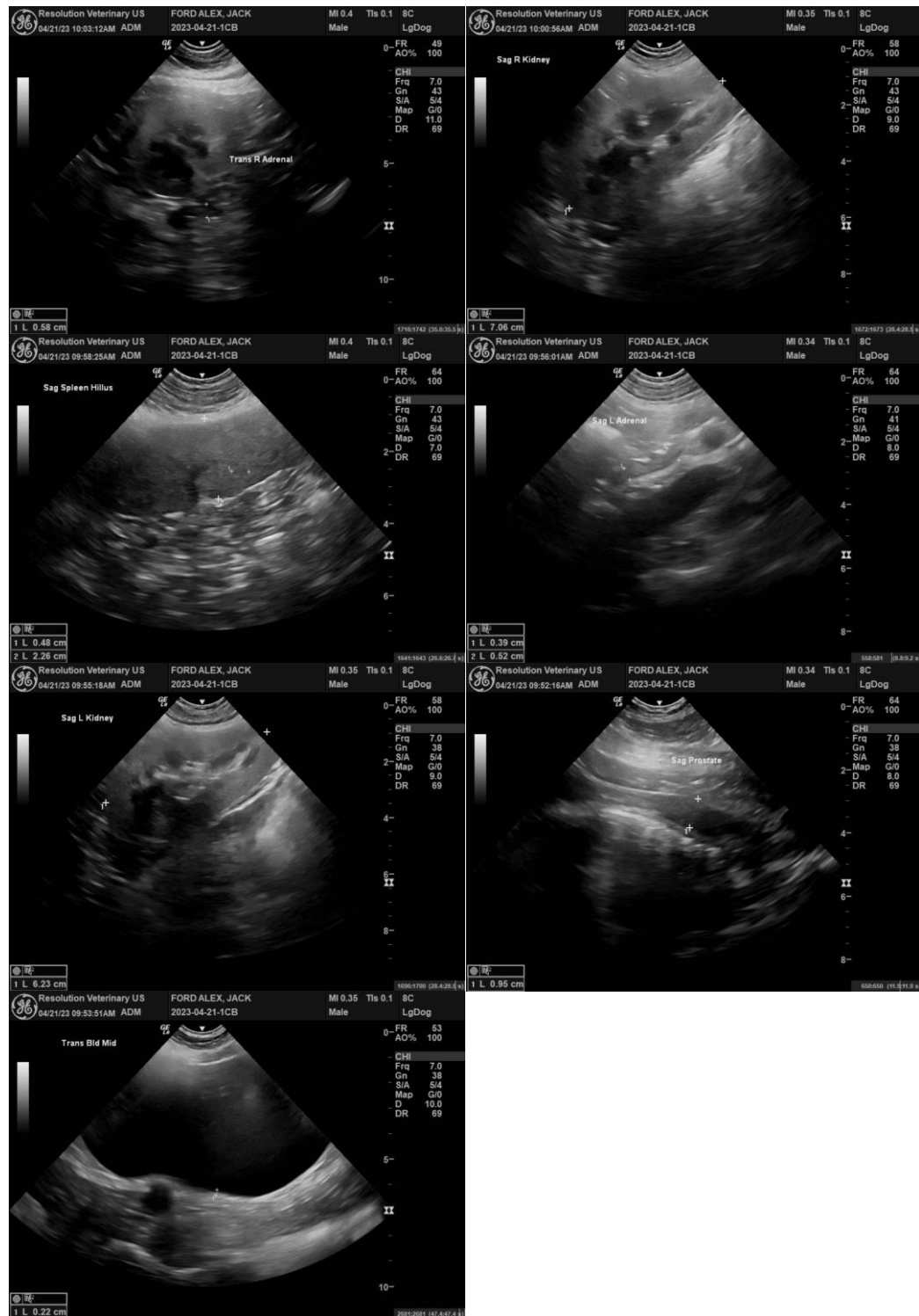
Dr. Nelson

INVOICE

13543ag

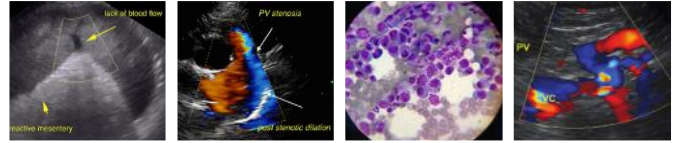
DATE

04/21/2023



The information and recommendations provided are based on the images presented by the referring veterinarian/sonographer. No evaluation can be communicated regarding pathology that was not visible in the image/video clips provided.

Thank you for this referral. If the clinical or image interpretation does not parallel your findings or if I



PATIENT

can be of any further assistance, please contact me.

Jack Ford

SPECIES

R. McKenzie Daniel, DVM, DABVP (Canine/Feline Practice)

mac.daniel@sonopath.com

Canine

BREED

Lab Ret

SEX

MN

AGE

10

WEIGHT

40kg

INTERPRETED BY

R. McKenzie Daniel,
DVM, DABVP
(Canine and Feline)

**IMAGING
PERFORMED BY**

Dr. Belan

HOSPITAL NAME

Alpine 24/7

REFERRING VET

Dr. Nelson

INVOICE

13543ag

DATE

04/21/2023