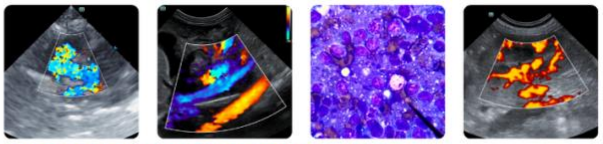

Clinical Sonography & Telecytology
Educational Teleconsultation Services™

PATIENT
Sophie Dee

SPECIES
Canine

BREED
Labrador Retriever

SEX
Spayed Female

AGE
13 Years

WEIGHT
54 lbs

INTERPRETED BY
R. McKenzie Daniel, DVM, DABVP (Canine / Feline Practice)

IMAGING PERFORMED BY
Jasmine Palacios

HOSPITAL NAME
River's Edge Pet Medical Center

REFERRING VET
Dr. Kellee Burns

INVOICE
15636

DATE
04/30/26

PRESENTING CLINICAL SIGNS

13 yr FS labrador with 1 month history of decreased appetite, PUPD, and pollakiuria pt has lost 6 lbs in 3 weeks. has experienced stringy mucoid vaginal discharge following urinations twice in the last month. Pt has 1 month history of frequent, small urinations; P cannot hold it through the night.. Pt has been on medications for urinary incontinence since 2023 per our records. Current Medications: proin BID. incurin SID. Carprofen. gabapentin SID in PM. Pepcid SID in am

Abnormal PE/Chem/CBC/UA Results: See attached labs: performed 3/24/26 urinalysis (free catch) USG 1.014 pyuria 500 leu/uL proteinuria 30mg/dL bld 250 ery/uL no bacteria detected crystalluria 1-5/HPF Bloodwork CBC decreased, HCT, HGB, MCB and MCH RBC 5.89 M/uL (5.65-8.87) lymphocytopenia 0.83 K/uL (1.05-5.10) MPV 14.0 fL (8.7-13.2) Chemistry -- no significant findings normal cpL, TT4

ULTRASONOGRAPHIC EXAMINATION OF THE ABDOMEN

Urinary System

The urinary bladder was normal in size and tone with mild irregular thickened ventroapical urinary bladder wall. Dependent to nondependent mild to moderate particulate urine sediment was present. No evidence of pathology in the area of the trigone or cystourethral junction. The urethra was normal in structure and tone to a depth of 3.0 cm. The thickened ventroapical wall measured 0.84 cm wall width. No evidence of mural mineralization. No obvious pathology in the area of the uterine remnant.

The area of the aortic trifurcation was free of pathology.

Normal size and margination was present in the kidneys. A normal 1:3 cortex / medulla ratio was maintained. The medulla and cortices were uniform in texture with some increased echogenicity and moderate loss of corticomedullary symmetry and definition expected for the age of the patient. No evidence of pelvic dilation was present. The left kidney measured 6.0 cm in length. The right kidney measured 6.0 cm in length.

Adrenal Glands

The left and right adrenal glands were not definitively visualized.

Spleen

A nonhomogenous mildly expansive mass involving the spleen with asymmetrical capsule expansion and disruption was present and measured at least 10.0 cm in diameter. No evidence of capsular escape or rupture. The parenchyma of the mass was heterogeneous to mixed echogenic without areas of cavitation. The non-affected spleen exhibited primarily finely textured and homogenous parenchyma which was hyperechoic to the liver and renal cortical parenchyma. The splenic vasculature at the hilus was normal in volume with no evidence of congestion or thrombosis.

Liver & Gallbladder

The liver presented mildly enlarged in size. The parenchyma of the liver was subjectively normal in echogenicity compared to the spleen and renal cortices. The liver parenchyma was uniform with a mildly coarse echotexture. The capsule of the liver was symmetrically rounded to mildly swollen in margination. The hepatic and portal vasculature were normal in appearance without signs of congestion.

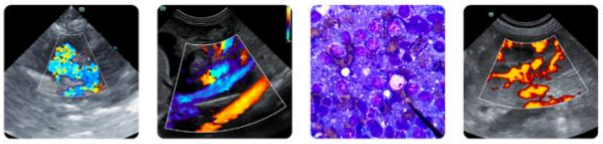

PATIENT
Sophie Dee

SPECIES
Canine

BREED
Labrador Retriever

SEX
Spayed Female

AGE
13 Years

WEIGHT
54 lbs

INTERPRETED BY
R. McKenzie Daniel, DVM, DABVP (Canine / Feline Practice)

IMAGING PERFORMED BY
Jasmine Palacios

HOSPITAL NAME
River's Edge Pet Medical Center

REFERRING VET
Dr. Kellee Burns

INVOICE
15636

DATE
04/30/26

The gallbladder was non distended in size with mild to moderate nonorganized biliary sludge. The cystic duct and common bile ducts were normal without evidence of dilation.

Gastrointestinal

The stomach presented intact wall layering with a normal wall layer ratio. The lumen of the stomach was empty with no signs of ileus, obstruction or foreign material.

The small intestine presented intact wall layering with 1:3 muscularis/mucosa ratio. The lumen of the small intestine was empty with no signs of ileus, obstruction or foreign material.

Normal visible colon wall layers were present with apparent formed feces in lumen.

Pancreas

The parenchyma of the left limb, body and right limb of the pancreas presented isoechoic to the adjacent omental fat. A normal curvilinear capsule contour of the pancreas was present. The visible pancreatic duct was normal. No signs of active inflammation or neoplastic disease was evident.

Free Abdomen

No overt lymphadenopathy or peritoneal effusion was present.

Rapid view of the heart revealed no overt cardiac tumors or pericardial effusion in the visible window.

ULTRASONOGRAPHIC FINDINGS

- Splenic mass.
- Mild hepatomegaly.
- Nonorganized gallbladder debris (non-mucocele).
- Sonographically normal gastrointestinal tract.
- Chronic renal changes.
- Mildly thickened ventral to ventroapical urinary bladder wall with dependent/nondependent urine sediment.

INTERPRETATION OF THE FINDINGS & FURTHER RECOMMENDATIONS

Although histopathology is required for definitive diagnosis, the splenic mass is most suggestive of neoplasia such as sarcoma or other. Benign pathologies are possible yet considered less likely. Obvious sonographic evidence of major organ or cardiac macrometastasis was not overtly evident with nonspecific mild hepatomegaly. Non sonographically evident metastasis / micro metastasis cannot be definitively excluded. Aside from the splenic mass, definitive cause of the patient's weight loss was not obvious. A GI panel to include PLI, TLI, cobalamin and folate and three view chest radiographs to assess for occult disease could be considered.

If no pathology on thoracic radiographs, splenectomy with gross inspection of the perisplenic omentum and abdominal cavity with consideration for screening hepatointestinal biopsies, if normal clotting status may be considered. Potential non-visualized adrenal pathology as a contributing factor is not excluded. Adrenal screening and workup could be considered if clinical suspicion of adrenal disease.

SonoPath

FOSTERING THE ART OF VETERINARY MEDICINE™

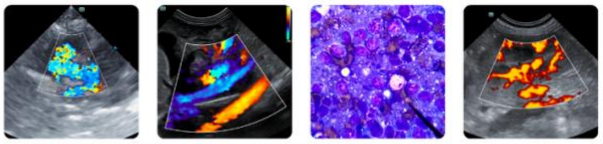

Clinical Sonography & Telecytology

Educational Teleconsultation Services™

SonoPath.com info@sonopath.com 1.800.838.4268

PATIENT

Sophie Dee

SPECIES

Canine

BREED

Labrador Retriever

SEX

Spayed Female

AGE

13 Years

WEIGHT

54 lbs

INTERPRETED BY

R. McKenzie Daniel, DVM, DABVP (Canine / Feline Practice)

IMAGING PERFORMED BY

Jasmine Palacios

HOSPITAL NAME

River's Edge Pet Medical Center

REFERRING VET

Dr. Kellee Burns

INVOICE

15636

DATE

04/30/26

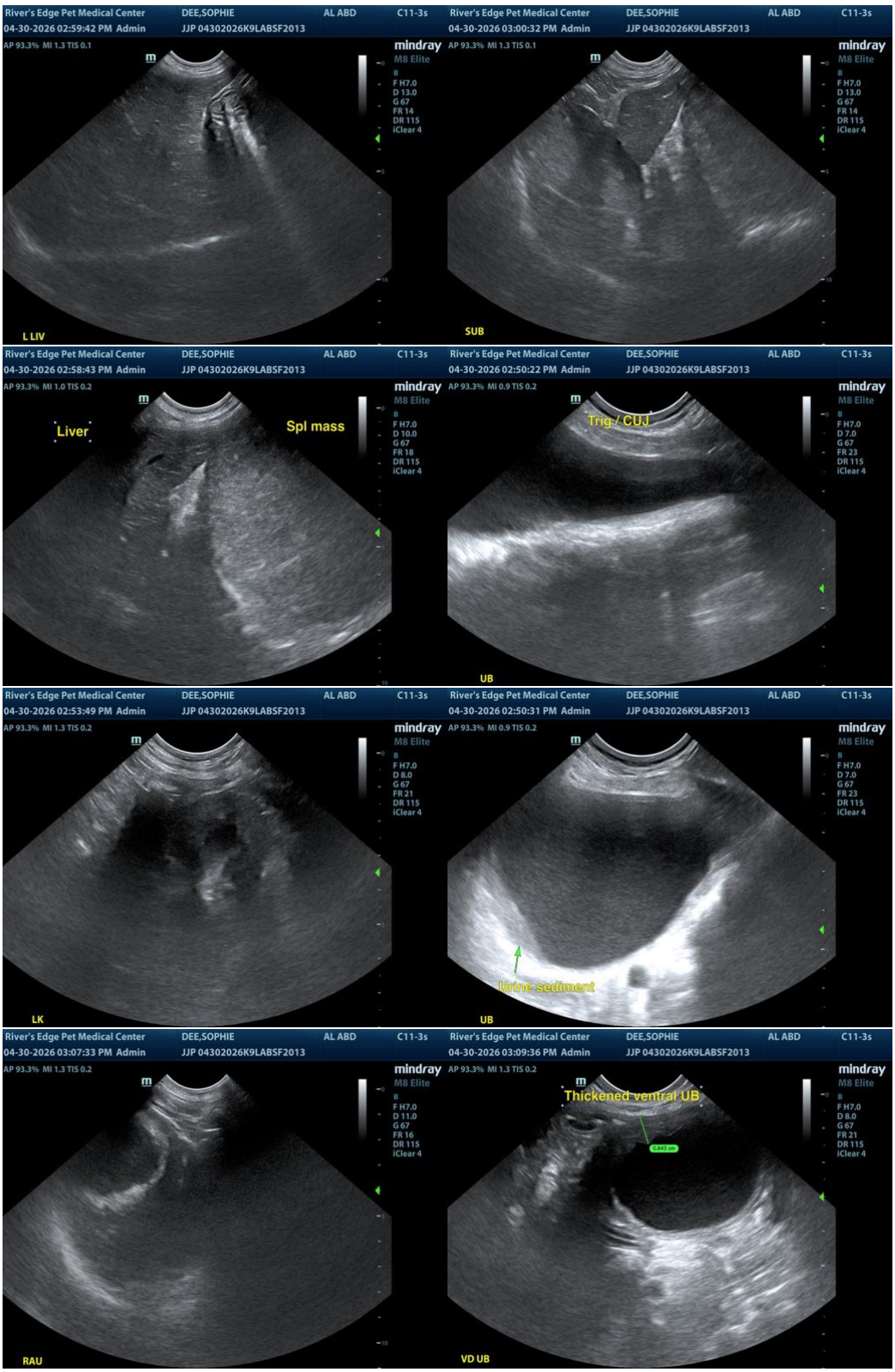

SonoPath
FOSTERING THE ART OF VETERINARY MEDICINE™

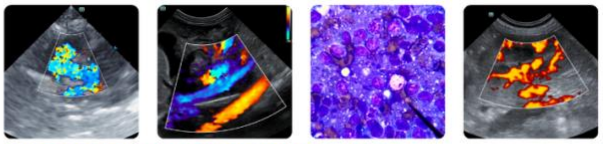

Clinical Sonography & Telecytology
Educational Teleconsultation Services™

SonoPath.com info@sonopath.com 1.800.838.4268

PATIENT

Sophie Dee

SPECIES

Canine

BREED

Labrador Retriever

SEX

Spayed Female

AGE

13 Years

WEIGHT

54 lbs

INTERPRETED BY

R. McKenzie Daniel, DVM, DABVP (Canine / Feline Practice)

IMAGING PERFORMED BY

Jasmine Palacios

HOSPITAL NAME

River's Edge Pet Medical Center

REFERRING VET

Dr. Kellee Burns

INVOICE

15636

DATE

04/30/26

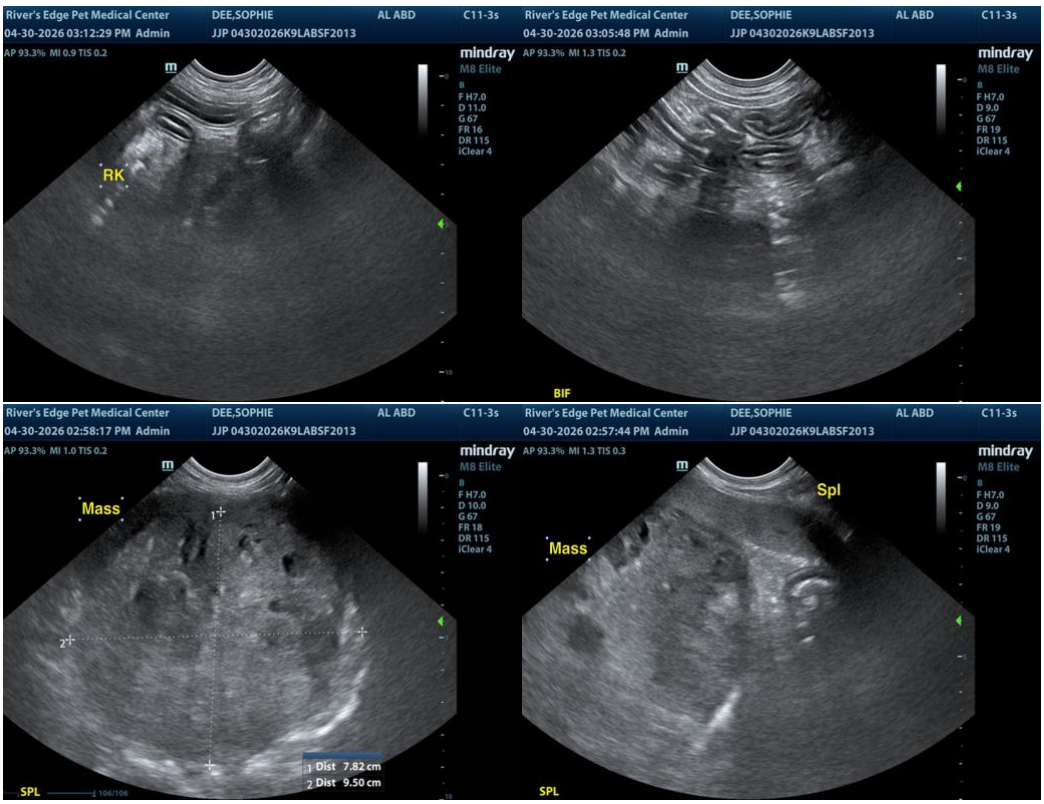

The information and recommendations provided are based on the images presented by the referring veterinarian/sonographer. No evaluation can be communicated regarding pathology that was not visible in the image/video clips provided.

Thank you for this referral. If the clinical or image interpretation does not parallel your findings or if I can be of any further assistance, please contact me.

R. McKenzie Daniel, DVM, DABVP (Canine / Feline Practice)

info@SonoPath.com