



## PATIENT

Pippa Hickenbottom

## SPECIES

Canine

## BREED

Cavalier King Charles Spaniel

## SEX

FS

## AGE

8 years

## WEIGHT

17.8 lbs.

## INTERPRETED BY

R. McKenzie Daniel,  
DVM, DABVP  
(Canine and Feline)

## IMAGING PERFORMED BY

Diane McFadden

## HOSPITAL NAME

Animal Hospital of  
Roxbury

## REFERRING VET

Dr. Elia

## INVOICE

13687

## DATE

4/20/22

## PRESENTING CLINICAL SIGNS

murmur 3/6, asymptomatic; screening today. On incuran.

Abnormal PE/Chem/CBC/UA Results: PSL 187, pro BNP wnl 425; UA: dark yellow, pH 9, amorphous phosphate 21-50; USPG 1.027

## ULTRASONOGRAPHIC EXAMINATION OF THE HEART & ABDOMEN

CANINE	MR	TR	LA/AO	LA/AO	FS	EF	EPSS
<b>CARDIAC PARAMETERS</b>	<b>VMAX</b> (m/s)	<b>VMAX</b> (m/s)	(Boon method)	(Heart Base; Swe)	(%)	(%)	(cm)
<b>NORMAL PARAMETER</b>	4.5-5.5	<2.7	1.3	<1.3	28-40	40-100	<0.6
<b>PATIENT</b>	5.2	2.4		1.3	47	80.2	0.19
CANINE	HR	AV	PV	BODY WEIGHT	LA	LVIDd	LVIDs
<b>CARDIAC PARAMETERS</b>	(BPM)	<b>VMAX</b> (m/s)	<b>MAX</b> (m/s)	(kg)	2D short axis Base view (cm)	Avg; 2D and m-mode short axis (cm)	Avg; 2D and m-mode short axis (cm)
<b>NORMAL PARAMETER</b>	50-100	0.7-1.7	0.7-1.6				
<b>PATIENT</b>	159	1.4	0.9		3.3	2.7	

## Cardiac Presentation

The echocardiogram in this patient demonstrated normal **left atrial** size based on 3 different LA measurement methods. Chamber volumes and echogenicity were normal. The cranial and caudal **mitral** valve leaflets presented vegetative thickening consistent with endocardiosis. Doppler indicated eccentric mitral valve insufficiency. No evidence of mitral valve prolapse or chordae tendineae rupture was noted. The **left ventricle** presented thicknesses with linear contour and was not dilated nor restricted. The **myocardium** presented normal echogenicity without subjective evidence of significant fibrotic or ischemic disease. **Contractility** of the ventricular walls was adequate and in normal range for this patient evidenced by the fractional shortening measurement and subjective evaluation of the different regions of the myocardium. The **left ventricular outflow** tract demonstrated normal laminar flow and subjective structural integrity. The **right atrium** and auricle revealed normal size, structure and content. No evidence of masses was noted or chamber overload. **Tricuspid** valvular assessment demonstrated mild thickening with mild TR on doppler. The **right ventricle** was of normal size (1/3 diameter of LV), chordae structure, myocardial echogenicity and thickness. **Pulmonic** tract assessment revealed normal valve structure, laminar flow, and diameter (approx.1:1 pa/ao ratio). No visible **pericardial** or free pleura fluid was noted. No echographically detectable evidence of infiltrative disease was visible. The cranial **mediastinum and pericardial regions** were free of masses in the visible window.



**PATIENT**

Pippa Hickenbottom

**SPECIES**

Canine

**BREED**

Cavalier King Charles  
Spaniel

**SEX**

FS

**AGE**

8 years

**WEIGHT**

17.8 lbs.

**INTERPRETED BY**

R. McKenzie Daniel,  
DVM, DABVP  
(Canine and Feline)

**IMAGING  
PERFORMED BY**

Diane McFadden

**HOSPITAL NAME**

Animal Hospital of  
Roxbury

**REFERRING VET**

Dr. Elia

**INVOICE**

13687

**DATE**

4/20/22

**Urinary System**

The urinary bladder, trigone, and cystourethral junction exhibited normal thickness and tone. Primarily anechoic urine was present in the lumen with mild, nondependent, particulate sediment without evidence of calculus formation. The ureteral papillae were normal. The ureters were not visible which is normal. No evidence of inflammatory or neoplastic mural changes were noted. The visible urethra exhibited normal structure and tone to a depth of 3.0 cm.

The area of the aortic trifurcation was free of pathology.

Normal size and margination were present in the kidneys. A normal 1:3 cortex / medulla ratio and normal corticomedullary definition were maintained. The echogenicity of the cortex was similar to or slightly less than normal liver parenchyma while the medulla echogenicity was hypoechoic to the cortex with no evidence of pelvic dilation. The left kidney measured 5.0 cm in length. The right kidney measured 5.4 cm in length.

**Adrenal Glands**

The left adrenal gland was uniform in size and contour with a uniformly hypoechoic parenchyma. The left adrenal gland measured 2.4 cm length x 0.54 cm width at the caudal pole. The right adrenal gland was uniform in size and contour with a uniformly hypoechoic parenchyma. The right adrenal gland measured 2.7 cm length x 0.38 cm width at the caudal pole.

**Spleen**

The spleen exhibited a finely textured and homogenous parenchyma which was hyperechoic to the liver and renal cortical parenchyma. The capsule was smooth and regular without apparent expansion. The splenic vasculature at the hilus was normal in volume with no evidence of congestion or thrombosis. Acute to chronic inflammatory, neoplastic, or benign parenchyma changes were not noted.

**Liver/ Gallbladder**

The liver was subjectively normal in size, structure, and contour. The liver parenchyma was uniform and hypoechoic to the spleen with a mild coarse echotexture. The hepatic and portal vasculature were normal in appearance without signs of congestion. The gallbladder was non-distended in size with thin walls and primarily anechoic luminal content. The cystic and common bile ducts were normal.

**Gastrointestinal**

The stomach presented intact wall layering with a normal wall layer ratio. The lumen of the stomach contained moderate nonshadowing ingesta likely consistent with post prandial presentation without signs of ileus, obstruction or foreign material. The stomach was otherwise normal.

The small intestine presented intact wall layering with 1:3 muscularis/mucosa ratio. The lumen of the small intestine was empty with no signs of ileus, obstruction, or foreign material.

Normal visible colon wall layers were present with apparent formed feces in lumen.



**PATIENT**

Pippa Hickenbottom

**SPECIES**

Canine

**BREED**

Cavalier King Charles Spaniel

**SEX**

FS

**AGE**

8 years

**WEIGHT**

17.8 lbs.

**INTERPRETED BY**

R. McKenzie Daniel, DVM, DABVP  
(Canine and Feline)

**IMAGING PERFORMED BY**

Diane McFadden

**HOSPITAL NAME**

Animal Hospital of Roxbury

**REFERRING VET**

Dr. Elia

**INVOICE**

13687

**DATE**

4/20/22

**Pancreas**

The parenchyma of the left limb, body, and right limb of the pancreas presented isoechoic to the adjacent omental fat. A normal curvilinear capsule contour of the pancreas was present. The visible pancreatic duct was normal. No signs of active inflammation or neoplastic disease were evident.

**Free Abdomen**

No overt lymphadenopathy or peritoneal effusion was present.

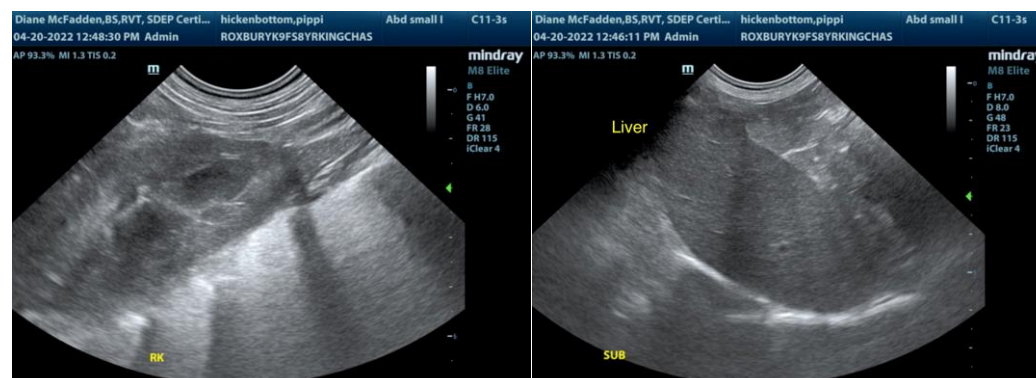
**ULTRASONOGRAPHIC FINDINGS**

- Chronic mitral valve disease (ACVIM B1)
- TR - estimated pulmonary pressure gradient not consistent with clinical pulmonary hypertension
- Sonographically unremarkable urinary bladder and visible proximal urethra with mild urinary bladder sediment

**INTERPRETATION OF THE FINDINGS & FURTHER RECOMMENDATIONS**

The cause of the murmur is chronic degenerative valvular changes with secondary eccentric mitral valve insufficiency. The lack of left atrial enlargement implies that the risk of complication secondary to mitral valve insufficiency is low at this time and, without current clinical signs, indicates that medical therapy is not required. However, prognosis is highly variable, and serial sonographic monitoring is required for further prognosis. Conservative monitoring is recommended with a recheck echocardiogram in 6-12 months, sooner if clinical signs suggestive of heart disease develop.

The mild urinary bladder sediment is suggestive of mild cellular debris / protein, or crystalline debris, given the amorphous phosphate crystals. Urine culture and sensitivity could be considered, given the increased PH or if evidence of inflammatory cells.





**PATIENT**

Pippa Hickenbottom

**SPECIES**

Canine

**BREED**

Cavalier King Charles Spaniel

**SEX**

FS

**AGE**

8 years

**WEIGHT**

17.8 lbs.

**INTERPRETED BY**

R. McKenzie Daniel,  
DVM, DABVP  
(Canine and Feline)

**IMAGING PERFORMED BY**

Diane McFadden

**HOSPITAL NAME**

Animal Hospital of  
Roxbury

**REFERRING VET**

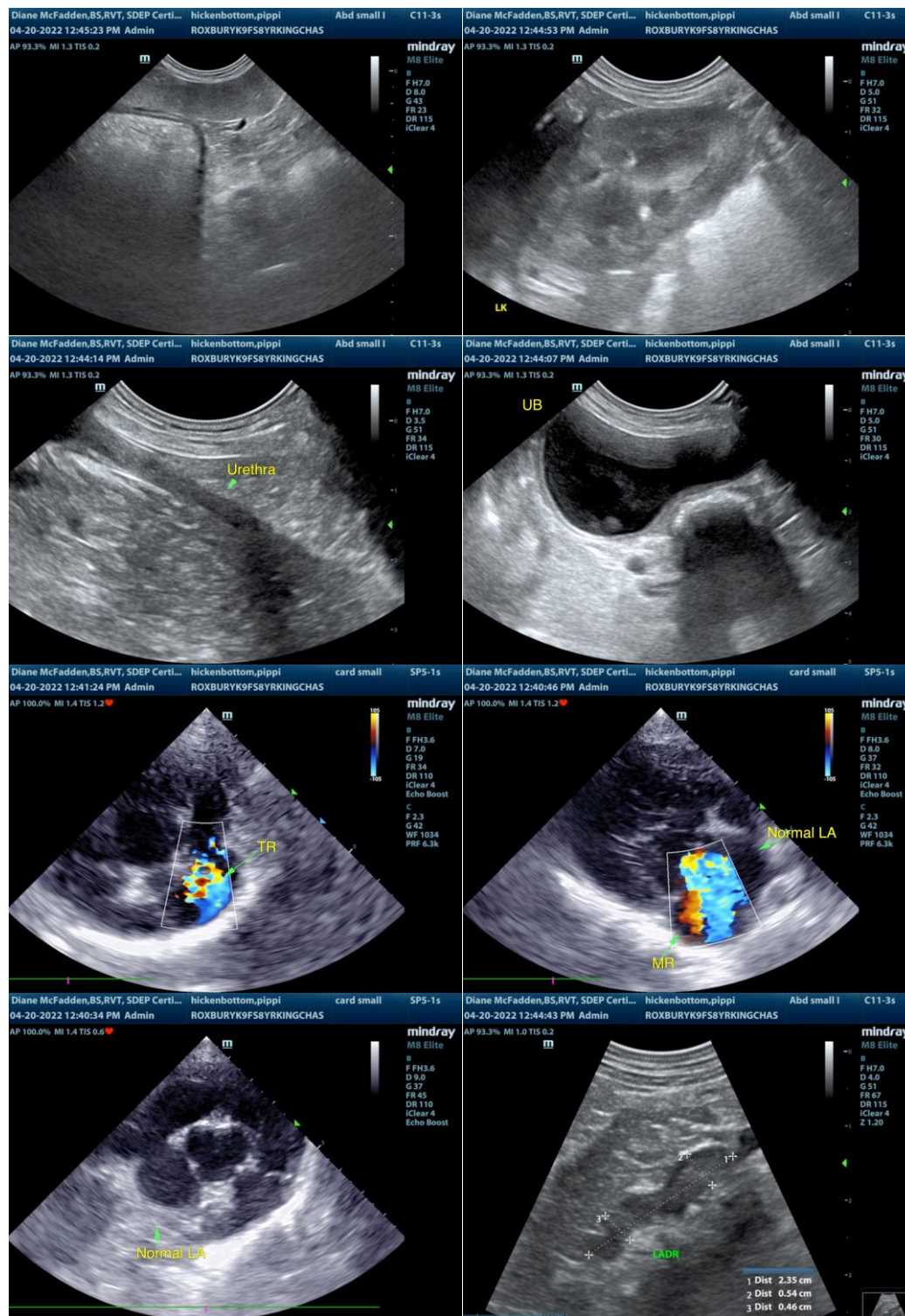
Dr. Elia

**INVOICE**

13687

**DATE**

4/20/22





**PATIENT**

Pippa Hickenbottom

**SPECIES**

Canine

**BREED**

Cavalier King Charles  
Spaniel

**SEX**

FS

**AGE**

8 years

**WEIGHT**

17.8 lbs.

**INTERPRETED BY**

R. McKenzie Daniel,  
DVM, DABVP  
(Canine and Feline)

**IMAGING  
PERFORMED BY**

Diane McFadden

**HOSPITAL NAME**

Animal Hospital of  
Roxbury

**REFERRING VET**

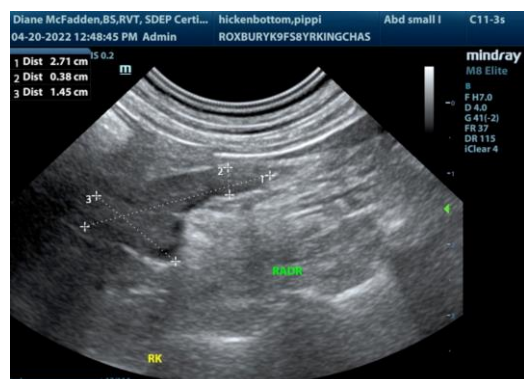
Dr. Elia

**INVOICE**

13687

**DATE**

4/20/22



The information and recommendations provided are based on the images presented by the referring veterinarian/sonographer. No evaluation can be communicated regarding pathology that was not visible in the image/video clips provided.

Thank you for this referral. If the clinical or image interpretation does not parallel your findings or if I can be of any further assistance please contact me.

**R. McKenzie Daniel, DVM, DABVP (Canine / Feline Practice)**  
info@SonoPath.com