

PATIENT

Katy Garber

SPECIES

Feline

BREED

Siamese

SEX

FS

AGE

13.5 yrs

WEIGHT

4.9 kg

INTERPRETED BY

R. McKenzie Daniel,
 DVM, DABVP
 (Canine and Feline)

IMAGING PERFORMED BY

Crystal Hill

HOSPITAL NAME

Vet For Life AH

REFERRING VET

Dr. Bajaj

INVOICE

10756

DATE

4/2/26

PRESENTING CLINICAL SIGNS

History:

- Annual wellness exam revealed heart murmur grade 3/6. Clinically patient is doing well. No meds

Abnormal PE/Chem/CBC/UA Results: Rads to radiologist Nov 2025 reported normal thorax

ULTRASONOGRAPHIC EXAMINATION OF THE HEART

FELINE CARDIAC PARAMETERS	BODY WEIGHT	HR (BPM)	IVSd (cm)	LVIDd (cm)	LVWd (cm)	FS (%)	EF (%)
NORMAL PARAMETER	-----	150-240	0.3-0.6	1.0-2.1	0.25-0.6	35-67	80-100
PATIENT	4.9 kg	180	0.51	1.4	0.48	48	84
FELINE CARDIAC PARAMETERS	LA/AO (M-mode)	LA/AO HEART BASE (Sisson)	LAD LA MAX 4 Chamber		LVOT VEL. (m/s)	RVOT VEL. (m/s)	IVRT (m/)
NORMAL PARAMETER	<1.5	1.6	0.7-1.7		<1.6	<1.3	40-60
PATIENT	-	1.45	1.4		1.0	1.35	-

Adapted from June Boon, Veterinary Echocardiography, 1998
 Sisson D et al. JVIM 1991; 5: 232, Jacobs et al. Am J Vet Res 1985; 46:1705

Cardiac Presentation

The echocardiogram in this patient demonstrated normal **left atrial** size and structure. The cranial and caudal **mitral** valve leaflets presented minor irregular age-related changes that are not clinically significant at this time with adequate extension in systole and union in diastole. Minor MR was noted on Doppler. The **left ventricle** presented normal free wall and septal thicknesses with linear contour. The **myocardium** presented some echogenic remodeling consistent with expected age-related change. **Contractility** of the ventricular walls was adequate and in normal range for this breed and patient size. The **left ventricular outflow** tract demonstrated normal laminar flow with subjectively unremarkable structure. Subjective assessment of the **right atrium** and auricle revealed normal size, structure and content. No evidence of masses was noted. **Tricuspid** valvular assessment demonstrated expected findings for this age patient. The **right ventricle** was of normal size (1/3 diameter of LV), echogenicity and thickness. **Pulmonic** tract assessment revealed normal valve structure, laminar flow, and diameter (approx. 1:1 pa/ao ratio). Normal measured RVOT velocity was noted. No visible **pericardial** or free pleural fluid was noted. The **mediastinum** was free of masses in the visible window.



PATIENT

Katy Garber

SPECIES

Feline

BREED

Siamese

SEX

FS

AGE

13.5 yrs

WEIGHT

4.9 kg

INTERPRETED BY

R. McKenzie Daniel,
 DVM, DABVP
 (Canine and Feline)

IMAGING PERFORMED BY

Crystal Hill

HOSPITAL NAME

Vet For Life AH

REFERRING VET

Dr. Bajaj

INVOICE

10756

DATE

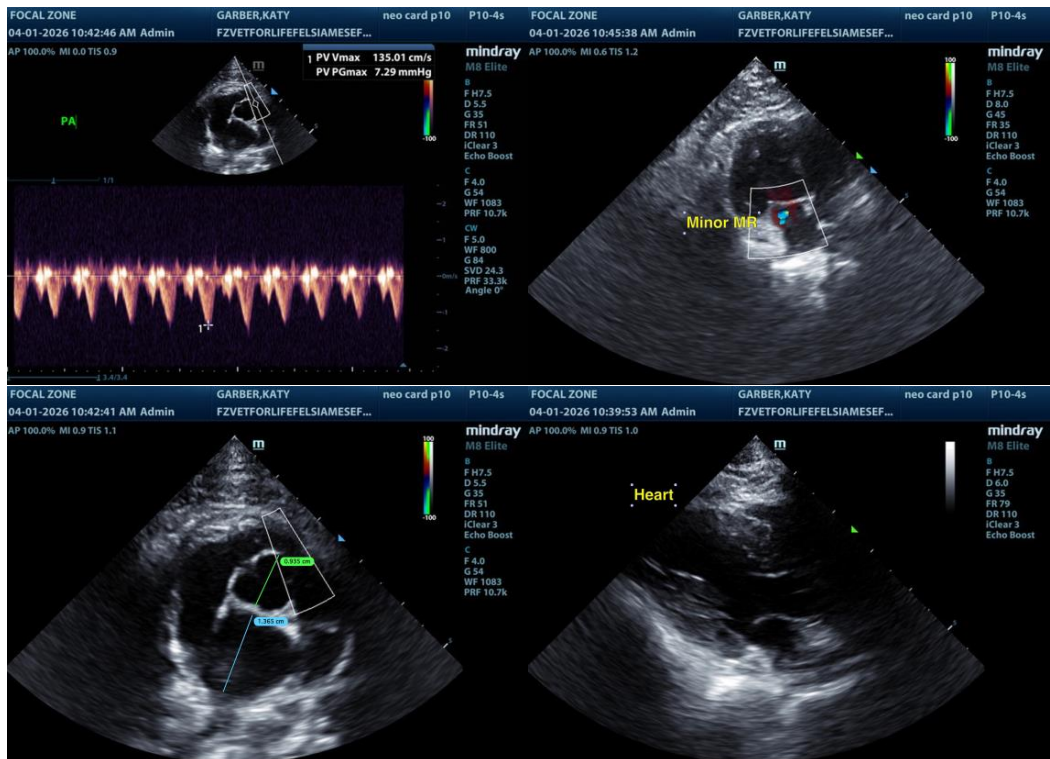
4/2/26

ULTRASONOGRAPHIC FINDINGS

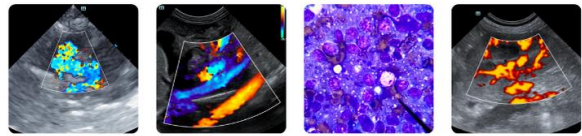
- Overall normal cardiac structure / function with mild myocardial remodeling
- Minor mitral valve insufficiency

INTERPRETATION OF THE FINDINGS & FURTHER RECOMMENDATIONS

There is no evidence of HCM or other structural cardiomyopathy. The minor MR is not suspected to be audible, indicating a likely flow murmur. Regardless of classification, the hemodynamic effects of the murmur are low. There is no indication for cardiac medications. Conservative monitoring is indicated. Recheck echocardiogram is suggested in 6-12 months, sooner if increased murmur intensity or if clinical signs arise. Cardiac anesthetic risk is considered mild. If required, the following protocol is suggested. Suggested anesthetic protocol may include opioid or Benzodiazepine pre-med, induction with Propofol or Alfaxalone, and appropriate gas anesthesia with avoidance of alpha 2 agonists.



The information and recommendations provided are based on the images presented by the referring veterinarian/sonographer. No evaluation can be communicated regarding pathology that was not visible in the image/video clips provided.



PATIENT

Katy Garber

Thank you for this referral. If the clinical or image interpretation does not parallel your findings or if I can be of any further assistance, please contact me.

SPECIES

Feline

R. McKenzie Daniel, DVM, DABVP (Canine/Feline Practice)
info@sonopath.com

BREED

Siamese

SEX

FS

AGE

13.5 yrs

WEIGHT

4.9 kg

INTERPRETED BY

R. McKenzie Daniel,
DVM, DABVP
(Canine and Feline)

**IMAGING
PERFORMED BY**

Crystal Hill

HOSPITAL NAME

Vet For Life AH

REFERRING VET

Dr. Bajaj

INVOICE

10756

DATE

4/2/26