



PATIENT

Watson Ng

SPECIES

Canine

BREED

Cane Corso

SEX

MN

AGE

9 years

WEIGHT

130 lbs.

INTERPRETED BY

R. McKenzie Daniel,
DVM, DABVP
(Canine and Feline)

IMAGING PERFORMED BY

Kelly Vazquez

HOSPITAL NAME

Animal General on
Hudson

REFERRING VET

Dr. Vivian Ng

INVOICE

16650

DATE

4/19/23

PRESENTING CLINICAL SIGNS

Follow up of lymph node in the area of the prostate (previously FNA'd: reactive lymphoid neoplasia). History of splenic nodules 12/1/21. No current meds.

Abnormal PE/Chem/CBC/UA Results: CBC/Chem: WNL.

ULTRASONOGRAPHIC EXAMINATION OF THE ABDOMEN

Urinary System

The urinary bladder was normal in size and tone exhibiting overtly normal urinary bladder walls containing anechoic urine with mild dependent, hyperechoic sand and micromineral.

The residual prostate was mildly enlarged with an asymmetrical yet intact prostatic capsule. Nonhomogeneous, hypoechoic cystic pinpoint mineralized residual prostate parenchyma was noted. The residual prostate measured 4.3 cm x 3.5 cm.

No evidence of medial Iliac or sublumbar lymphadenopathy/masses.

Normal size and margination were present in the right kidney. A normal 1:3 cortex / medulla ratio was maintained. The medulla and cortices were uniform in texture with some increased echogenicity and mild loss of corticomedullary symmetry and definition expected for the age of the patient. No evidence of pelvic dilation was present. The right kidney measured 7.4 cm in length. No overt pathology was noted in the area of the left kidney.

Adrenal Glands

The left adrenal gland was uniform in size and contour with a uniformly hypoechoic parenchyma. The left adrenal gland measured 2.1 cm length x 0.43 cm width at the caudal pole. The right adrenal gland was uniform in size and contour with a uniformly hypoechoic parenchyma. The right adrenal gland measured 2.8 cm length x 0.48 cm width at the caudal pole.

Spleen

The spleen exhibited primarily finely textured parenchyma which was hyperechoic to the liver and renal cortical parenchyma. Mild generalized parenchyma heterogeneity was present without evidence of nodular changes. The capsule was smooth and regular without apparent expansion. The splenic vasculature at the hilus was normal in volume with no evidence of congestion or thrombosis. The parenchymal heterogeneity is likely consistent with benign changes such as extramedullary hematopoiesis or age-related remodeling with minor potential for inflammatory or neoplastic disease.

Liver/ Gallbladder

The liver was subjectively normal in size, structure, and contour. The liver parenchyma was mildly nonuniform and hypoechoic to the spleen with a moderate coarse echotexture and subjective mild parenchymal remodeling. The hepatic and portal vasculature were normal in appearance without signs of congestion. The gallbladder was non-distended in size containing primarily anechoic content with minor echogenic gallbladder debris. No evidence of inflammatory criteria was noted. The cystic and common bile ducts were normal.



PATIENT

Gastrointestinal

Watson Ng

The stomach presented intact generalized mild prominent to thickened gastric walls with the ventral gastric body wall width measuring up to 1.0 cm. The lumen of the stomach was empty with mild luminal gas.

SPECIES

Canine

The small intestine presented intact wall layering with 1:3 muscularis/mucosa ratio. The lumen of the small intestine was empty with no signs of ileus, obstruction, or foreign material.

BREED

Cane Corso

Normal visible colon wall layers were present with apparent formed feces in lumen.

SEX

Pancreas

MN

The parenchyma of the left limb, body, and right limb of the pancreas presented isoechoic to the adjacent omental fat. A normal curvilinear capsule contour of the pancreas was present. The visible pancreatic duct was normal. No signs of active inflammation or neoplastic disease were evident.

AGE

9 years

Free Abdomen

No overt lymphadenopathy or peritoneal effusion was present.

WEIGHT

130 lbs.

ULTRASONOGRAPHIC FINDINGS

INTERPRETED BY

R. McKenzie Daniel,
DVM, DABVP
(Canine and Feline)

- Mild dependent urinary bladder sand / mineral
- Mild residual prostatomegaly exhibiting nonhomogeneous cystic to pinpoint mineralized parenchyma
- Right kidney mild chronic renal changes
- Heterogeneous spleen - benign
- Mild hepatic parenchymal remodeling with minor gallbladder debris (non-mucocele)

IMAGING PERFORMED BY

Kelly Vazquez

INTERPRETATION OF THE FINDINGS & FURTHER RECOMMENDATIONS

HOSPITAL NAME

Animal General on
Hudson

Although pending sampling is required for further assessment, primary concern for residual prostate neoplastic criteria is warranted. Given the evidence of parenchymal mineralization, prostatic or urothelial carcinoma is suspected with chronic residual prostatitis possible yet thought less likely.

REFERRING VET

Dr. Vivian Ng

Correlation with pending cytology is suggested. Biopsy may be required for a definitive diagnosis. No overt evidence of regional metastasis, if residual prostate neoplastic criteria is confirmed. Concurrent urinalysis +/- C/S, if evidence of inflammatory sediment, is suggested. No evidence of progressive splenic parenchyma changes or splenic neoplasia criteria.

INVOICE

16650

DATE

4/19/23



PATIENT

Watson Ng

SPECIES

Canine

BREED

Cane Corso

SEX

MN

AGE

9 years

WEIGHT

130 lbs.

INTERPRETED BY

R. McKenzie Daniel,
DVM, DABVP
(Canine and Feline)

IMAGING PERFORMED BY

Kelly Vazquez

HOSPITAL NAME

Animal General on
Hudson

REFERRING VET

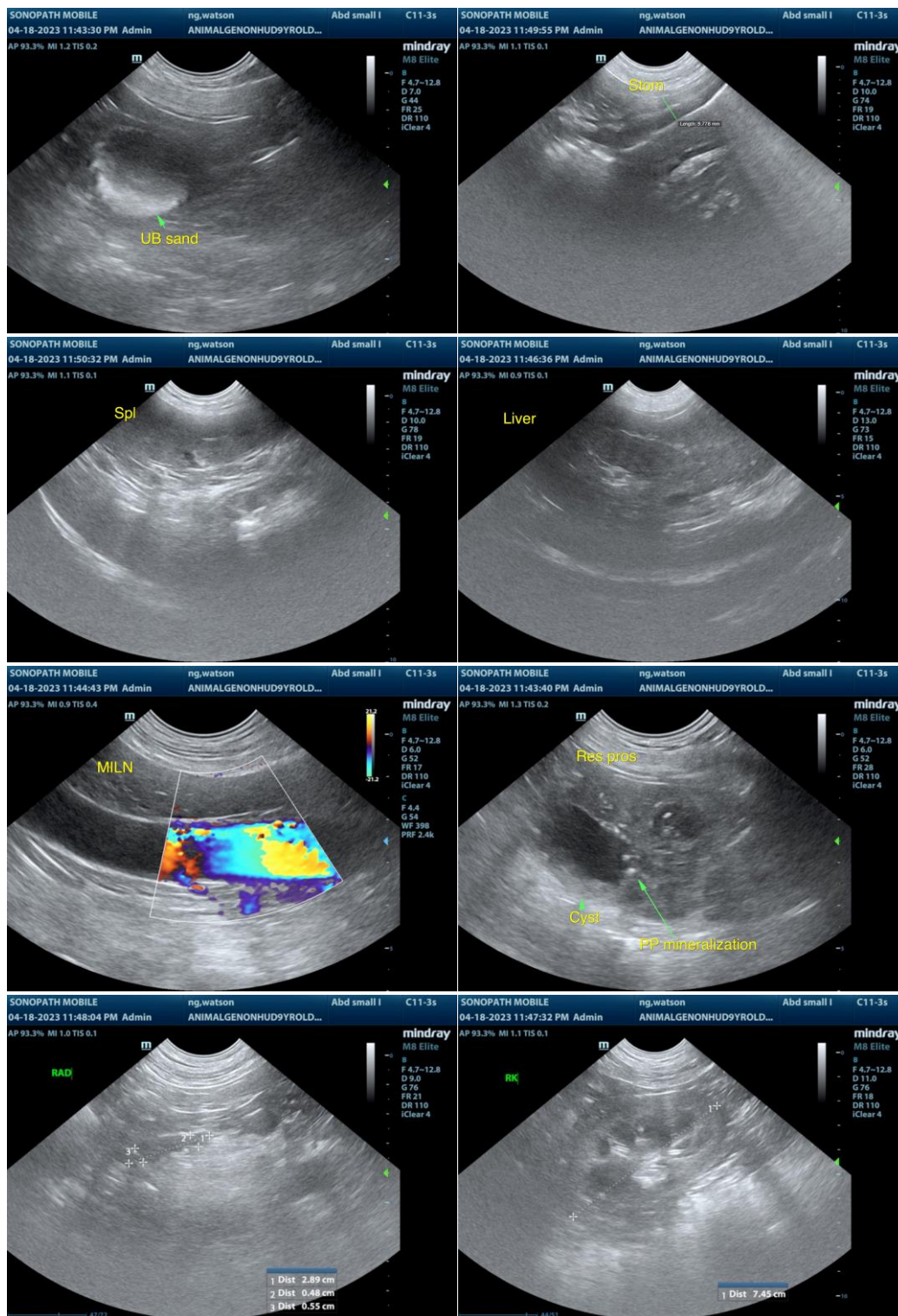
Dr. Vivian Ng

INVOICE

16650

DATE

4/19/23





PATIENT

Watson Ng

SPECIES

Canine

BREED

Cane Corso

SEX

MN

AGE

9 years

WEIGHT

130 lbs.

INTERPRETED BY

R. McKenzie Daniel,
DVM, DABVP
(Canine and Feline)

IMAGING PERFORMED BY

Kelly Vazquez

HOSPITAL NAME

Animal General on
Hudson

REFERRING VET

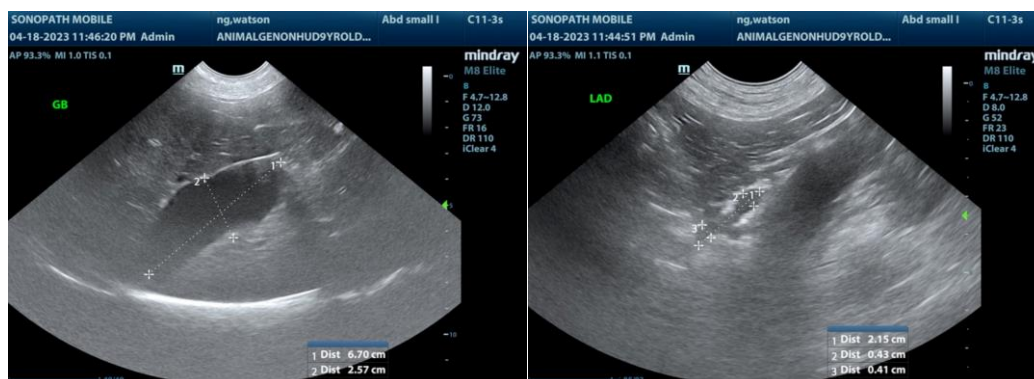
Dr. Vivian Ng

INVOICE

16650

DATE

4/19/23



The information and recommendations provided are based on the images presented by the referring veterinarian/sonographer. No evaluation can be communicated regarding pathology that was not visible in the image/video clips provided.

Thank you for this referral. If the clinical or image interpretation does not parallel your findings or if I can be of any further assistance please contact me.

R. McKenzie Daniel, DVM, DABVP (Canine / Feline Practice)
info@SonoPath.com