



PATIENT	PRESENTING CLINICAL SIGNS
Luigi Collazo	History of FIC, previous PU performed 2021. Several flares of FIC over last year, and empiric treatment with amoxicillin most recently in Dec 2022. P presents for several days of hematuria and stranguria.
SPECIES	Abnormal PE/Chem/CBC/UA Results: New mild ELE, pyuria and hematuria with possible rods - U C+S pending. Single vomiting episode reported by O, clear fluid and unsure which cat in household provided. No change in appetite or behaviors otherwise. On PE, no remarkable findings aside from obesity. ALT 164 ALP 114 GGT 17
Feline	
BREED	ULTRASONOGRAPHIC EXAMINATION OF THE ABDOMEN
DSH	Urinary System
SEX	The urinary bladder presented uniformly thickened urinary bladder wall isoechoic to the adjacent normal urinary bladder wall. The luminal margin of the thickened urinary bladder wall was mildly asymmetrical in contour. Urinary bladder wall thickness measured 0.42 cm. Mineralization or echogenic foci within the thickened areas of urinary bladder wall was not present. The urinary bladder, trigone, cystourethral junction, and visible pelvic urethra exhibited normal tone. Anechoic urine was present in the lumen with primarily small possible accumulated dependent mineral to small calculi. The total area of luminal mineral measured 1.1 cm in diameter. The ureteral papillae were normal. The ureters were not visible which is normal.
MN	
AGE	
5yr	
WEIGHT	Mildly prominent right kidney size was present. A normal 1:3 cortex / medulla ratio and normal corticomedullary definition were maintained. The echogenicity of the cortex was similar to or slightly less than normal liver parenchyma while the medulla echogenicity was hypoechoic to the cortex with no evidence of pelvic dilation or pyelonephritis. The left kidney measured 4.3 cm in length. The right kidney measured 4.8 cm in length.
9kg	
INTERPRETED BY	The area of the aortic trifurcation was free of pathology.
R. McKenzie Daniel, DVM, DABVP (Canine and Feline)	Adrenal Glands
IMAGING PERFORMED BY	The left adrenal gland was uniform in size and contour with a uniformly hypoechoic parenchyma. The left adrenal gland measured 0.55 cm width. The right adrenal gland was uniform in size and contour with a uniformly hypoechoic parenchyma. The right adrenal gland measured 0.67 cm width.
Wendy Turner	Spleen
HOSPITAL NAME	The spleen exhibited a finely textured and homogenous parenchyma which was hyperechoic to the liver and renal cortical parenchyma. The capsule was smooth and regular without apparent expansion. The splenic vasculature at the hilus was normal in volume with no evidence of congestion or thrombosis. Acute to chronic inflammatory, neoplastic, or benign parenchyma changes were not noted.
Pennsauken Animal Hospital	Liver/Gallbladder
REFERRING VET	The liver was subjectively normal in size, structure, and contour. The liver parenchyma was uniform and hypoechoic to the spleen with a mild coarse echotexture. The hepatic and portal vasculature were normal in appearance without signs of congestion. The gallbladder was non-distended in size with thin walls and primarily anechoic luminal content. The cystic and common bile ducts were normal.
Dr. Honeyford	Gastrointestinal
INVOICE	
13531ag	
DATE	
04/18/2023	



PATIENT

Luigi Collazo

The stomach presented intact wall layering with a normal wall layer ratio. The lumen of the stomach was empty with no signs of ileus, obstruction or foreign material.

SPECIES

Feline

The small intestine presented intact wall layering with 1:3 muscularis/mucosa ratio. The lumen of the small intestine was empty with no signs of ileus, obstruction or foreign material.

Normal visible colon wall layers were present with apparent formed feces in lumen.

Pancreas

BREED

DSH

The parenchyma of the left limb, body and right limb of the pancreas presented isoechoic to the adjacent omental fat. A normal curvilinear capsule contour of the pancreas was present. The visible pancreatic duct was normal. No signs of active inflammation or neoplastic disease was evident.

SEX

MN

Free Abdomen

No omental masses, overt lymphadenopathy or peritoneal effusion was present.

ULTRASONOGRAPHIC FINDINGS

AGE

5yr

- Cystitis pattern with luminal mineral/calculi.
- Normal bilateral kidneys.
- Benign hepatopathy-potential low grade inflammatory hepatopathy.
- Sonographically unremarkable GI tract.

WEIGHT

9kg

INTERPRETATION OF THE FINDINGS & FURTHER RECOMMENDATIONS

A urinary diet and continued empirical therapy for idiopathic cystitis would be reasonable. Pending urine C/S, potential embedded infection within the urinary bladder could be possible. Sonographic monitoring of the urinary bladder for evidence of persistent/progressive or resolving urinary calculi/cystitis is recommended.

INTERPRETED BY

R. McKenzie Daniel,
DVM, DABVP
(Canine and Feline)

Cystotomy with urinary bladder mural biopsy and tissue C/S may eventually be indicated in this patient.

IMAGING PERFORMED BY

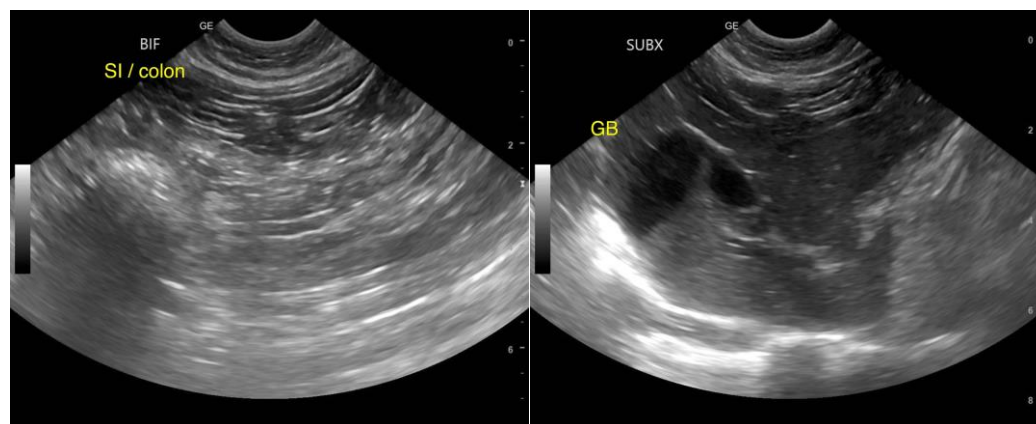
Wendy Turner

HOSPITAL NAME

Pennsauken Animal
Hospital

REFERRING VET

Dr. Honeyford

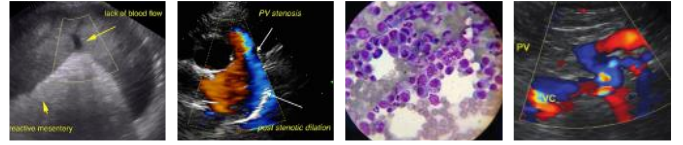


INVOICE

13531ag

DATE

04/18/2023



PATIENT

Luigi Collazo

SPECIES

Feline

BREED

DSH

SEX

MN

AGE

5yr

WEIGHT

9kg

INTERPRETED BY

R. McKenzie Daniel,
DVM, DABVP
(Canine and Feline)

IMAGING PERFORMED BY

Wendy Turner

HOSPITAL NAME

Pennsauken Animal Hospital

REFERRING VET

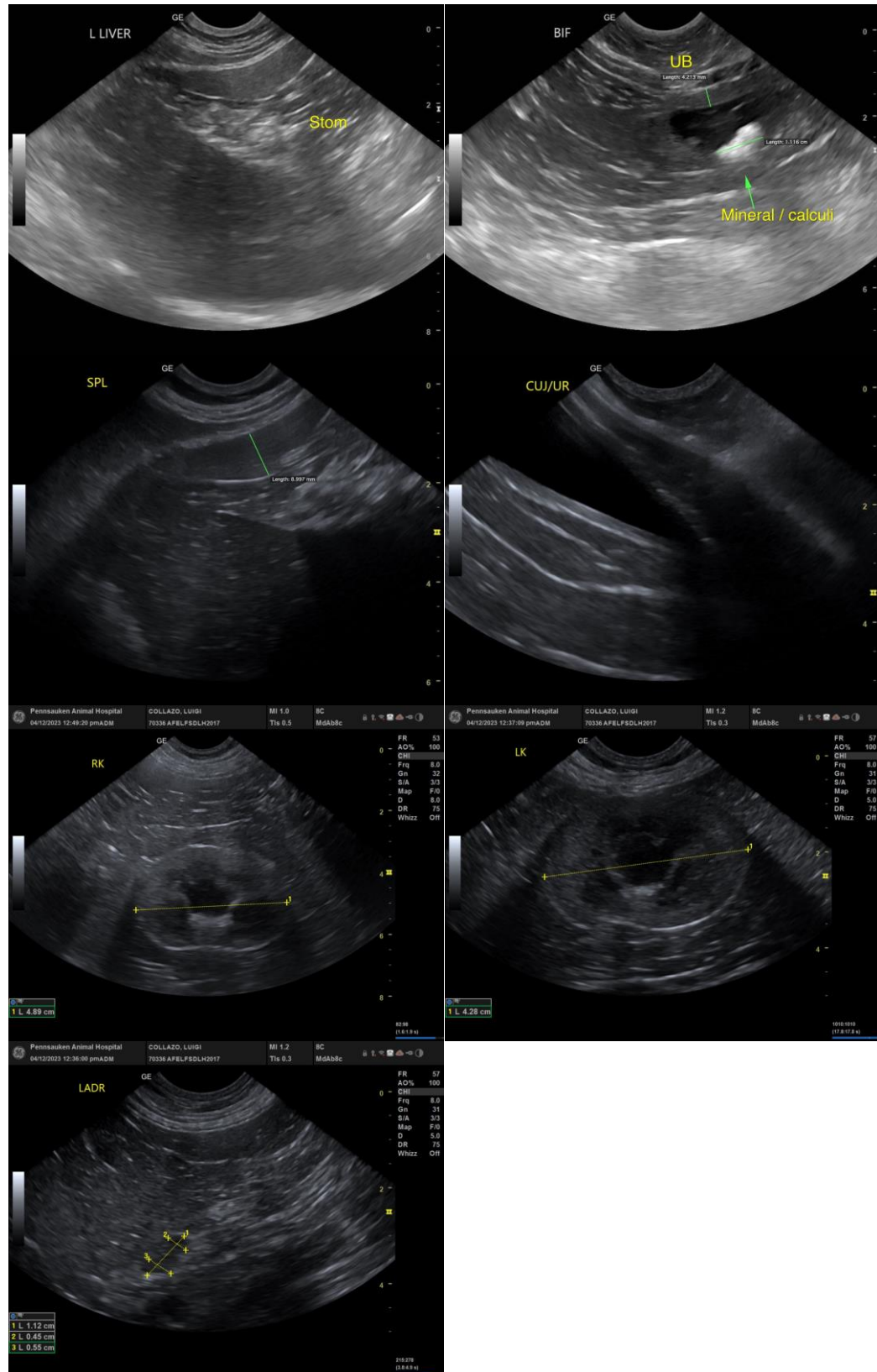
Dr. Honeyford

INVOICE

13531ag

DATE

04/18/2023



The information and recommendations provided are based on the images presented by the referring



PATIENT

Luigi Collazo

veterinarian/sonographer. No evaluation can be communicated regarding pathology that was not visible in the image/video clips provided.

Thank you for this referral. If the clinical or image interpretation does not parallel your findings or if I can be of any further assistance, please contact me.

SPECIES

Feline

R. McKenzie Daniel, DVM, DABVP (Canine/Feline Practice)
mac.daniel@sonopath.com

BREED

DSH

SEX

MN

AGE

5yr

WEIGHT

9kg

INTERPRETED BY

R. McKenzie Daniel,
DVM, DABVP
(Canine and Feline)

**IMAGING
PERFORMED BY**

Wendy Turner

HOSPITAL NAME

Pennsauken Animal
Hospital

REFERRING VET

Dr. Honeyford

INVOICE

13531ag

DATE

04/18/2023