



PATIENT PRESENTING CLINICAL SIGNS

Kato Johnson vomiting and weight loss - despite good appetite and activity Kato vomits several times each day

SPECIES Abnormal PE/Chem/CBC/UA Results: mild elevation in Amylase , all else WNL

Feline ULTRASONOGRAPHIC EXAMINATION OF THE ABDOMEN

BREED *Urinary System*

DSH The urinary bladder, trigone, cystourethral junction, and visible pelvic urethra to a depth of 2 cm exhibited normal thickness and tone. Anechoic urine was present in the lumen with moderate non-dependent particulate sediment. The sediment may indicate cellular debris / protein, crystalline debris, lipid, or mucus. The ureteral papillae were normal. The ureters were not visible which is normal. No evidence of inflammatory or neoplastic changes were noted.

SEX FS
AGE 16yr
Normal renal size with asymmetrical margination was present in both kidneys. The renal cortex presented uniformly increased in echogenicity with uniform echotexture. The renal cortex appeared to be hypertrophied resulting in an altered cortex: medulla ratio. Mild loss of corticomedullary distinction was also present. The renal medullary volume was subjectively reduced. The left kidney measured 3.9 cm in length. The right kidney measured 3.8 cm in length.

WEIGHT 6.8lb
The area of the aortic trifurcation was free of pathology.

Adrenal Glands

INTERPRETED BY The left adrenal gland was uniform in size and contour with a uniformly hypoechoic parenchyma. The left adrenal gland measured 0.38 cm width. The right adrenal gland was uniform in size and contour with a uniformly hypoechoic parenchyma. The right adrenal gland measured 0.61 cm width.

R. McKenzie Daniel,
DVM, DABVP
(Canine and Feline)

Spleen

IMAGING PERFORMED BY The spleen exhibited marked enlargement with folding. Symmetrical to rounded splenic contour was noted with a finely textured and non-homogenous parenchyma which was hyperechoic to the liver and renal cortical parenchyma. The splenic vasculature at the hilus was normal in volume with no evidence of congestion or thrombosis.

Jenna Walsh CVT

Liver/Gallbladder

HOSPITAL NAME The liver was subjectively normal in size, structure, and contour. The liver parenchyma was uniform and hypoechoic to the spleen with a mild coarse echotexture. The hepatic and portal vasculature were normal in appearance without signs of congestion. The gallbladder was non-distended in size with thin walls and primarily anechoic luminal content. The cystic and common bile ducts were normal.

The Veterinary Hospital

REFERRING VET

Dr. Johnson

Gastrointestinal

INVOICE 13530ag
The stomach presented intact wall layering with a normal wall layer ratio. The lumen of the stomach contained mild to moderate non-shadowing echogenic ingesta with no signs of ileus, obstruction or foreign material.

DATE 04/18/2023
The small intestine presented intact wall layering with 1:3 muscularis/mucosa ratio. The lumen of the small intestine was empty with no signs of ileus, obstruction or foreign material. Intermittent non-specific hyperechoic mucosal speckling was present.



PATIENT Normal visible colon wall layers were present with apparent semi formed to soft feces in lumen.

Kato Johnson **Pancreas**

SPECIES The pancreas presented hypoechoic to heterogeneous echogenicity compared to adjacent omental fat. Mild asymmetrical capsule margination was present with mild variable parenchymal swelling and mild peripancreatic reactivity / inflammation. No overt evidence of neoplasia. Mild pancreatic duct dilation was present.

Feline

BREED **Free Abdomen**

DSH No omental masses or overt lymphadenopathy was present.

SEX Mild volume primarily perisplenic free fluid was present.

FS **ULTRASONOGRAPHIC FINDINGS**

AGE

16yr

WEIGHT

6.8lb

- Urinary bladder sediment.
- Mild chronic renal changes.
- Marked splenomegaly-primary concern for infiltrative round cell neoplastic criteria, potential for significant benign hyperplasia, hematopoiesis, focal splenitis or similar possible.
- Gastric ingesta-sonographically consistent with food.
- Intact small bowel walls with mild non-specific hyperechoic mucosal speckling-at times intestinal mucosal speckling has been associated with inflammatory criteria.
- Mild pancreatitis.
- Mild volume peritoneal free fluid.

INTERPRETED BY

R. McKenzie Daniel,
DVM, DABVP
(Canine and Feline)

INTERPRETATION OF THE FINDINGS & FURTHER RECOMMENDATIONS

The urinary bladder sediment may suggest cellular / crystalline debris or mucus. Cystocentesis for UA +/- C/S if evidence of inflammatory cells is recommended. The presence of gastric ingesta is nonspecific and likely indicates post-prandial presentation. Correlation with most recent meal ingestion is recommended. If documented NPO prior to the ultrasound, the presence of gastric ingesta may indicate some degree of gastric hypomotility or metabolic stasis. The sonographic presentation of the ingesta was most consistent with food, without evidence of foreign material.

IMAGING PERFORMED BY

Jenna Walsh CVT

HOSPITAL NAME

The Veterinary Hospital

REFERRING VET

Dr. Johnson

INVOICE

13530ag

DATE

04/18/2023

Assuming normal clotting status with Benadryl premed and using a 25g needle, a splenic FNA for screening cytology is warranted for further assessment. A GI panel to include PLI/TLI/Cobalamin/Folate is recommended. Three view chest radiographs are recommended if not done to assess for occult thoracic pathology. A guarded prognosis pending splenic cytology which is required for further clarification.



PATIENT

Kato Johnson

SPECIES

Feline

BREED

DSH

SEX

FS

AGE

16yr

WEIGHT

6.8lb

INTERPRETED BY

R. McKenzie Daniel,
DVM, DABVP
(Canine and Feline)

IMAGING PERFORMED BY

Jenna Walsh CVT

HOSPITAL NAME

The Veterinary
Hospital

REFERRING VET

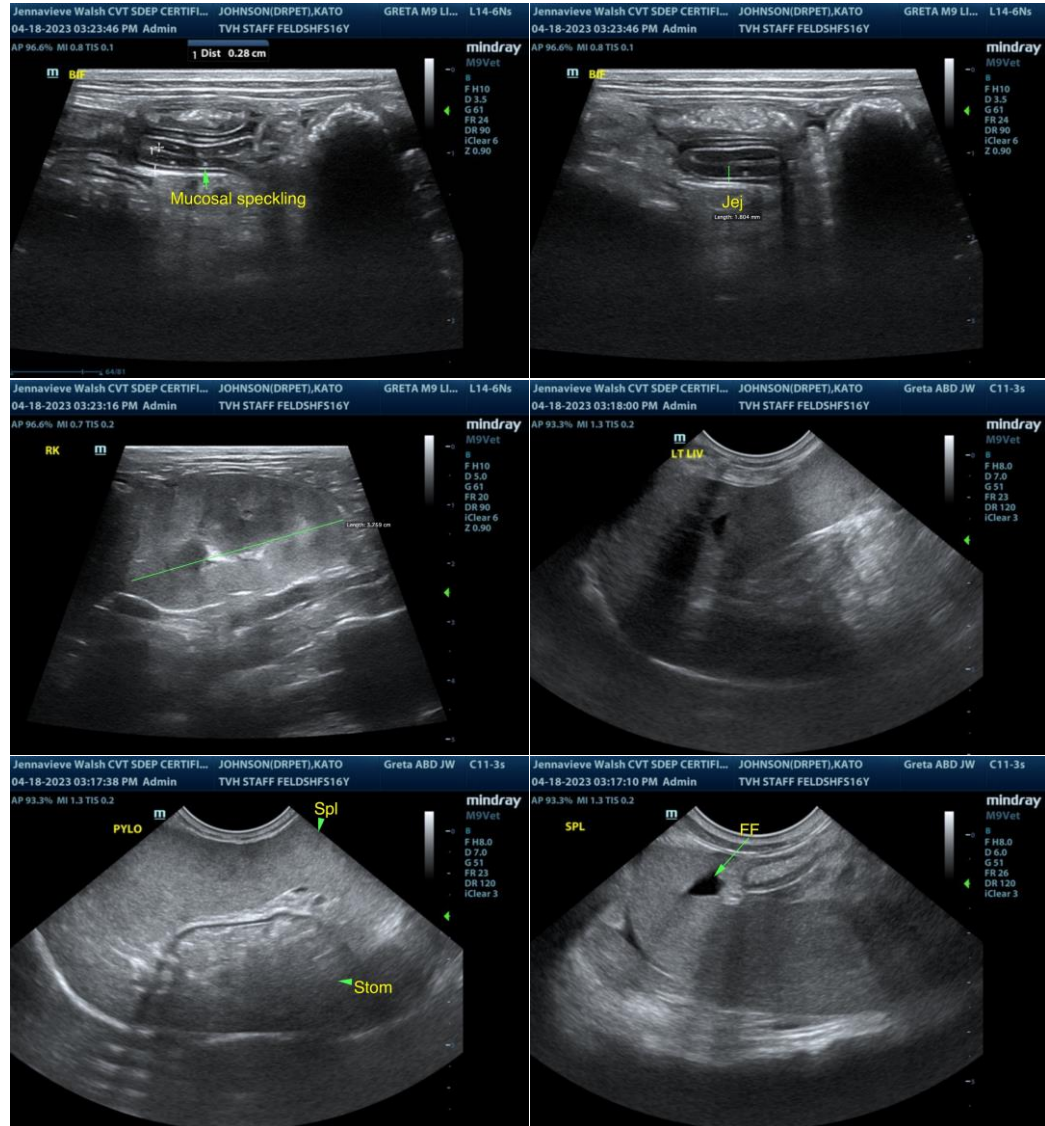
Dr. Johnson

INVOICE

13530ag

DATE

04/18/2023





PATIENT

Kato Johnson

SPECIES

Feline

BREED

DSH

SEX

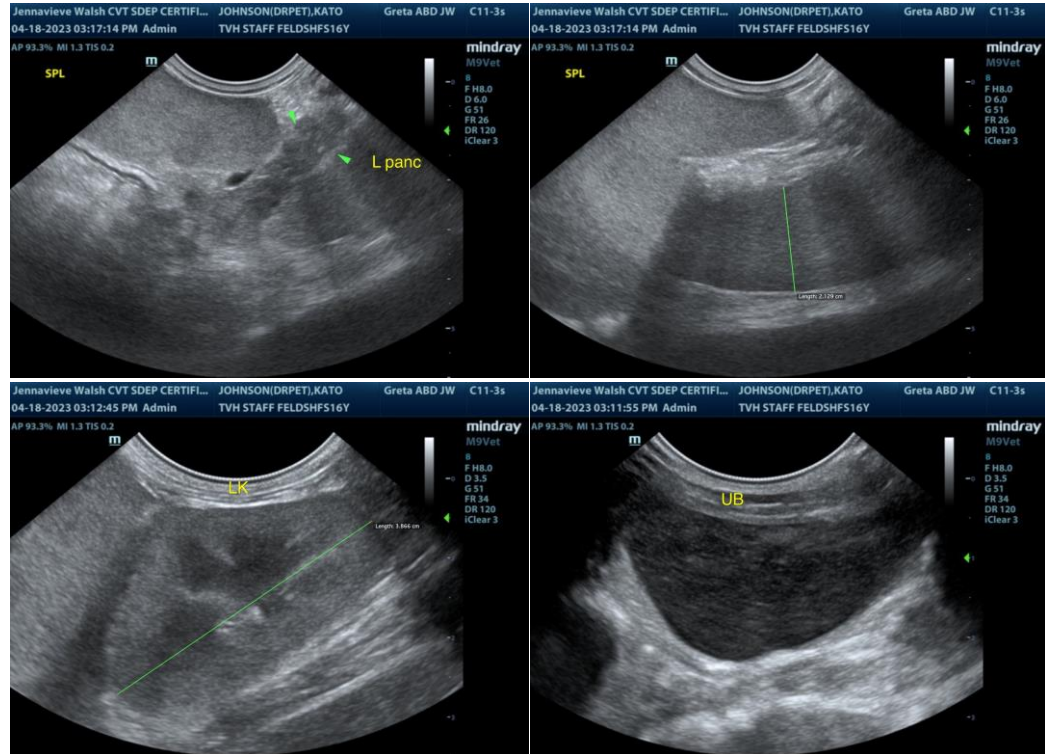
FS

AGE

16yr

WEIGHT

6.8lb



INTERPRETED BY

R. McKenzie Daniel,
DVM, DABVP
(Canine and Feline)

IMAGING PERFORMED BY

Jenna Walsh CVT

HOSPITAL NAME

The Veterinary
Hospital

REFERRING VET

Dr. Johnson

INVOICE

13530ag

DATE

04/18/2023

The information and recommendations provided are based on the images presented by the referring veterinarian/sonographer. No evaluation can be communicated regarding pathology that was not visible in the image/video clips provided.

Thank you for this referral. If the clinical or image interpretation does not parallel your findings or if I can be of any further assistance please contact me.

R. McKenzie Daniel, DVM, DABVP (Canine / Feline Practice)

info@SonoPath.com