Pennsylvania Mobile
VETERINARY ULTRASOUND SERVICES

IMAGING PERFORMED BY
PAMobileVet.com 443-794-4700

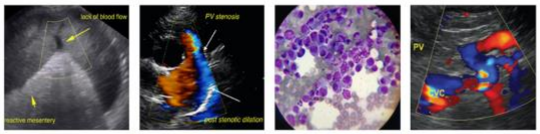

SonoPath
Clinical Sonography & Telecytology
EDUCATIONAL TELECONSULTATION SERVICES™
1-800-838-4268 info@sonopath.com SonoPath.com

PATIENT
Tia Rashko

SPECIES
Canine

BREED
Brittany

SEX
Spayed Female

AGE
2010

WEIGHT
44.6 Pounds

INTERPRETED BY
R. McKenzie Daniel, DVM, DABVP (Canine and Feline)

IMAGING PERFORMED BY
Rebekah Jakum, CVT ARDMS/RVT

HOSPITAL NAME
Lehighton AH

REFERRING VET
Dr. Carpenter

INVOICE
14813

DATE
4/18/22

PRESENTING CLINICAL SIGNS

History: Coughing when eating, PU/PD, weak and painful hind end, excessive panting, lethargy

Labs: hematocrit 32, platelets 68, BUN 36, ALT 213, ALP 641, lipase 4456, Amylase >2500

ULTRASONOGRAPHIC EXAMINATION OF THE ABDOMEN

Urinary System

The urinary bladder, trigone, cystourethral junction, and visible pelvic urethra to a depth of 2.0 cm exhibited normal thickness and tone. Anechoic urine was present in the lumen with no uroliths or sediment. The ureteral papillae were normal. The ureters were not visible which is normal. No evidence of inflammatory or neoplastic changes were noted. Aortic trifurcation was normal.

Normal size and margination were present in the kidneys. A normal 1:3 cortex / medulla ratio was maintained. The medulla and cortices were uniform in texture with some increased echogenicity and mild loss of corticomedullary symmetry and definition expected for the age of the patient. No evidence of pelvic dilation was present. The left kidney measured 6.6 cm in length. The right kidney measured 6.5 cm in length.

Adrenal Glands

The bilateral adrenal glands were normal in size. Mild parenchyma heterogeneity and mild capsule asymmetry was present without overt evidence of hyperplasia or neoplastic criteria. The left adrenal gland measured 2.5 cm x 0.66 cm. The right adrenal gland measured 2.2 cm in length x 0.59 cm width at the caudal pole.

Spleen

The spleen exhibited a finely textured and homogenous parenchyma which was hyperechoic to the liver and renal cortical parenchyma. The capsule was smooth and regular without apparent expansion. The splenic vasculature at the hilus was normal in volume with no evidence of congestion or thrombosis. Acute to chronic inflammatory, neoplastic, or benign parenchyma changes were not noted.

Liver

The liver exhibited generalized enlargement. The liver revealed primarily maintained symmetrical yet swollen hepatic capsule contour with subtle areas of capsule asymmetry and generalized nonuniform hepatic parenchyma echotexture, exhibiting mildly echogenic parenchyma echogenicity, evidence of parenchymal remodeling. Solitary to potential multiple mildly expansive nonhomogeneous to nodular masses noted in the subjective left to mid ventral to deep liver. An example measured 4-5 cm in diameter.

The gallbladder was non-distended in size with thin walls and primarily anechoic luminal content. The cystic and common bile ducts were normal.

Gastrointestinal

The stomach presented intact wall layering with a normal wall layer ratio. The lumen of the stomach was empty with no signs of ileus, obstruction or foreign material.

The small intestine presented intact wall layering with 1:3 muscularis/mucosa ratio. The lumen of the small intestine was empty with no signs of ileus, obstruction or foreign material.

Normal visible colon wall layers were present with apparent formed feces in lumen.

Pennsylvania Mobile
VETERINARY ULTRASOUND SERVICES
IMAGING PERFORMED BY
PAMobileVet.com 443-794-4700

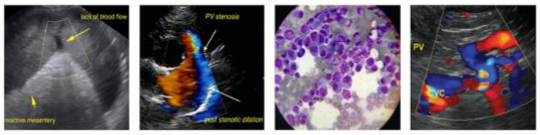

SonoPath
Clinical Sonography & Telecytology
EDUCATIONAL TELECONSULTATION SERVICES™
1-800-838-4268 info@sonopath.com SonoPath.com

PATIENT

Tia Rashko

SPECIES

Canine

BREED

Brittany

SEX

Spayed Female

AGE

2010

WEIGHT

44.6 Pounds

INTERPRETED BY

R. McKenzie Daniel, DVM, DABVP (Canine and Feline)

IMAGING PERFORMED BY

Rebekah Jakum, CVT ARDMS/RVT

HOSPITAL NAME

Lehighton AH

REFERRING VET

Dr. Carpenter

INVOICE

14813

DATE

4/18/22

Pancreas

The right pancreatic limb exhibited mild prominent size with mild capsule asymmetry and subjective hypoechoic to nonhomogeneous parenchyma.

Free Abdomen

No omental masses, lymphadenopathy or peritoneal effusion.

ULTRASONOGRAPHIC FINDINGS

- Hepatomegaly, exhibiting generalized nonhomogeneous parenchyma with focal to possible several nonhomogeneous to nodular mildly expansive masses
- Sonographically unremarkable gallbladder
- Bilateral chronic renal changes
- Overtly normal gastrointestinal
- Hypoechoic to nonhomogeneous right pancreas- potential concurrent right chronic active pancreatitis

INTERPRETATION OF THE FINDINGS & FURTHER RECOMMENDATIONS

The hepatic changes are nonspecific with potential considerations including vacuolar hepatopathy, inflammatory/immune mediated disease, nodular hyperplasia, possible early fibrosis, hematopoiesis, infiltrative neoplasia or other hepatopathy.

Assuming normal clotting status, ultrasound guided FNA of the hepatic parenchyma, as well as the nodular mass, using a 25-guage needle is warranted for screening cytology and further clarification if potential for oncology consult. Screening UCCR could be considered with additional adrenal testing, if strong clinical suspicion of adrenal hyperfunction, however, the bilateral adrenal glands were not overtly consistent with hyperplasia and without evidence of neoplastic criteria. Three-view chest radiographs suggested if not done.

Pennsylvania Mobile
VETERINARY ULTRASOUND SERVICES

IMAGING PERFORMED BY
PAMobileVet.com 443-794-4700

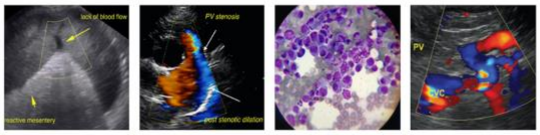

SonoPath
Clinical Sonography & Telecytology
EDUCATIONAL TELECONSULTATION SERVICES™
1-800-838-4268 info@sonopath.com SonoPath.com

PATIENT

Tia Rashko

SPECIES

Canine

BREED

Brittany

SEX

Spayed Female

AGE

2010

WEIGHT

44.6 Pounds

INTERPRETED BY

R. McKenzie Daniel, DVM, DABVP (Canine and Feline)

IMAGING PERFORMED BY

Rebekah Jakum, CVT ARDMS/RVT

HOSPITAL NAME

Lehighton AH

REFERRING VET

Dr. Carpenter

INVOICE

14813

DATE

4/18/22

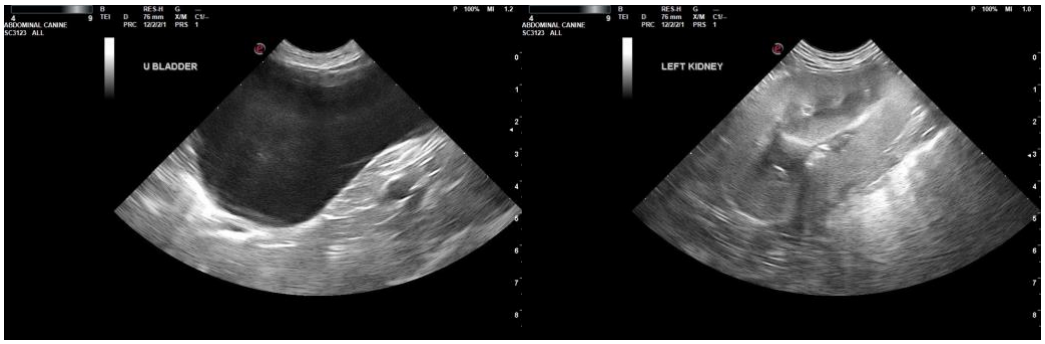

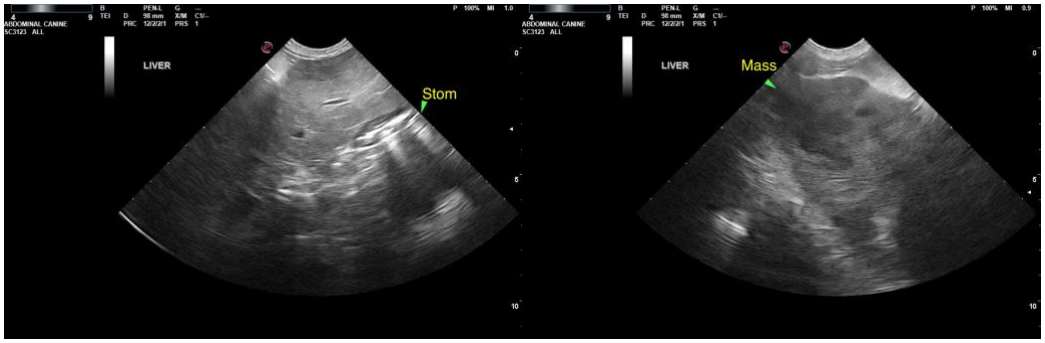

Pennsylvania Mobile
VETERINARY ULTRASOUND SERVICES

IMAGING PERFORMED BY
PAMobileVet.com 443-794-4700

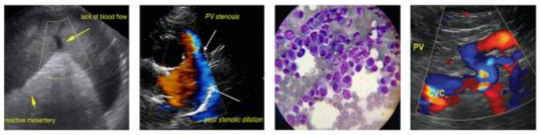

SonoPath
Clinical Sonography & Telecytology
EDUCATIONAL TELECONSULTATION SERVICES™
1-800-838-4268 info@sonopath.com SonoPath.com

PATIENT

Tia Rashko

SPECIES

Canine

BREED

Brittany

SEX

Spayed Female

AGE

2010

WEIGHT

44.6 Pounds

INTERPRETED BY

R. McKenzie Daniel, DVM, DABVP (Canine and Feline)

IMAGING PERFORMED BY

Rebekah Jakum, CVT ARDMS/RVT

HOSPITAL NAME

Lehighton AH

REFERRING VET

Dr. Carpenter

INVOICE

14813

DATE

4/18/22

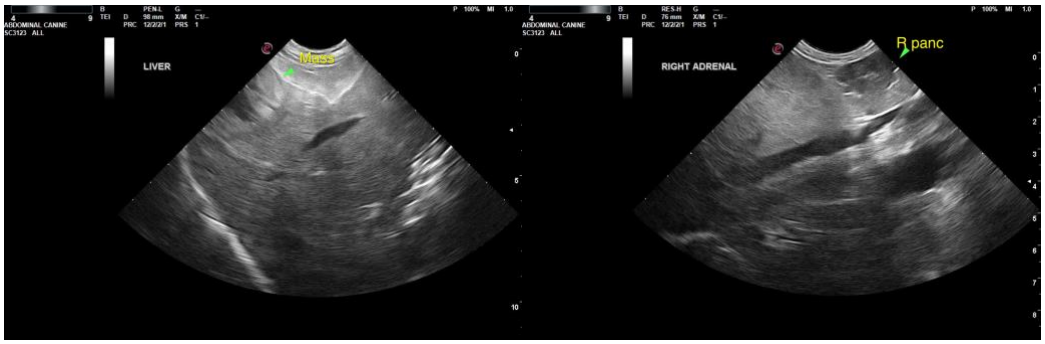

The information and recommendations provided are based on the images presented by the referring veterinarian. No evaluation can be communicated regarding pathology that was not visible in the image/video clips provided.

Thank you for this referral. If the clinical or image interpretation does not parallel your findings or if I can be of any further assistance please contact me.

R. McKenzie Daniel, DVM, DABVP (Canine/Feline Practice)
mac.daniel@sonopath.com