



**PATIENT PRESENTING CLINICAL SIGNS**

Nena Harter History: lethargic and acting painful the last 24 hours. Hx of mld liver enzyme elevations; hepatomegaly; ascites noted on rads as well as possible cardiomegaly

**SPECIES** Abnormal PE/Chem/CBC/UA Results:

Canine **ULTRASONOGRAPHIC EXAMINATION OF THE HEART AND ABDOMEN**

**BREED**

Eskimo Spitz

**SEX**

Female

**AGE**

9 years

**WEIGHT**

43.5 pounds

CANINE CARDIAC PARAMETERS	MR VMAX (m/s)	TR VMAX (m/s)	LA/AO (Boon method)	LA/AO (Heart Base; Swe)	FS (%)	EF (%)	EPSS (cm)
NORMAL PARAMETER	4.5-5.5	<2.7	1.3	<1.3	28-40	40-100	<0.6
PATIENT	NM	NM	1.0	1.1	36.2	68	0.25
CANINE CARDIAC PARAMETERS	HR (BPM)	AV VMAX (m/s)	PV MAX (m/s)	BODY WEIGHT (kg)	LA 2D short axis Base view (cm)	LVIDd Avg; 2D and m-mode short axis (cm)	LVIDs Avg; 2D and m-mode short axis (cm)
NORMAL PARAMETER	50-100	0.7-1.7	0.7-1.6				
PATIENT	185	1.6	1.0		2.5	2.65	NM

**INTERPRETED BY**

R. McKenzie Daniel, DVM, DABVP (Canine and Feline)

**IMAGING PERFORMED BY**  
Diane McFadden

**HOSPITAL NAME**

Newton Veterinary Hospital

**REFERRING VET**

Dr. Verhalen

**INVOICE**

10411ag

**DATE**

04/18/2022

**Cardiac Presentation**

The echocardiogram in this patient demonstrated normal left atrial size based on 3 separate methods of LA evaluation. The cranial and caudal mitral valve leaflets presented normal linear structure, extension in systole, and union in diastole with normal kinesis. The left ventricle presented thicknesses with linear contour and was not dilated nor restricted. The myocardium presented normal echogenicity without subjective evidence of significant fibrotic or ischemic disease. Contractility of the ventricular walls was adequate and in normal range for this patient evidenced by the fractional shortening measurement and subjective evaluation of the different regions of the myocardium. The left ventricular outflow tract demonstrated normal laminar flow and subjective structural integrity. The right atrium and auricle revealed overall normal size, structure and content. A nonhomogeneous primarily spherical mass in the area of the RA specifically in the area of the right atrioventricular groove measuring 2.3 cm – 2.5 cm in diameter was noted. The mass appeared to extend into the area of the tricuspid valve. Tricuspid valvular assessment demonstrated overall adequate linear morphology and kinesis. The right ventricle was of normal size (1/3 diameter of LV), chordae structure, myocardial echogenicity and thickness. Pulmonary outflow tract assessment revealed normal valve structure, laminar flow, and diameter (approx.1:1 pa/ao ratio). Mild to moderate volume pericardial effusion was present with subjective secondary cardiac tamponade. No overt evidence or arrhythmogenic disease was observed. No overt evidence of pleural free fluid was noted.

**Urinary System**

The urinary bladder, trigone, cystourethral junction, and visible pelvic urethra exhibited normal thickness and tone. Anechoic urine was present in the lumen with no uroliths or sediment. The ureteral



<b>PATIENT</b>	papillae were normal. The ureters were not visible which is normal. No evidence of inflammatory or neoplastic changes were noted.
Nena Harter	
<b>SPECIES</b>	Normal size and margination were present in the kidneys. A normal 1:3 cortex / medulla ratio and normal corticomedullary definition were maintained. The echogenicity of the cortex was similar to or slightly less than normal liver parenchyma while the medulla echogenicity was hypoechoic to the cortex with no evidence of pelvic dilation. The left kidney measured 5.5 cm in length. The right kidney measured 5.3 cm in length.
Canine	
<b>BREED</b>	<b>Adrenal Glands</b>
Eskimo Spitz	The left adrenal gland was uniform in size and contour with a uniformly hypoechoic parenchyma. The left adrenal gland measured 0.65 cm width at the caudal pole and 2.8 cm in length. The right adrenal gland was uniform in size and contour with a uniformly hypoechoic parenchyma. The right adrenal gland measured 0.63 cm width at the caudal pole and 2.9 cm in length.
<b>SEX</b>	<b>Spleen</b>
Female	The spleen exhibited a finely textured and homogenous parenchyma which was hyperechoic to the liver and renal cortical parenchyma. The capsule was smooth and regular without apparent expansion. The splenic vasculature at the hilus was normal in volume with no evidence of congestion or thrombosis. Acute to chronic inflammatory, neoplastic, or benign parenchyma changes were not noted.
<b>AGE</b>	
9 years	
<b>WEIGHT</b>	<b>Liver</b>
43.5 pounds	The liver exhibited generalized enlargement with symmetrical to slightly swollen structure and contour. The liver parenchyma was uniform and hypoechoic to the spleen with a mild coarse echotexture. Subjective mild hepatic and portal vasculature congestion was observed, most notable at the level of the hepatic vein caudal vena cava junction. Mild concurrent cranial abdominal caudal vena cava distension was present measuring 1.7 cm in diameter.
<b>INTERPRETED BY</b>	<b>Gastrointestinal</b>
R. McKenzie Daniel, DVM, DABVP (Canine and Feline)	The gallbladder was mildly distended in size. The gallbladder wall was thickened in appearance consisting of an echogenic double rim corresponding to the inner and outer portions of the wall. This is consistent with gallbladder wall edema. Possible causes may include acute inflammation, edema and anaphylaxis. The cystic and common bile ducts were normal.
<b>IMAGING PERFORMED BY</b>	
Diane McFadden	
<b>HOSPITAL NAME</b>	The stomach presented intact wall layering with a normal wall layer ratio. The lumen of the stomach was empty with no signs of ileus, obstruction or foreign material.
Newton Veterinary Hospital	The small intestine presented intact wall layering with 1:3 muscularis/mucosa ratio. The lumen of the small intestine was empty with no signs of ileus, obstruction or foreign material.
<b>REFERRING VET</b>	Normal visible colon wall layers were present with apparent formed feces in lumen.
Dr. Verhalen	<b>Pancreas</b>
<b>INVOICE</b>	The parenchyma of the left limb, body and right limb of the pancreas presented isoechoic to the adjacent omental fat. A normal curvilinear capsule contour of the pancreas was present. The visible pancreatic duct was normal. No signs of active inflammation or neoplastic disease was evident.
10411ag	<b>Free Abdomen</b>
<b>DATE</b>	Mild volume subjectively acellular ascites was present. The omentum exhibited uniform normal echogenicity with no overt lymphadenopathy or omental masses noted.
04/18/2022	



**PATIENT**

Nena Harter

**SPECIES**

Canine

**BREED**

Eskimo Spitz

**SEX**

Female

**AGE**

9 years

**WEIGHT**

43.5 pounds

**INTERPRETED BY**

R. McKenzie Daniel,  
DVM, DABVP  
(Canine and Feline)

**IMAGING PERFORMED BY**  
Diane McFadden

**HOSPITAL NAME**

Newton Veterinary  
Hospital

**REFERRING VET**

Dr. Verhalen

**INVOICE**

10411ag

**DATE**

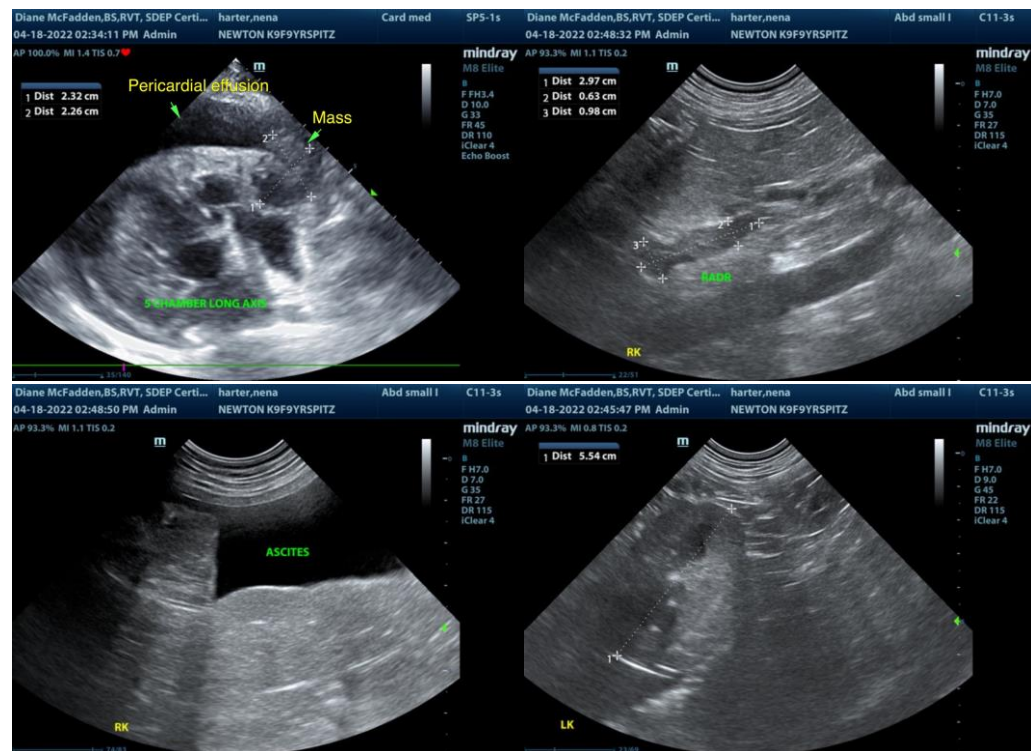
04/18/2022

**ULTRASONOGRAPHIC FINDINGS**

- RA/atrioventricular groove mass-consistent with neoplastic criteria, primary differential diagnosis hemangiosarcoma.
- Mild to moderate pericardial free fluid and secondary cardiac tamponade.
- Mild congestive hepatomegaly with mild gallbladder wall edema.
- Unremarkable spleen.

**INTERPRETATION OF THE FINDINGS & FURTHER RECOMMENDATIONS**

No overt evidence of primary intra-abdominal neoplastic criteria as a cause of cardiac metastatic disease was noted. Alternative neoplastic etiologies for the RA/atrioventricular mass are possible yet thought less likely based on location. Further assessment may include pericardiocentesis for effusion analysis (hemorrhage or other). Likewise, abdominocentesis for ascites analysis to confirm ascites secondary to pericardial effusion and cardiac tamponade is recommended. Thoracic CT with potential for oncology and/or surgical consult could be considered if further therapy is elected. A likely unfavorable long-term prognosis is unfortunately indicated.





**PATIENT**

Nena Harter

**SPECIES**

Canine

**BREED**

Eskimo Spitz

**SEX**

Female

**AGE**

9 years

**WEIGHT**

43.5 pounds

**INTERPRETED BY**

R. McKenzie Daniel,  
DVM, DABVP  
(Canine and Feline)

**IMAGING PERFORMED BY**  
Diane McFadden

**HOSPITAL NAME**

Newton Veterinary  
Hospital

**REFERRING VET**

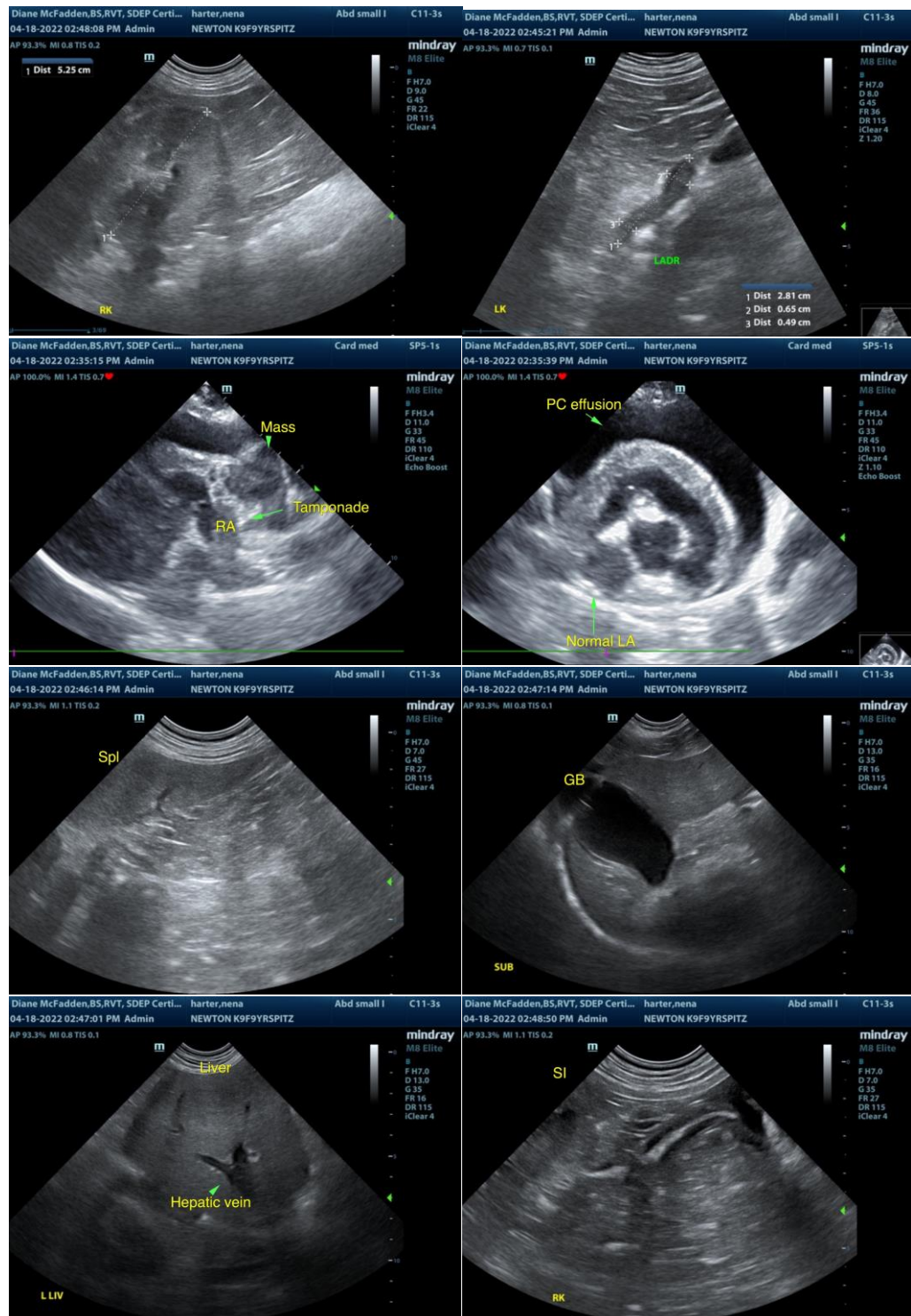
Dr. Verhalen

**INVOICE**

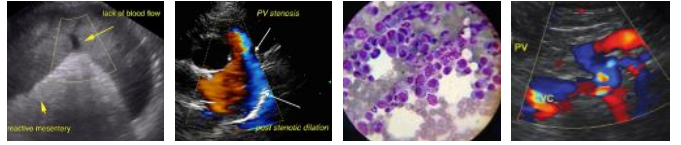
10411ag

**DATE**

04/18/2022



The information and recommendations provided are based on the images presented by the referring veterinarian/sonographer. No evaluation can be communicated regarding pathology that was not



**PATIENT** visible in the image/video clips provided.

Nena Harter Thank you for this referral. If the clinical or image interpretation does not parallel your findings or if I can be of any further assistance please contact me.

**SPECIES** R. McKenzie Daniel, DVM, DABVP (Canine / Feline Practice)

Canine info@SonoPath.com

**BREED**

Eskimo Spitz

**SEX**

Female

**AGE**

9 years

**WEIGHT**

43.5 pounds

**INTERPRETED BY**

R. McKenzie Daniel,  
DVM, DABVP  
(Canine and Feline)

**IMAGING  
PERFORMED BY**

Diane McFadden

**HOSPITAL NAME**

Newton Veterinary  
Hospital

**REFERRING VET**

Dr. Verhalen

**INVOICE**

10411ag

**DATE**

04/18/2022