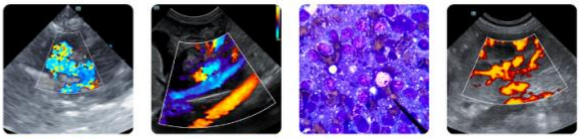

PATIENT
Jasper Holland

SPECIES
Canine

BREED
Poodle Mix

SEX
Neutered Male

AGE
11 Years

WEIGHT
9.1 kg

INTERPRETED BY
R. McKenzie Daniel, DVM, DABVP (Canine / Feline Practice)

IMAGING PERFORMED BY
Dr. Sarah Barthelemy

HOSPITAL NAME
Woodlands Vet

REFERRING VET
Dr. Nagy

INVOICE
15209

DATE
04/17/26

PRESENTING CLINICAL SIGNS

Suspected IMHA. AUS to assess for underlying disease

ULTRASONOGRAPHIC EXAMINATION OF THE ABDOMEN

Urinary System

The urinary bladder, trigone, cystourethral junction, and visible pelvic urethra to a depth of 3.0 cm exhibited normal thickness and tone. Anechoic urine was present in the lumen with no uroliths or sediment. The ureteral papillae were normal. The ureters were not visible which is normal. No evidence of inflammatory or neoplastic change were noted.

The area of the residual prostate appeared normal and free of pathology.

The visualized medial iliac lymph nodes were sonographically normal. No evidence of distal aortic thrombus.

Normal size and margination was present in the kidneys. A normal 1:3 cortex / medulla ratio was maintained. The medulla and cortices were uniform in texture with some increased echogenicity and mild loss of corticomedullary symmetry and definition expected for the age of the patient. No evidence of pelvic dilation was present. The left kidney measured 5.0 cm in length. The right kidney measured 4.9 cm in length.

Adrenal Glands

The left adrenal gland was uniform in size and contour with a uniformly hypoechoic parenchyma. The left adrenal gland measured 0.64 cm width at the caudal pole.

The right adrenal gland was uniform in size and contour with a uniformly hypoechoic parenchyma. The right adrenal gland measured 0.52 cm width at the caudal pole.

Spleen

The spleen presented subjective mildly enlarged with areas of mild medial capsule asymmetrical contour and heterogeneous to focal to regional subtle hypoechoic parenchyma. No evidence of masses or definitive intraparenchymal nodules. Normal splenic vascularity.

Liver & Gallbladder

The liver was subjectively normal in size, structure, and contour. The liver parenchyma was uniform and hypoechoic to the spleen with a mild coarse echotexture. The hepatic and portal vasculature were normal in appearance without signs of congestion.

The gallbladder was non distended in size with normal wall. Mild echogenic, nonmineralized, non-dependent biliary sludge is present. The biliary sludge is congealed without organization. No signs of peripheral inflammation.

Gastrointestinal

The stomach presented intact wall layering with a normal wall layer ratio. The lumen of the stomach contained variably echogenic, mild nonshadowing ingesta/chyme consistent with food echogenicity without signs of obstruction or foreign material.

PATIENT
Jasper Holland

SPECIES
Canine

BREED
Poodle Mix

SEX
Neutered Male

AGE
11 Years

WEIGHT
9.1 kg

INTERPRETED BY
R. McKenzie Daniel, DVM, DABVP (Canine / Feline Practice)

IMAGING PERFORMED BY
Dr. Sarah Barthelemy

HOSPITAL NAME
Woodlands Vet

REFERRING VET
Dr. Nagy

INVOICE
15209

DATE
04/17/26

The small intestine presented intact wall layering with 1:3 muscularis/mucosa ratio. The lumen of the small intestine was empty with no signs of ileus, obstruction or foreign material.

Normal visible colon wall layers were present with semi formed fecal matter.

Pancreas

The parenchyma of the left limb, body and right limb of the pancreas presented isoechoic to the adjacent omental fat. A normal curvilinear capsule contour of the pancreas was present. The visible pancreatic duct was normal. No signs of active inflammation or neoplastic disease was evident.

Free Abdomen

No overt lymphadenopathy or peritoneal effusion was present.

ULTRASONOGRAPHIC FINDINGS

- Mildly enlarged heterogeneous spleen.
- Noninflamed immature gallbladder mucocele.
- Sonographically normal gastrointestinal tract with mild nonshadowing gastric ingesta-consistent with food/chyme.
- Age-related renal changes.

INTERPRETATION OF THE FINDINGS & FURTHER RECOMMENDATIONS

No evidence of definitive pathology as an obvious cause of hemolytic anemia. The spleen may indicate hyperplasia or hematopoiesis given anemia, inflammation, while potential for occult splenic neoplasia is not definitively excluded. Depending upon degree of anemia and if normal clotting status, screening splenic FNA cytology using a 25-gauge needle could be considered for further clarification. Correlation with hepatic enzyme assessment with hepatosupportive medications if evidence of cholestatic hepatopathy is recommended.

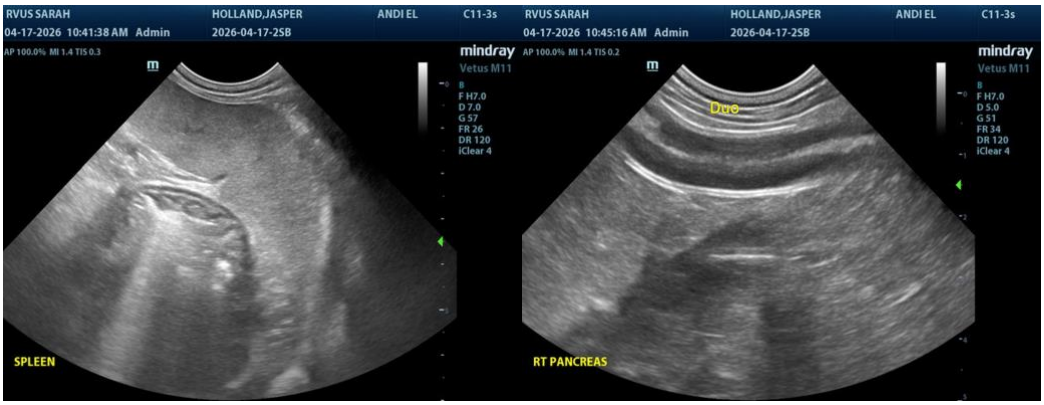

SonoPath

FOSTERING THE ART OF VETERINARY MEDICINE™

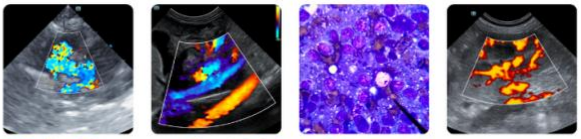

Clinical Sonography & Telecytology

Educational Teleconsultation Services™

SonoPath.com info@sonopath.com 1.800.838.4268

PATIENT

Jasper Holland

SPECIES

Canine

BREED

Poodle Mix

SEX

Neutered Male

AGE

11 Years

WEIGHT

9.1 kg

INTERPRETED BY

R. McKenzie Daniel, DVM, DABVP (Canine / Feline Practice)

IMAGING PERFORMED BY

Dr. Sarah Barthelemy

HOSPITAL NAME

Woodlands Vet

REFERRING VET

Dr. Nagy

INVOICE

15209

DATE

04/17/26

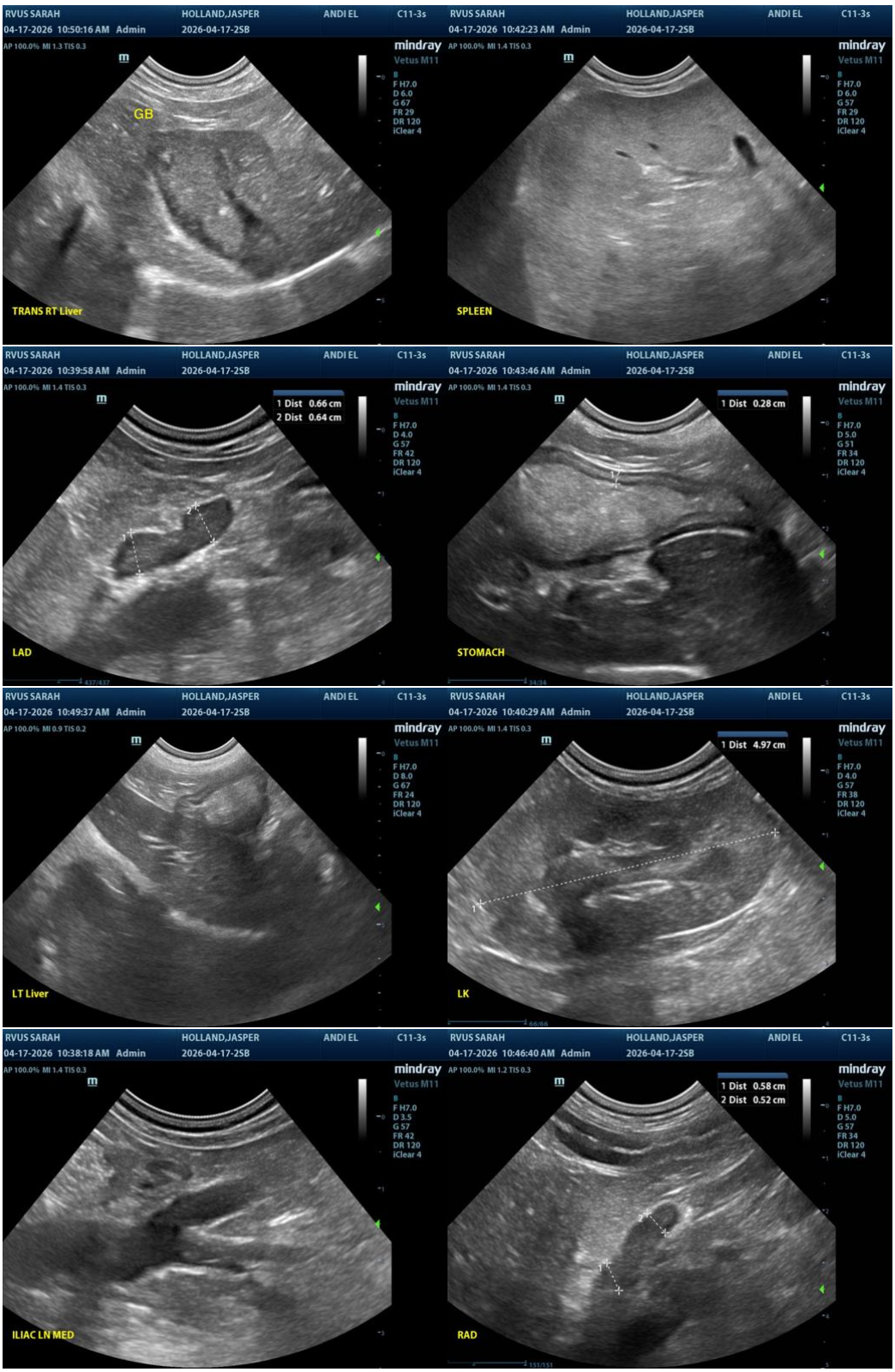

PATIENT

Jasper Holland

SPECIES

Canine

BREED

Poodle Mix

SEX

Neutered Male

AGE

11 Years

WEIGHT

9.1 kg

INTERPRETED BY

R. McKenzie Daniel, DVM, DABVP (Canine / Feline Practice)

IMAGING PERFORMED BY

Dr. Sarah Barthelemy

HOSPITAL NAME

Woodlands Vet

REFERRING VET

Dr. Nagy

INVOICE

15209

DATE

04/17/26

The information and recommendations provided are based on the images presented by the referring veterinarian/sonographer. No evaluation can be communicated regarding pathology that was not visible in the image/video clips provided.

Thank you for this referral. If the clinical or image interpretation does not parallel your findings or if I can be of any further assistance, please contact me.

R. McKenzie Daniel, DVM, DABVP (Canine / Feline Practice)

info@SonoPath.com