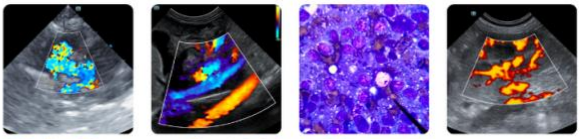

PATIENT

Birdie Sullivan

SPECIES

Feline

BREED

DLH

SEX

Spayed Female

AGE

8 Years

WEIGHT

15.28 pounds

INTERPRETED BY

R. McKenzie Daniel, DVM, DABVP (Canine / Feline Practice)

IMAGING PERFORMED BY

Christa Williams DVM, DABVP

HOSPITAL NAME

Caravan Vet

REFERRING VET

Christa Williams DVM, DABVP

INVOICE

15212

DATE

04/17/26

PRESENTING CLINICAL SIGNS

Cat has progressive ALP elevation. We first saw Birdie in December, and labs showed ALP 62, all other chemistry values normal. T4 was 6.7, so hyperthyroidism was presumed to be the cause of the elevated ALP. She was started on Methimazole. At her recheck in February, T4 was 1.8, but ALP was 88. A liver enzyme recheck in early April showed ALP 91. Abdominal US and a GI panel were recommended to further evaluate the persistent and increasing elevation. FNA of liver submitted for review. Cat has a good appetite and energy level. She is vomiting about once a week.

Abnormal PE/Chem/CBC/UA Results: Normal exam, GI Panel pending.

ULTRASONOGRAPHIC EXAMINATION OF THE ABDOMEN

Urinary System

The urinary bladder, trigone, cystourethral junction, and visible pelvic urethra to a depth of 3.0 cm exhibited normal thickness and tone. Anechoic urine was present in the lumen with no uroliths or sediment. The ureteral papillae were normal. The ureters were not visible which is normal. No evidence of inflammatory or neoplastic change were noted.

Normal size and margination was present in the kidneys. A normal 1:3 cortex / medulla ratio and normal corticomedullary definition were maintained. The echogenicity of the cortex was similar to or slightly less than normal liver parenchyma while the medulla echogenicity was hypoechoic to the cortex with no evidence of pelvic dilation. The left kidney measured 3.5 cm in length. The right kidney measured 3.9 cm in length.

Adrenal Glands

The left adrenal gland was uniform in size and contour with a uniformly hypoechoic parenchyma. The left adrenal gland measured 0.40 cm width.

The right adrenal gland was uniform in size and contour with a uniformly hypoechoic parenchyma. The right adrenal gland measured 0.46 cm width.

Spleen

The spleen exhibited a finely textured and homogenous parenchyma which was hyperechoic to the liver and renal cortical parenchyma. The capsule was smooth and regular without apparent expansion. The splenic vasculature at the hilus was normal in volume with no evidence of congestion or thrombosis. Acute to chronic inflammatory, neoplastic, or benign parenchyma changes were not noted. The spleen measured 0.95 cm width level of the mid spleen.

Liver & Gallbladder

The liver was subjectively normal in size, structure, and contour. The liver parenchyma was uniform and hypoechoic to the spleen with a mild coarse echotexture. The hepatic and portal vasculature were normal in appearance without signs of congestion.

The gallbladder was non-distended in size with thin walls and primarily anechoic luminal content. The cystic and common bile ducts were normal.

Gastrointestinal

PATIENT

Birdie Sullivan

SPECIES

Feline

BREED

DLH

SEX

Spayed Female

AGE

8 Years

WEIGHT

15.28 pounds

INTERPRETED BY

R. McKenzie Daniel, DVM, DABVP (Canine / Feline Practice)

IMAGING PERFORMED BY

Christa Williams DVM, DABVP

HOSPITAL NAME

Caravan Vet

REFERRING VET

Christa Williams DVM, DABVP

INVOICE

15212

DATE

04/17/26

The stomach presented intact wall layering with a normal wall layer ratio. The lumen of the stomach was empty with no signs of ileus, obstruction or foreign material.

The small intestine presented intact wall layering with 1:3 muscularis/mucosa ratio. The lumen of the small intestine was empty with no signs of ileus, obstruction or foreign material.

Normal visible colon wall layers were present with apparent formed feces in lumen.

Pancreas

The parenchyma of the right pancreas was nonhomogenous and hyperechoic to adjacent omental fat with diffuse parenchyma remodeling. The capsule of the pancreas was mildly asymmetrical in contour without evidence of peripancreatic inflammation. These changes may suggest chronic inflammation, fibrosis, or saponification if previous history of pancreatitis. No overt signs of pancreatic neoplasia. The area of the left pancreas was sonographically unremarkable.

Free Abdomen

No overt lymphadenopathy or peritoneal effusion was present.

ULTRASONOGRAPHIC FINDINGS

- Sonographically normal liver/gallbladder- consistent with mild benign hepatopathy.
- Suspect right limb pancreatitis/fibrosis.
- Sonographically normal gastrointestinal tract.

INTERPRETATION OF THE FINDINGS & FURTHER RECOMMENDATIONS

Correlation with pending GI panel is recommended. A definitive cause of the elevated liver enzyme was not obvious without evidence of sonographic hepatobiliary pathology.

Assuming normal clotting status using a 25-gauge needle, hepatic FNA cytology could be considered for further clarification. Otherwise, as needed gastrointestinal support and empirical therapy for suspect chronic pancreatitis and hepatosupportive medications with clinical monitoring is recommended.

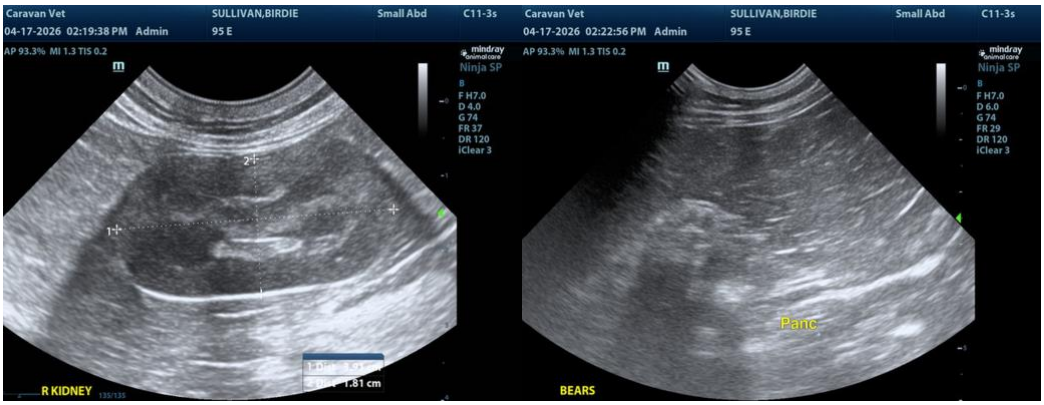

SonoPath
FOSTERING THE ART OF VETERINARY MEDICINE™

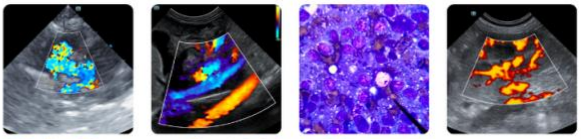

Clinical Sonography & Telecytology
Educational Teleconsultation Services™

SonoPath.com info@sonopath.com 1.800.838.4268

PATIENT

Birdie Sullivan

SPECIES

Feline

BREED

DLH

SEX

Spayed Female

AGE

8 Years

WEIGHT

15.28 pounds

INTERPRETED BY

R. McKenzie Daniel, DVM, DABVP (Canine / Feline Practice)

IMAGING PERFORMED BY

Christa Williams DVM, DABVP

HOSPITAL NAME

Caravan Vet

REFERRING VET

Christa Williams DVM, DABVP

INVOICE

15212

DATE

04/17/26

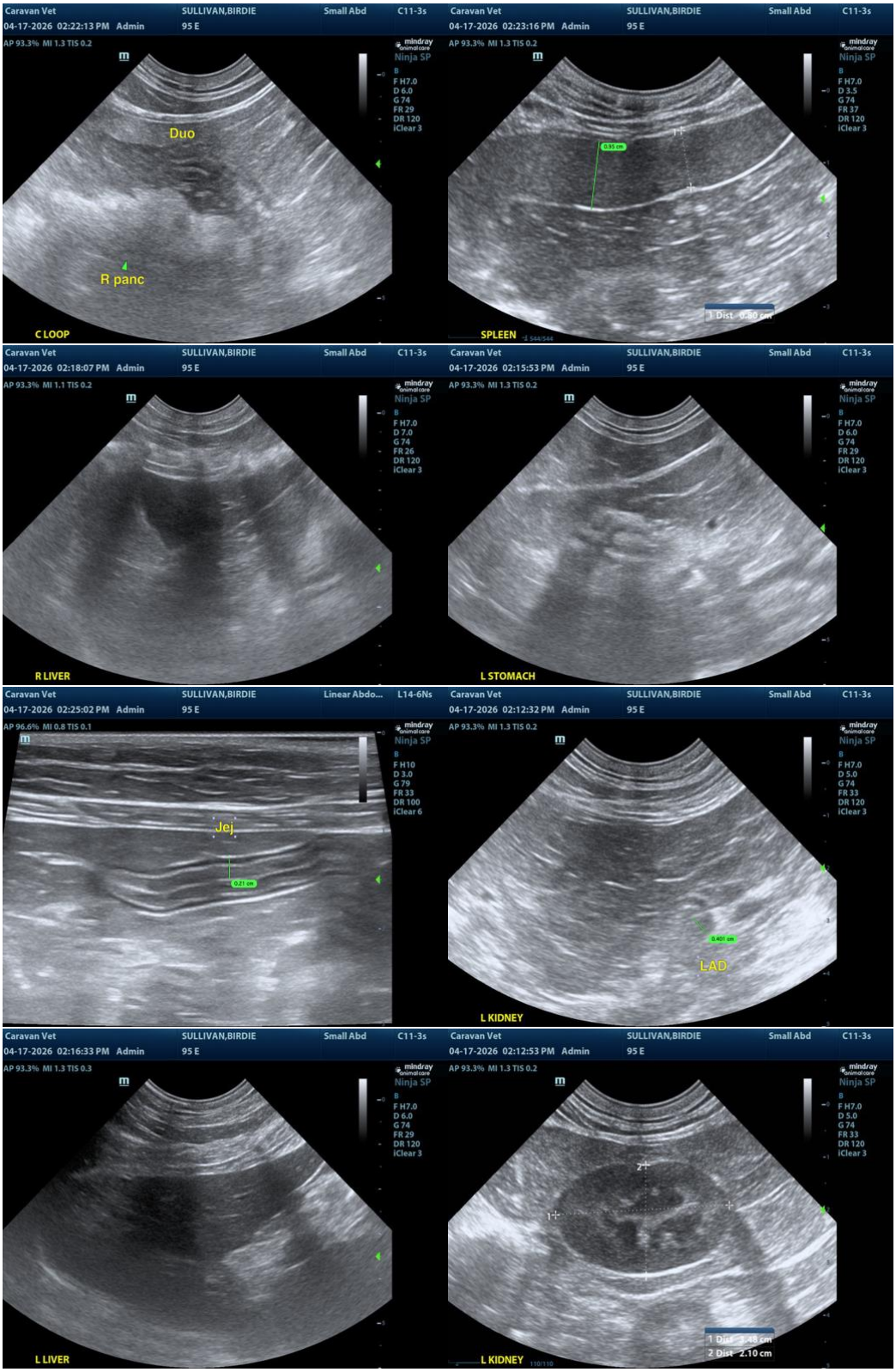

SonoPath
FOSTERING THE ART OF VETERINARY MEDICINE™

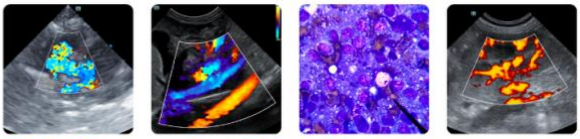

Clinical Sonography & Telecytology
Educational Teleconsultation Services™

SonoPath.com info@sonopath.com 1.800.838.4268

PATIENT

Birdie Sullivan

SPECIES

Feline

BREED

DLH

SEX

Spayed Female

AGE

8 Years

WEIGHT

15.28 pounds

INTERPRETED BY

R. McKenzie Daniel, DVM, DABVP (Canine / Feline Practice)

IMAGING PERFORMED BY

Christa Williams DVM, DABVP

HOSPITAL NAME

Caravan Vet

REFERRING VET

Christa Williams DVM, DABVP

INVOICE

15212

DATE

04/17/26

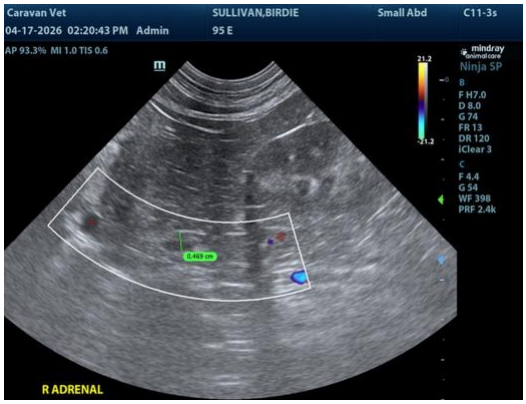

The information and recommendations provided are based on the images presented by the referring veterinarian/sonographer. No evaluation can be communicated regarding pathology that was not visible in the image/video clips provided.

Thank you for this referral. If the clinical or image interpretation does not parallel your findings or if I can be of any further assistance, please contact me.

R. McKenzie Daniel, DVM, DABVP (Canine / Feline Practice)

info@SonoPath.com