



**PATIENT PRESENTING CLINICAL SIGNS**

Chloe Amoroso History: Enlarged heart

**SPECIES** Abnormal PE/Chem/CBC/UA Results: BUN creat 34H, Amylase 278L, PLT 551H

Canine **ULTRASONOGRAPHIC EXAMINATION OF THE HEART**

**BREED**

Maltese

**SEX**

Female Spayed

**AGE**

11y

**WEIGHT**

5.8 lbs

**INTERPRETED BY**

R. McKenzie Daniel,  
DVM, DABVP  
(Canine and Feline)

CANINE CARDIAC PARAMETERS	MR VMAX (m/s)	TR VMAX (m/s)	LA/AO (M-Mode)	LA/AO (Heart Base; Swe)	FS (%)	EF (%)	EPSS (cm)
NORMAL PARAMETER	4.5-5.5	<2.7	1.3	Up to 1.6	28-40	40-100	<0.6
PATIENT	5.8	--	--	1.7	48	81	0.1
CANINE CARDIAC PARAMETERS	HR (BPM)	AV VMAX (m/s)	PV MAX (m/s)	BODY WEIGHT (kg)	LAD LA MAX 4 Chamber	LVIDd Avg; 2D and m-mode short axis (cm)	LVIDs Avg; 2D and m-mode short axis (cm)
NORMAL PARAMETER	50-100	0.7-1.7	0.7-1.6				
PATIENT	NM	1.2	0.8	--	2.8	2.5	--

**Cardiac Presentation**

The echocardiogram in this patient demonstrated mild increased **left atrial** size based on 2 different LA measurement methods with early intra atrial septal deviation. The cranial and caudal **mitral** valve leaflets presented thickening consistent with endocardiosis and valvular prolapse. Doppler indicated moderate eccentric to significant MR insufficiency noted on doppler. MR velocity measured 5.8 m/s. The **left ventricle** presented mild increased dimension. The **myocardium** presented normal echogenicity without subjective evidence of significant fibrotic or ischemic disease. **Contractility** of the ventricular walls was adequate and in normal range for this patient evidenced by the fractional shortening measurement and subjective evaluation of the different regions of the myocardium. The **left ventricular outflow** tract demonstrated normal laminar flow and subjective structural integrity. The **right atrium** and auricle revealed normal size, structure and content. No evidence of masses was noted or chamber overload. **Tricuspid** valvular assessment demonstrated adequate linear morphology. The **right ventricle** was of normal size (1/3 diameter of LV), chordae structure, myocardial echogenicity and thickness. **Pulmonic** tract assessment revealed normal valve structure, laminar flow, and diameter (approx.1:1 pa/ao ratio). No visible **pericardial** or free pleura fluid was noted. No echographically detectable evidence of cardiac / pericardial tumors was visible.

**ULTRASONOGRAPHIC FINDINGS**

- Chronic mitral valve disease with valve prolapse (B2)

**INVOICE**

13413

**DATE**

4/16/26

Becca Hamilton

**HOSPITAL NAME**

Companion AH  
Parsippany

**REFERRING VET**

Dr. Tsai



**PATIENT**

Chloe Amoroso

**SPECIES**

Canine

**BREED**

Maltese

**SEX**

Female Spayed

**AGE**

11y

**WEIGHT**

5.8 lbs

**INTERPRETED BY**

R. McKenzie Daniel,  
 DVM, DABVP  
 (Canine and Feline)

**IMAGING PERFORMED BY**

Becca Hamilton

**HOSPITAL NAME**

Companion AH  
 Parsippany

**REFERRING VET**

Dr. Tsai

**INVOICE**

13413

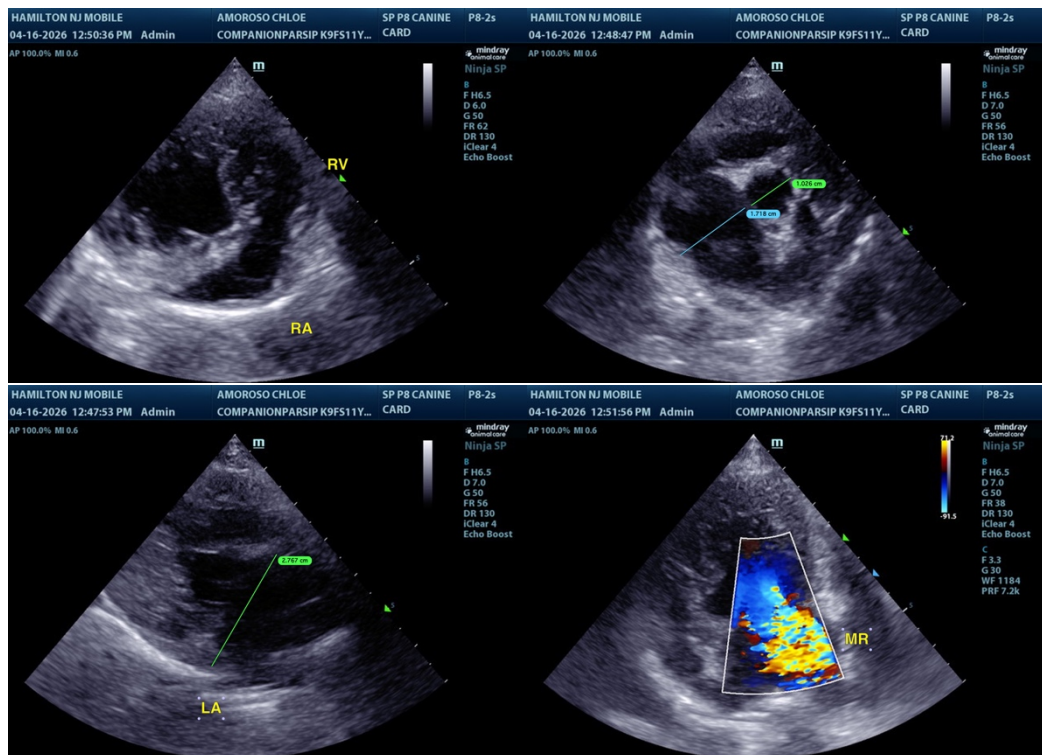
**DATE**

4/16/26

**INTERPRETATION OF THE FINDINGS & FURTHER RECOMMENDATIONS**

The cause of the murmur is chronic degenerative valvular changes with secondary eccentric mitral valve insufficiency. The left atrial enlargement implies that the risk of complication secondary to mitral valve insufficiency is elevated, yet overall, the heart appears stable. No other clinical issues such as LV systolic dysfunction or clinical pulmonary hypertension. Pimobendan 0.3 mg/kg BID is recommended. No overt indication for additional medication. Prognosis is considered variable and sonographic monitoring is recommended. Recheck echo cardiogram is suggested in 6 months, sooner if clinical signs arise.

Anesthetic risk is mild yet likely mildly reduced once on Pimobendan for 3-5 days. If required, the following protocol is suggested. Suggested anesthetic protocol may include opioid or Benzodiazepine pre-med, induction with Propofol or Alfaxalone, and appropriate gas anesthesia with avoidance of alpha 2 agonists.





**PATIENT**

Chloe Amoroso

**SPECIES**

Canine

**BREED**

Maltese

**SEX**

Female Spayed

**AGE**

11y

**WEIGHT**

5.8 lbs

**INTERPRETED BY**

R. McKenzie Daniel,  
DVM, DABVP  
(Canine and Feline)

**IMAGING PERFORMED BY**

Becca Hamilton

**HOSPITAL NAME**

Companion AH  
Parsippany

**REFERRING VET**

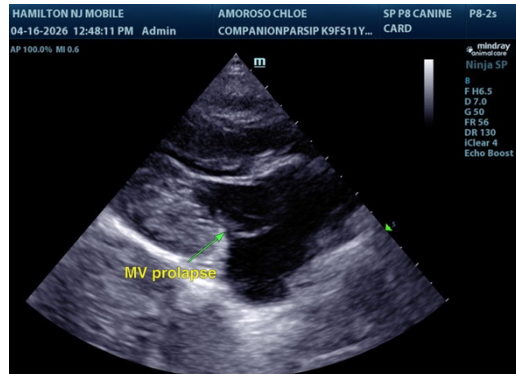
Dr. Tsai

**INVOICE**

13413

**DATE**

4/16/26



The information and recommendations provided are based on the images presented by the referring veterinarian/sonographer. No evaluation can be communicated regarding pathology that was not visible in the image/video clips provided.

Thank you for this referral. If the clinical or image interpretation does not parallel your findings or if I can be of any further assistance, please contact me.

R. McKenzie Daniel, DVM, DABVP (Canine / Feline Practice)

[info@sonopath.com](mailto:info@sonopath.com)