



**PATIENT PRESENTING CLINICAL SIGNS**

Luna Galeana History: 3 lumps removed 2 lipomas and one mast cell tumour. Metastasis check  
Abnormal PE/Chem/CBC/UA Results: None

**SPECIES ULTRASONOGRAPHIC EXAMINATION OF THE ABDOMEN**

Canine

**Urinary System**

**BREED** The urinary bladder, trigone, cystourethral junction, and visible pelvic urethra to a depth of 3 cm exhibited normal thickness and tone. Anechoic urine was present in the lumen with no uroliths or sediment. The ureteral papillae were normal. The ureters were not visible which is normal. No evidence of inflammatory or neoplastic changes were noted.

Beagle

**SEX**

Spayed female

Normal size and margination were present in the kidneys. A normal 1:3 cortex / medulla ratio and normal corticomedullary definition were maintained. The echogenicity of the cortex was similar to or slightly less than normal liver parenchyma while the medulla echogenicity was hypoechoic to the cortex with no evidence of pelvic dilation. The left kidney measured 4.5 cm in length. The right kidney measured 4.5 cm in length.

**AGE**

6 years

The area of the aortic trifurcation was free of pathology.

**Adrenal Glands**

**WEIGHT**

14kg

The left adrenal gland was uniform in size and contour with a uniformly hypoechoic parenchyma. The left adrenal gland measured 0.45 cm width at the caudal pole and 0.38 cm width at the cranial pole. The right adrenal gland was uniform in size and contour with a uniformly hypoechoic parenchyma. The right adrenal gland measured 0.43 cm width at the caudal pole and 0.37 cm width at the cranial pole.

**INTERPRETED BY**

R. McKenzie Daniel,  
DVM, DABVP  
(Canine and Feline)

**Spleen**

The spleen exhibited a finely textured and homogenous parenchyma which was hyperechoic to the liver and renal cortical parenchyma. The capsule was smooth and regular without apparent expansion. The splenic vasculature at the hilus was normal in volume with no evidence of congestion or thrombosis. Acute to chronic inflammatory, neoplastic, or benign parenchyma changes were not noted.

**IMAGING PERFORMED BY**

Dr. Belan

**Liver**

**HOSPITAL NAME**

South Point AH

The liver was subjectively normal in size, structure, and contour. The liver parenchyma was uniform and hypoechoic to the spleen with a mild coarse echotexture. The hepatic and portal vasculature were normal in appearance without signs of congestion. The gallbladder was non-distended in size with thin walls and primarily anechoic luminal content with minor nondependent luminal sludge. The cystic and common bile ducts were normal.

**REFERRING VET**

Dr. Callan

**Gastrointestinal**

The stomach presented intact wall layering with a normal wall layer ratio. The lumen of the stomach contained minor nonshadowing ingesta/chyme with no signs of ileus, obstruction or foreign material.

**INVOICE**

10377ag

The small intestine presented intact wall layering with 1:3 muscularis/mucosa ratio. The lumen of the small intestine was empty with no signs of ileus, obstruction or foreign material.

Normal visible colon wall layers were present with apparent formed feces in lumen.

**DATE**

04/15/2022

**Pancreas**



**PATIENT**

Luna Galeana

The parenchyma of the left limb, body and right limb of the pancreas presented isoechoic to the adjacent omental fat. A normal curvilinear capsule contour of the pancreas was present. The visible pancreatic duct was normal. No signs of active inflammation or neoplastic disease was evident.

**SPECIES**

Canine

**Free Abdomen**

No omental masses, overt lymphadenopathy or peritoneal effusion was present.

**BREED**

Beagle

**ULTRASONOGRAPHIC FINDINGS**

- Sonographically unremarkable abdomen.

**SEX**

Spayed female

**INTERPRETATION OF THE FINDINGS & FURTHER RECOMMENDATIONS**

No evidence of intra-abdominal primary or neoplastic disease. Sonographic monitoring of the abdomen based on oncology consult is recommended.

**AGE**

6 years

**WEIGHT**

14kg

**INTERPRETED BY**

R. McKenzie Daniel,  
DVM, DABVP  
(Canine and Feline)

**IMAGING PERFORMED BY**

Dr. Belan

**HOSPITAL NAME**

South Point AH

**REFERRING VET**

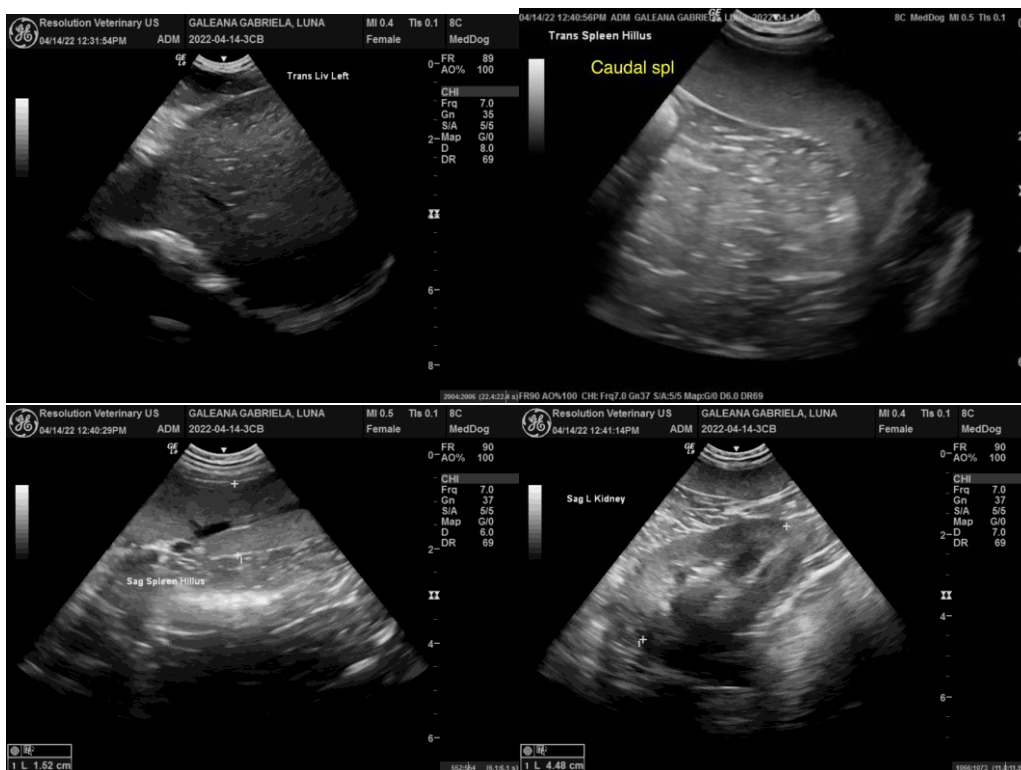
Dr. Callan

**INVOICE**

10377ag

**DATE**

04/15/2022





**PATIENT**

Luna Galeana

**SPECIES**

Canine

**BREED**

Beagle

**SEX**

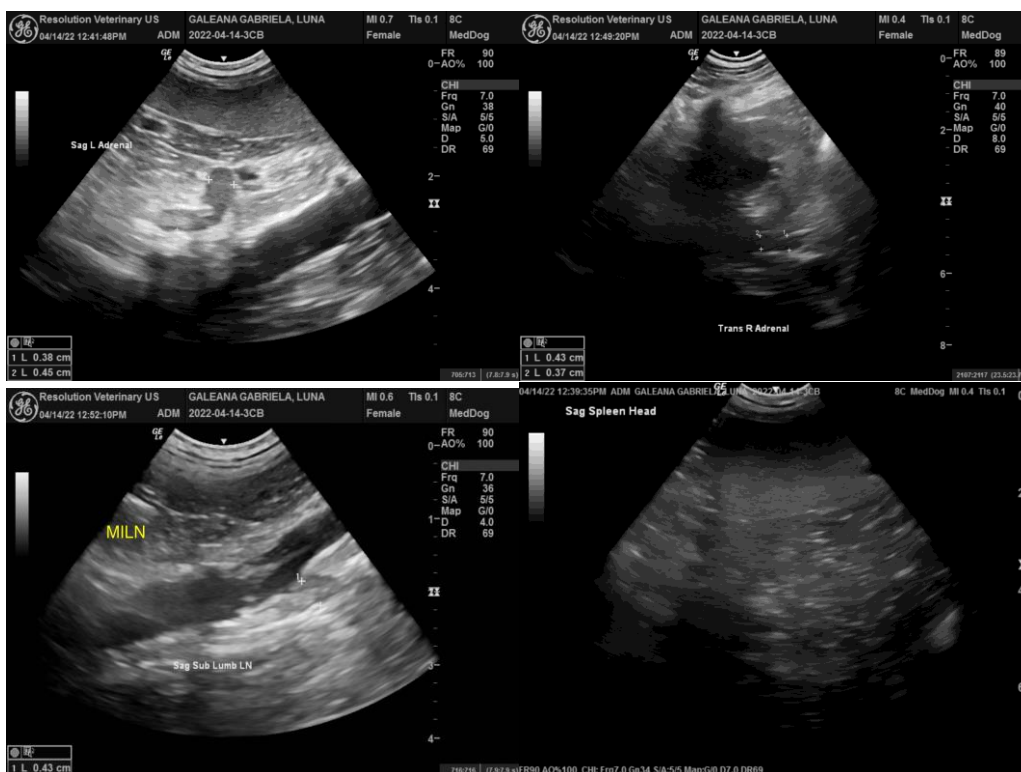
Spayed female

**AGE**

6 years

**WEIGHT**

14kg



**INTERPRETED BY**

R. McKenzie Daniel,  
DVM, DABVP  
(Canine and Feline)

**IMAGING PERFORMED BY**

Dr. Belan

**HOSPITAL NAME**

South Point AH

**REFERRING VET**

Dr. Callan

**INVOICE**

10377ag

**DATE**

04/15/2022

The information and recommendations provided are based on the images presented by the referring veterinarian/sonographer. No evaluation can be communicated regarding pathology that was not visible in the image/video clips provided.

Thank you for this referral. If the clinical or image interpretation does not parallel your findings or if I can be of any further assistance please contact me.

R. McKenzie Daniel, DVM, DABVP (Canine / Feline Practice)

info@SonoPath.com