

**PATIENT PRESENTING CLINICAL SIGNS**

Sweet Pea Anderson

**SPECIES**

Canine

**BREED**

Pug

**SEX**

FS

**AGE**

10yr

**WEIGHT**

20.20lb

**INTERPRETED BY**

R. McKenzie Daniel,  
DVM, DABVP  
(Canine and Feline)

Coughing for the past 2-3 weeks, and wheezing since 3 days ago. Normal appetite and energy level. Mild yellow-green nasal discharge from both nares for the past 2 days. Intermittent hacking/wheezing cough in exam room. Loud referred upper airway noise throughout lung fields. Mild thin yellow nasal discharge bilateral nares. HR: 140, RR: 80-100 (panting), T: 100.4, CRT <2 seconds. No murmur/arrhythmia auscultated. Femoral pulses strong and synchronous. Became cyanotic and developed respiratory distress during RG despite sedation Radiographic Findings 1. Mild generalized cardiomegaly may be due to mitral and tricuspid valve endocardiosis. Other differentials for the mild right-sided enlargement would include early pulmonary hypertension related to underlying chronic inflammatory lower airway disease, less likely heartworm disease or thromboembolic disease. No evidence of cardiogenic pulmonary edema. Recommend an echocardiogram for further assessment of this finding. 2. Diffuse bronchointerstitial lung pattern. This may due to underlying chronic active bronchitis, pulmonary fibrosis or infectious bronchitis. The interstitial component is likely compounded by expiration. Lower airway sampling can be performed for further evaluation. 3. Ill-defined region of increased radiopacity superimposed with the cardiac silhouette on the right lateral and caudal subsegment of the caudal subsegment of the left cranial lung lobe on the VD radiograph. Again this may be compounded by expiration and atelectasis however given the history an early focus of pneumonia cannot be ruled out. Antibiotic therapy would therefore be recommended in this patient with repeat thoracic radiographic evaluation with in 5 to 7 days or sooner if clinically indicated. 4. Mild hepatomegaly may be due to a vacuolar hepatopathy however other differential such as hepatitis body congestion or less likely neoplasia cannot be excluded. Abdominal ultrasound could be performed for further assessment of this finding if clinically indicated. 5. Mild splenomegaly may be due to EMH, congestion, lymphoid hyperplasia or neoplasia. Abdominal ultrasound can be performed to further assess this finding. Primary Question/Differential to Be Answered in This Exam Evaluate cardiomegaly and respiratory distress. Evaluate mild hepatomegaly and splenomegaly.

**IMAGING PERFORMED BY**

Jenna Walsh CVT

**HOSPITAL NAME**

West Eugene AH

**REFERRING VET**

Dr. Powers

**INVOICE**

13472ag

**DATE**

04/14/2023

**ULTRASONOGRAPHIC EXAMINATION OF THE ABDOMEN AND HEART**

CANINE CARDIAC PARAMETERS	MR VMAX (m/s)	TR VMAX (m/s)	LA/AO (Boon method)	LA/AO (Heart Base; Swe)	FS (%)	EF (%)	EPSS (cm)
NORMAL PARAMETER	4.5-5.5	<2.7	1.3	<1.3	28-40	40-100	<0.6
PATIENT		1.6		1.36	51	85	0.1
CANINE CARDIAC PARAMETERS	HR (BPM)	AV VMAX (m/s)	PV MAX (m/s)	BODY WEIGHT (kg)	LA 2D short axis Base view (cm)	LVIDd Avg; 2D and m-mode short axis (cm)	LVIDs Avg; 2D and m-mode short axis (cm)
NORMAL PARAMETER	50-100	0.7-1.7	0.7-1.6				
PATIENT	144	1.4	1.1		2.8	2.5	



**PATIENT**

Sweet Pea Anderson

**SPECIES**

Canine

**BREED**

Pug

**SEX**

FS

**AGE**

10yr

**WEIGHT**

20.20lb

**INTERPRETED BY**

R. McKenzie Daniel,  
DVM, DABVP  
(Canine and Feline)

**IMAGING PERFORMED BY**

Jenna Walsh CVT

**HOSPITAL NAME**

West Eugene AH

**REFERRING VET**

Dr. Powers

**INVOICE**

13472ag

**DATE**

04/14/2023

**Cardiac Presentation**

The echocardiogram in this patient demonstrated normal left atrial size based on 3 separate methods of LA evaluation. The cranial and caudal mitral valve leaflets presented normal linear structure, extension in systole, and union in diastole with normal kinesis. Mild MR was present on Doppler. The left ventricle presented thicknesses with linear contour and was not dilated nor restricted. The myocardium presented normal echogenicity without subjective evidence of significant fibrotic or ischemic disease. Contractility of the ventricular walls was adequate and in normal range for this patient evidenced by the fractional shortening measurement and subjective evaluation of the different regions of the myocardium. The left ventricular outflow tract demonstrated normal laminar flow and subjective structural integrity. Normal measured LVOT velocity. The right atrium and auricle revealed normal size, structure and content. No evidence of masses was noted. Tricuspid valvular assessment demonstrated adequate linear morphology and kinesis. Minor TR was present on Doppler. The right ventricle was of normal size (1/3 diameter of LV), chordae structure, myocardial echogenicity and thickness. Pulmonary outflow tract assessment revealed normal valve structure, laminar flow, and diameter (approx. 1:1 pa/ao ratio). Normal measured RVOT velocity. No visible pericardial or free pleural fluid was noted. The cranial mediastinum and pericardial and extra-cardiac regions were free of masses in the visible window.

**Urinary System**

The urinary bladder, trigone, cystourethral junction, and visible pelvic urethra to a depth of 3 cm exhibited normal thickness and tone. Anechoic urine was present in the lumen with mild non-dependent particulate sediment. The ureteral papillae were normal. The ureters were not visible which is normal. No evidence of inflammatory or neoplastic changes were noted.

Normal size and margination were present in the kidneys. A normal 1:3 cortex / medulla ratio was maintained. The medulla and cortices were uniform in texture with some increased echogenicity and mild to moderate loss of corticomedullary symmetry and definition expected for the age of the patient. No evidence of pelvic dilation was present. Bilateral mild non-obstructive medullary mineral was present. The left kidney measured 3.9 cm in length. The right kidney measured 4.7 cm in length.

The area of the aortic trifurcation was free of pathology.

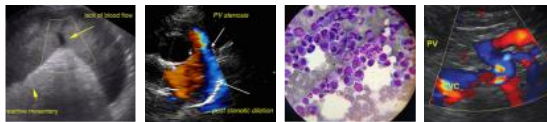
**Adrenal Glands**

The left adrenal gland was uniform in size and contour with a uniformly hypoechoic parenchyma. The left adrenal gland measured 0.48 cm width at the caudal pole and 2.2 cm length.

The right adrenal gland was indistinctly enlarged in size with areas of capsule asymmetry yet subjective maintained capsule integrity. Variably sized echogenic nodular changes were present with a mid to cranial right adrenal nodule measuring 1.8 cm x 1.8 cm. The right adrenal gland overall measured 1.8 cm width at the caudal pole and 2.9 cm length.

**Spleen**

The spleen exhibited a finely textured and homogenous parenchyma which was hyperechoic to the liver and renal cortical parenchyma. The capsule was smooth and regular without apparent expansion. The splenic vasculature at the hilus was normal in volume with no evidence of congestion or



<b>PATIENT</b>	thrombosis. Acute to chronic inflammatory, neoplastic, or benign parenchyma changes were not noted.
Sweet Pea Anderson	
<b>SPECIES</b>	<b>Liver/Gallbladder</b>
Canine	The liver exhibited moderate enlargement with symmetrical capsule contour and generalized mild non-homogenous increased parenchymal echogenicity. No masses or nodules noted. The hepatic and portal vasculature were normal in appearance without signs of congestion. The gallbladder was non-distended in size with thin walls and primarily anechoic luminal content. The cystic and common bile ducts were normal.
<b>BREED</b>	<b>Gastrointestinal</b>
Pug	
<b>SEX</b>	The stomach presented intact wall layering with a normal wall layer ratio. The lumen of the stomach was empty with no signs of ileus, obstruction or foreign material.
FS	
<b>AGE</b>	The small intestine presented intact wall layering with 1:3 muscularis/mucosa ratio. The lumen of the small intestine was empty with no signs of ileus, obstruction or foreign material.
10yr	Normal visible colon wall layers were present with apparent formed feces in lumen.
<b>WEIGHT</b>	<b>Pancreas</b>
20.20lb	The pancreas was normal in size and contour with isoechoic to heterogeneous parenchyma compared to adjacent omentum, likely consistent with age related changes and considered incidental. No signs of active inflammation or neoplasia.
<b>INTERPRETED BY</b>	<b>Free Abdomen</b>
R. McKenzie Daniel, DVM, DABVP (Canine and Feline)	No omental masses, overt lymphadenopathy or peritoneal effusion was present.
<b>IMAGING PERFORMED BY</b>	<b>ULTRASONOGRAPHIC FINDINGS</b>
Jenna Walsh CVT	<ul style="list-style-type: none"><li>• Normal echocardiogram with minor MR/TR.</li><li>• Urinary bladder sediment.</li><li>• Normal spleen.</li><li>• Chronic renal changes with non-obstructive medullary mineral.</li><li>• Non-specific subjective benign hepatopathy.</li><li>• Irregular/nodular right adrenomegaly.</li></ul>
<b>HOSPITAL NAME</b>	<b>INTERPRETATION OF THE FINDINGS &amp; FURTHER RECOMMENDATIONS</b>
West Eugene AH	
<b>REFERRING VET</b>	No evidence of structural or functional cardiomyopathy was present in this study including no evidence of clinical pulmonary hypertension as a contributing factor to the patient's respiratory abnormalities.
Dr. Powers	
<b>INVOICE</b>	Assessment of hepatic enzyme levels +/- hepatic FNA for screening cytology could be considered for further assessment.
13472ag	
<b>DATE</b>	The right adrenal gland may indicate functional vs non-functional adenomatous change or benign hyperplasia while the possibility of emerging neoplasia i.e., pheochromocytoma is possible. A screening BP is advised to assess for evidence of hypertension which may allude to emerging adrenal neoplastic criteria i.e., pheochromocytoma. Sonographic monitoring of the right adrenal gland with initial recheck
04/14/2023	



**PATIENT**

in 4-6 weeks +/- abdominal CT for further clarification is recommended.

Sweet Pea Anderson

**SPECIES**

Canine

**BREED**

Pug

**SEX**

FS

**AGE**

10yr

**WEIGHT**

20.20lb

**INTERPRETED BY**

R. McKenzie Daniel,  
DVM, DABVP  
(Canine and Feline)

**IMAGING PERFORMED BY**

Jenna Walsh CVT

**HOSPITAL NAME**

West Eugene AH

**REFERRING VET**

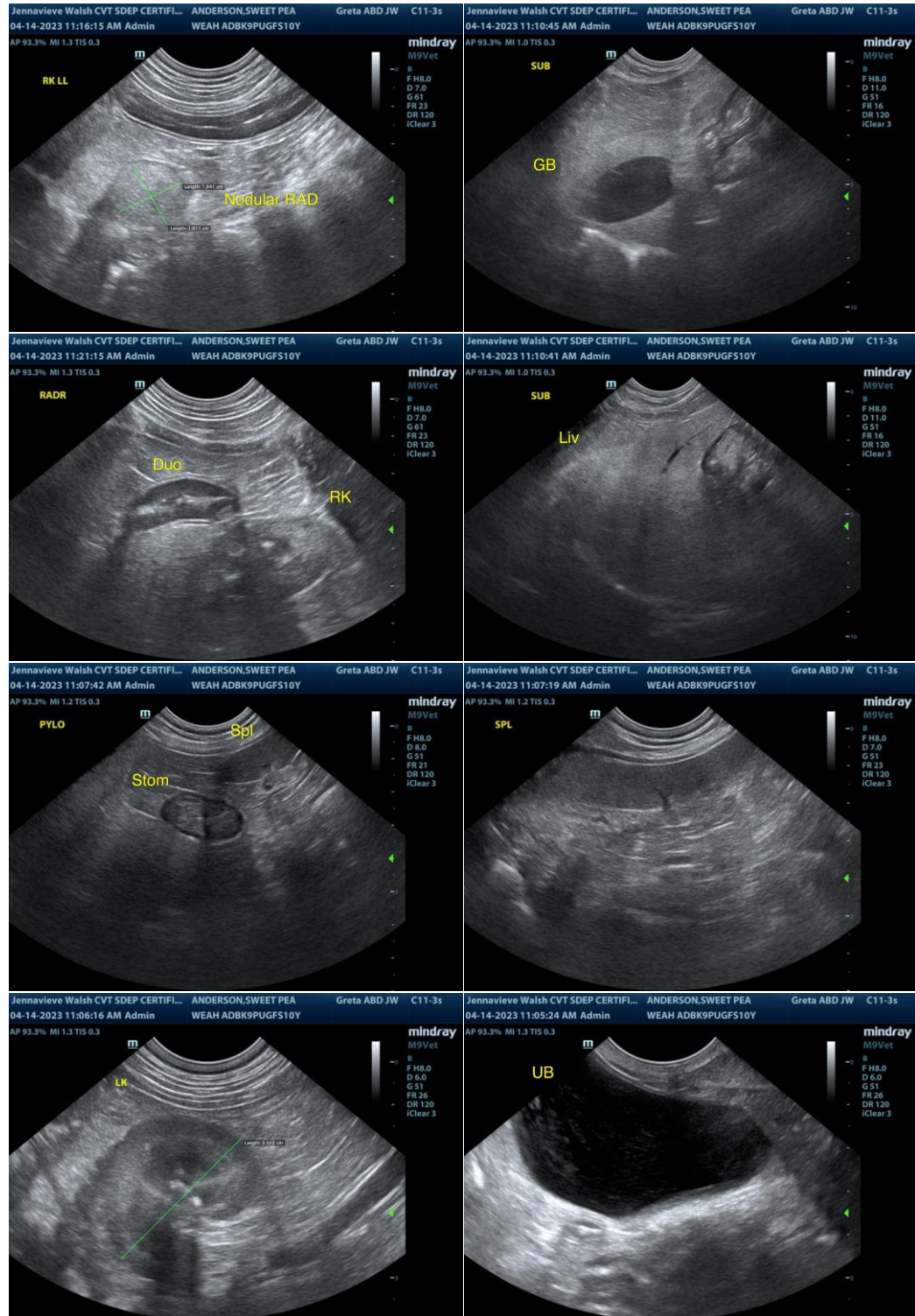
Dr. Powers

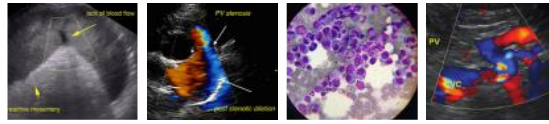
**INVOICE**

13472ag

**DATE**

04/14/2023





**PATIENT**

Sweet Pea Anderson

**SPECIES**

Canine

**BREED**

Pug

**SEX**

FS

**AGE**

10yr

**WEIGHT**

20.20lb

**INTERPRETED BY**

R. McKenzie Daniel,  
DVM, DABVP  
(Canine and Feline)

**IMAGING PERFORMED BY**

Jenna Walsh CVT

**HOSPITAL NAME**

West Eugene AH

**REFERRING VET**

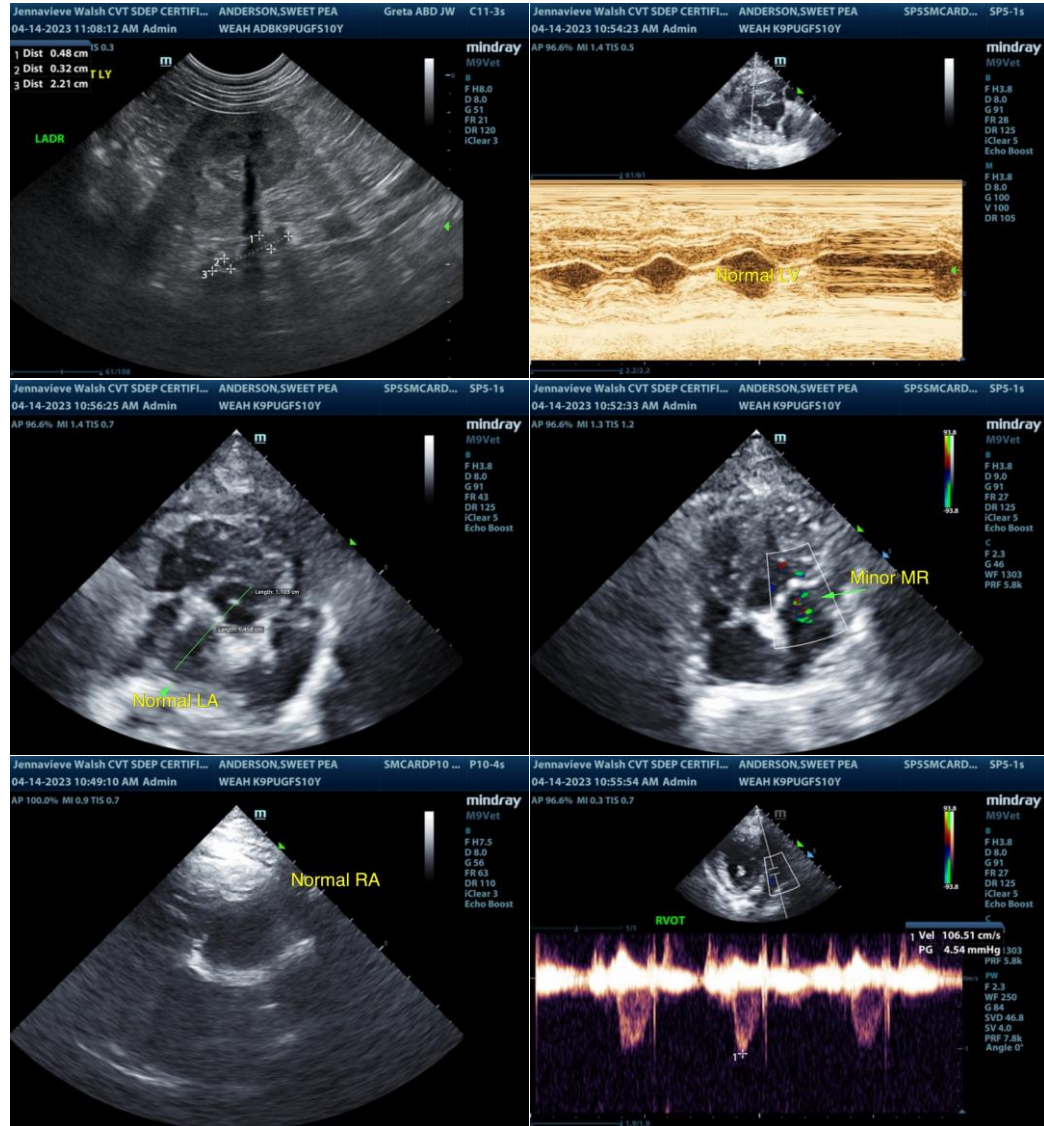
Dr. Powers

**INVOICE**

13472ag

**DATE**

04/14/2023



The information and recommendations provided are based on the images presented by the referring veterinarian/sonographer. No evaluation can be communicated regarding pathology that was not visible in the image/video clips provided.

Thank you for this referral. If the clinical or image interpretation does not parallel your findings or if I can be of any further assistance please contact me.

R. McKenzie Daniel, DVM, DABVP (Canine / Feline Practice)

info@SonoPath.com