


PATIENT

Harley Stutman

PRESENTING CLINICAL SIGNS

Heavy Panting

SPECIES

Canine

BREED

Mixed

SEX

FS

AGE

3yr

WEIGHT

52.5lb

INTERPRETED BY

 R. McKenzie Daniel,
 DVM, DABVP
 (Canine and Feline)

IMAGING PERFORMED BY

Val Shumskaya

HOSPITAL NAME

 Rockaway Animal
 Hospital

REFERRING VET

Dr. Maniar

INVOICE

13451ag

DATE

04/14/2023

ULTRASONOGRAPHIC EXAMINATION OF THE ABDOMEN AND HEART

CANINE CARDIAC PARAMETERS	MR VMAX (m/s)	TR VMAX (m/s)	LA/AO (Boon method)	LA/AO (Heart Base; Swe)	FS (%)	EF (%)	EPSS (cm)
NORMAL PARAMETER	4.5-5.5	<2.7	1.3	<1.3	28-40	40-100	<0.6
PATIENT				1.2	48	81	0.25
CANINE CARDIAC PARAMETERS	HR (BPM)	AV VMAX (m/s)	PV MAX (m/s)	BODY WEIGHT (kg)	LA 2D short axis Base view (cm)	LVIDd Avg; 2D and m-mode short axis (cm)	LVIDs Avg; 2D and m-mode short axis (cm)
NORMAL PARAMETER	50-100	0.7-1.7	0.7-1.6				
PATIENT	123	2.0	1.5		3.4	3.3	

Cardiac Presentation

The echocardiogram in this patient demonstrated normal left atrial size based on 3 separate methods of LA evaluation. The cranial and caudal mitral valve leaflets presented normal linear structure, extension in systole, and union in diastole with normal kinesis. No overt MR on Doppler. The left ventricle presented thicknesses with linear contour and was not dilated nor restricted. The myocardium presented normal echogenicity without subjective evidence of significant fibrotic or ischemic disease. Contractility of the ventricular walls was adequate and in normal range for this patient evidenced by the fractional shortening measurement and subjective evaluation of the different regions of the myocardium. The left ventricular outflow tract demonstrated normal laminar flow and subjective structural integrity. Normal measured LVOT velocity. The right atrium and auricle revealed normal size, structure and content. No evidence of masses was noted. Tricuspid valvular assessment demonstrated adequate linear morphology and kinesis. No overt TR on Doppler. The right ventricle was of normal size (1/3 diameter of LV), chordae structure, myocardial echogenicity and thickness. Pulmonary outflow tract assessment revealed normal valve structure, laminar flow, and diameter (approx. 1:1 pa/ao ratio). Normal measured RVOT velocity. No visible pericardial or free pleural fluid was noted. The cranial mediastinum and pericardial and extra-cardiac regions were free of masses in the visible window.

Urinary System

The urinary bladder, trigone, cystourethral junction, and visible pelvic urethra to a depth of 3 cm exhibited normal thickness and tone. Anechoic urine was present in the lumen with no uroliths or sediment. The ureteral papillae were normal. The ureters were not visible which is normal. No evidence of inflammatory or neoplastic changes were noted.

Normal size and margination were present in the kidneys. A normal 1:3 cortex / medulla ratio and normal corticomedullary definition were maintained. The echogenicity of the cortex was similar to or slightly less than normal liver parenchyma while the medulla echogenicity was hypoechoic to the



PATIENT	cortex with no evidence of pelvic dilation. The left kidney measured 5.5 cm in length. The right kidney measured 5.8 cm in length.
Harley Stutman	The area of the aortic trifurcation was free of pathology.
SPECIES	<i>Adrenal Glands</i>
Canine	The left adrenal gland was uniform in size and contour with a uniformly hypoechoic parenchyma. The left adrenal gland measured 0.42 cm width at the caudal pole and 2.0 cm length. The right adrenal gland was uniform in size and contour with a uniformly hypoechoic parenchyma. The right adrenal gland measured 0.57 cm width at the caudal pole and 2.7 cm length.
BREED	
Mixed	<i>Spleen</i>
SEX	The spleen exhibited a finely textured and homogenous parenchyma which was hyperechoic to the liver and renal cortical parenchyma. The capsule was smooth and regular without apparent expansion.
FS	The splenic vasculature at the hilus was normal in volume with no evidence of congestion or thrombosis. Acute to chronic inflammatory, neoplastic, or benign parenchyma changes were not noted.
AGE	<i>Liver/Gallbladder</i>
3yr	The liver was subjectively normal in size, structure, and contour. The liver parenchyma was uniform and hypoechoic to the spleen with a mild coarse echotexture. The hepatic and portal vasculature were normal in appearance without signs of congestion. The gallbladder was non-distended in size with thin walls and primarily anechoic luminal content. The cystic and common bile ducts were normal.
WEIGHT	<i>Gastrointestinal</i>
52.5lb	The stomach presented intact wall layering with a normal wall layer ratio. The lumen of the stomach contained mild to moderate ingesta sonographically consistent with food with no signs of ileus, obstruction or foreign material.
INTERPRETED BY	The small intestine presented intact wall layering with 1:3 muscularis/mucosa ratio. The lumen of the small intestine was empty with no signs of ileus, obstruction or foreign material.
R. McKenzie Daniel, DVM, DABVP (Canine and Feline)	Normal visible colon wall layers were present with apparent formed feces in lumen.
IMAGING PERFORMED BY	<i>Pancreas</i>
Val Shumskaya	The parenchyma of the left limb, body and right limb of the pancreas presented isoechoic to the adjacent omental fat. A normal curvilinear capsule contour of the pancreas was present. The visible pancreatic duct was normal. No signs of active inflammation or neoplastic disease was evident.
HOSPITAL NAME	<i>Free Abdomen</i>
Rockaway Animal Hospital	No omental masses, overt lymphadenopathy or peritoneal effusion was present.
REFERRING VET	ULTRASONOGRAPHIC FINDINGS
Dr. Maniar	<ul style="list-style-type: none"> • Normal echocardiogram. • Sonographically unremarkable abdomen.
INVOICE	<u>INTERPRETATION OF THE FINDINGS & FURTHER RECOMMENDATIONS</u>
13451ag	No evidence of cardiac or abdominal visceral pathology.
DATE	
04/14/2023	



PATIENT

Harley Stutman

SPECIES

Canine

BREED

Mixed

SEX

FS

AGE

3yr

WEIGHT

52.5lb

INTERPRETED BY

R. McKenzie Daniel,
DVM, DABVP
(Canine and Feline)

IMAGING PERFORMED BY

Val Shumskaya

HOSPITAL NAME

Rockaway Animal
Hospital

REFERRING VET

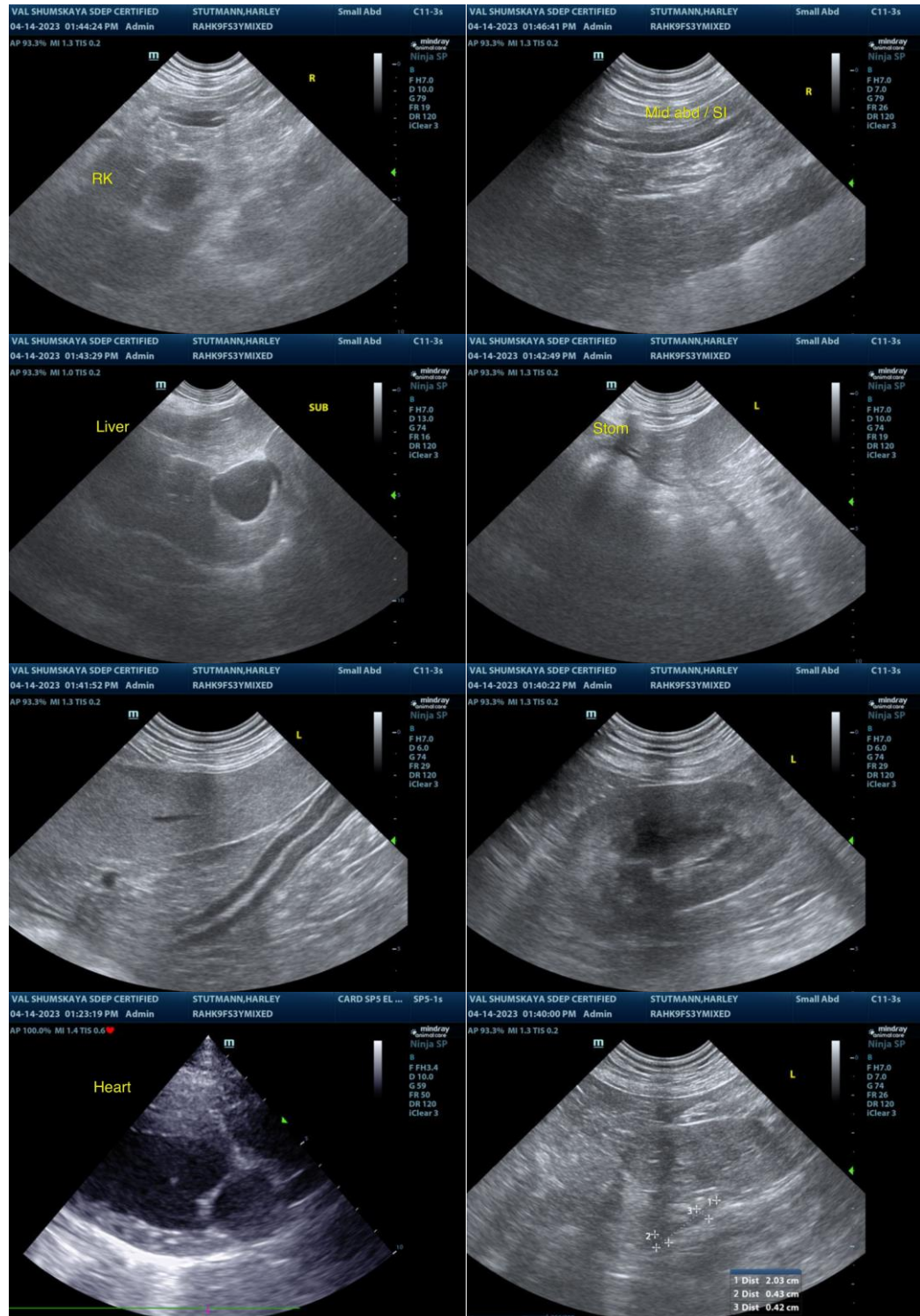
Dr. Maniar

INVOICE

13451ag

DATE

04/14/2023





PATIENT

Harley Stutman

SPECIES

Canine

BREED

Mixed

SEX

FS

AGE

3yr

WEIGHT

52.5lb

INTERPRETED BY

R. McKenzie Daniel,
DVM, DABVP
(Canine and Feline)

IMAGING PERFORMED BY

Val Shumskaya

HOSPITAL NAME

Rockaway Animal
Hospital

REFERRING VET

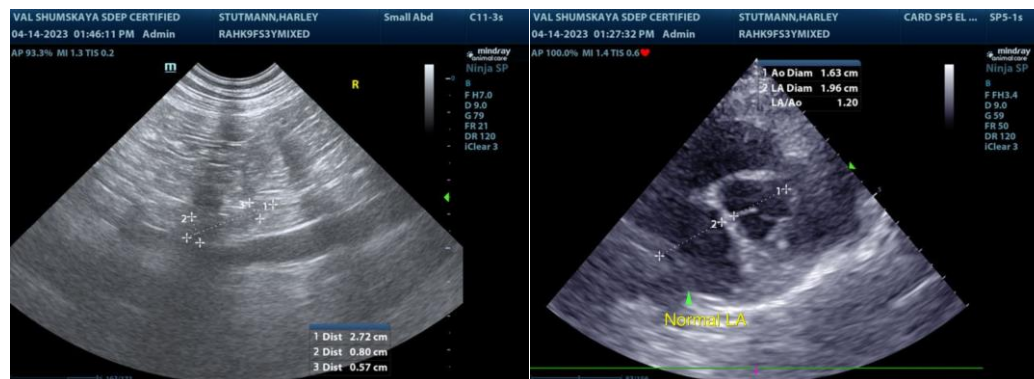
Dr. Maniar

INVOICE

13451ag

DATE

04/14/2023



The information and recommendations provided are based on the images presented by the referring veterinarian/sonographer. No evaluation can be communicated regarding pathology that was not visible in the image/video clips provided.

Thank you for this referral. If the clinical or image interpretation does not parallel your findings or if I can be of any further assistance, please contact me.

R. McKenzie Daniel, DVM, DABVP (Canine/Feline Practice)
mac.daniel@sonopath.com