



**PATIENT**

Ebony Harrington

**SPECIES**

Canine

**BREED**

Greyhound

**SEX**

FS

**AGE**

9yr

**WEIGHT**

65.3lb

**PRESENTING CLINICAL SIGNS**

Firm mass ventral neck, more R side than L No current meds.

Abnormal PE/Chem/CBC/UA Results: 2/1/23 Neuts 2001, T4 1.7, Na 162, Cl 124

**ULTRASONOGRAPHIC EXAMINATION OF THE NECK**

A large irregular non-homogenous vascular mass was present primarily in the area of the right thyroid lobe measuring ~ 6.0-7.0 cm in diameter. Extension of the mass ventrally around the trachea into the area of left thyroid lobe was visualized. The mass exhibited subtle areas of intraparenchymal small cystic lesions, an example of a lesion measured 0.75 cm in diameter. The left thyroid lobe was indistinctly visualized yet appeared to be mildly enlarged and irregular exhibiting similar appearing non-homogenous parenchyma subjectively measuring 2.7 cm x 1.1 cm. No obvious evidence of peripheral or associated subcutaneous effusion. The trachea appeared to be sonographically normal.

**ULTRASONOGRAPHIC FINDINGS**

- Irregular non-homogenous vascular mass primarily area of the right thyroid lobe with likely extension/involvement of the left thyroid lobe.

**INTERPRETATION OF THE FINDINGS & FURTHER RECOMMENDATIONS**

Based on location, the mass is most consistent with neoplastic criteria of thyroid origin such as carcinoma/adenocarcinoma. Non-thyroid or benign etiology is possible yet thought less likely. Correlation with pending cytology is recommended. Potential subnormal T4 levels owing to destruction of normal thyroid tissue.

Oncology consult pending cytology with potential further clarification including surgical CT may be considered.

**INTERPRETED BY**

R. McKenzie Daniel,  
DVM, DABVP  
(Canine and Feline)

**IMAGING PERFORMED BY**

Jessica Miller

**HOSPITAL NAME**

American AH

**REFERRING VET**

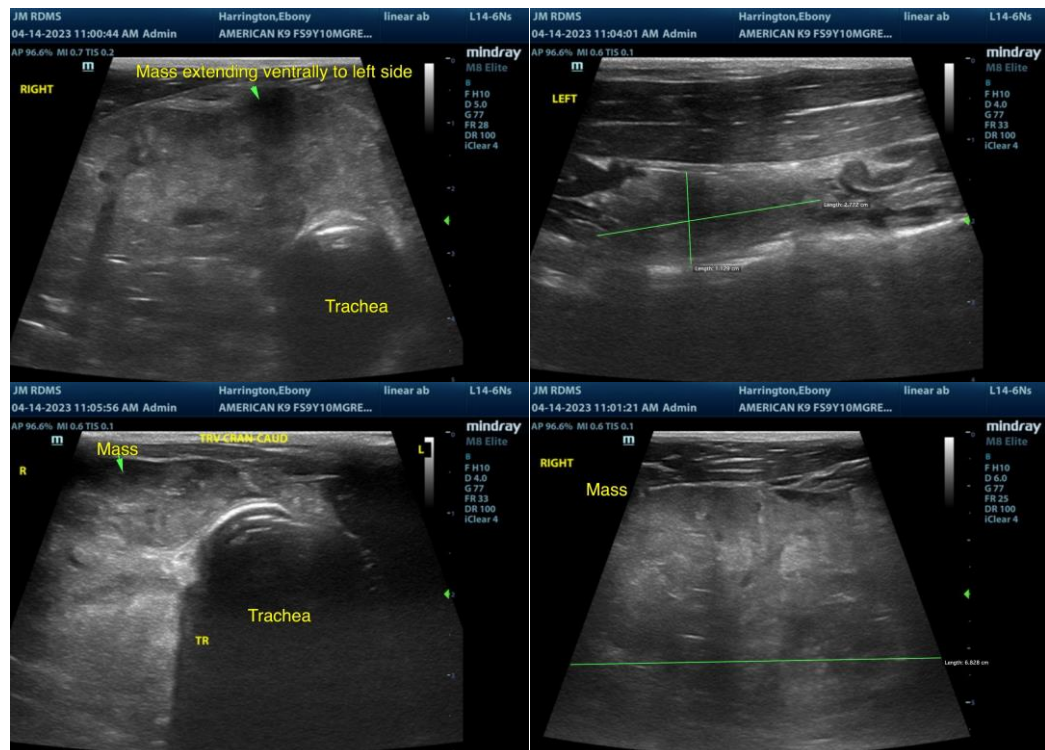
Dr. Stockmal

**INVOICE**

13458ag

**DATE**

04/14/2023





**PATIENT**

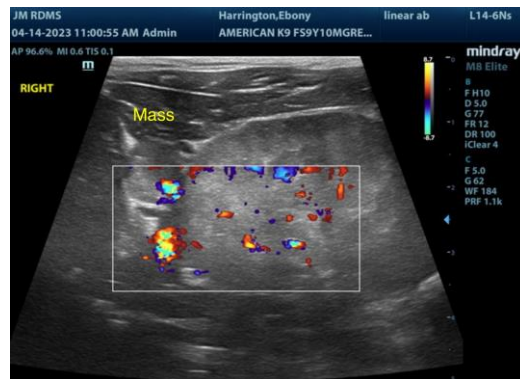
Ebony Harrington

**SPECIES**

Canine

**BREED**

Greyhound



**SEX**

FS

**AGE**

9yr

**WEIGHT**

65.3lb

**INTERPRETED BY**

R. McKenzie Daniel,  
DVM, DABVP  
(Canine and Feline)

**IMAGING PERFORMED BY**

Jessica Miller

**HOSPITAL NAME**

American AH

**REFERRING VET**

Dr. Stockmal

**INVOICE**

13458ag

**DATE**

04/14/2023

The information and recommendations provided are based on the images presented by the referring veterinarian/sonographer. No evaluation can be communicated regarding pathology that was not visible in the image/video clips provided.

Thank you for this referral. If the clinical or image interpretation does not parallel your findings or if I can be of any further assistance, please contact me.

R. McKenzie Daniel, DVM, DABVP (Canine/Feline Practice)  
[mac.daniel@sonopath.com](mailto:mac.daniel@sonopath.com)