


PATIENT

Darsi Both

PRESENTING CLINICAL SIGNS

Heart murmur III/VI mitral - needs dental

Current meds: Apoquel

SPECIES

Canine

Abnormal PE/Chem/CBC/UA Results: CK 824 UA SG: 1.050

ULTRASONOGRAPHIC EXAMINATION OF THE HEART
BREED

Chinese Crested

SEX

FS

AGE

10yr

WEIGHT

11lb

CANINE CARDIAC PARAMETERS	MR VMAX (m/s)	TR VMAX (m/s)	LA/AO (Boon method)	LA/AO (Heart Base; Swe)	FS (%)	EF (%)	EPSS (cm)
NORMAL PARAMETER	4.5-5.5	<2.7	1.3	<1.3	28-40	40-100	<0.6
PATIENT			1.1	1.0	34	65	0.15
CANINE CARDIAC PARAMETERS	HR (BPM)	AV VMAX (m/s)	PV MAX (m/s)	BODY WEIGHT (kg)	LA 2D short axis Base view (cm)	LVIDd Avg; 2D and m-mode short axis (cm)	LVIDs Avg; 2D and m-mode short axis (cm)
NORMAL PARAMETER	50-100	0.7-1.7	0.7-1.6				
PATIENT	126	2.0	0.92		2.3	2.2	

INTERPRETED BY

 R. McKenzie Daniel,
 DVM, DABVP
 (Canine and Feline)

Cardiac Presentation

The echocardiogram in this patient demonstrated normal left atrial size based on 3 different LA measurement methods. Chamber volumes and echogenicity were normal. The cranial and caudal mitral valve leaflets presented mild thickening consistent with endocardiosis. Doppler indicated mild eccentric insufficiency. The left ventricle presented thicknesses with linear contour and was not dilated nor restricted. The myocardium presented normal echogenicity without subjective evidence of significant fibrotic or ischemic disease. Contractility of the ventricular walls was adequate and in normal range for this patient evidenced by the fractional shortening measurement and subjective evaluation of the different regions of the myocardium. The left ventricular outflow tract demonstrated normal laminar flow and subjective structural integrity. The right atrium and auricle revealed normal size, structure and content. No evidence of masses was noted or chamber overload. Tricuspid valvular assessment demonstrated adequate linear morphology. The right ventricle was of normal size (1/3 diameter of LV), chordae structure, myocardial echogenicity and thickness. Pulmonic tract assessment revealed normal valve structure, laminar flow, and diameter (approx.1:1 pa/ao ratio). No visible pericardial or free pleura fluid was noted. No echographically detectable evidence of infiltrative disease was visible. The cranial mediastinum and pericardial regions were free of masses in the visible window.

IMAGING PERFORMED BY

Jessica Miller

HOSPITAL NAME

The Gentle Vet

REFERRING VET

Dr. Dulude

ULTRASONOGRAPHIC FINDINGS

- Compensated chronic mitral valve disease (ACVIM B1)

INVOICE

13457ag

DATE

04/14/2023



PATIENT

Darsi Both

SPECIES

Canine

BREED

Chinese Crested

INTERPRETATION OF THE FINDINGS & FURTHER RECOMMENDATIONS

The cause of the murmur is chronic degenerative valvular changes with secondary mild eccentric MR. The lack of left atrial enlargement implies that the risk of complication secondary to mitral valve insufficiency is relatively low at this time and, without current clinical signs, indicates that medical therapy is not required at this stage. No anesthetic contraindications.

Prognosis at this stage is variable and serial sonographic monitoring is recommended with a recheck echocardiogram in 8-12 months, sooner if clinical signs suggestive of heart disease develop.

Suggested anesthetic protocol may include opioid or Benzodiazepine pre-med, induction with Propofol or Alfaxalone, and appropriate gas anesthesia with avoidance of alpha 2 agonists.

SEX

FS

AGE

10yr

WEIGHT

11lb

INTERPRETED BY

R. McKenzie Daniel,
DVM, DABVP
(Canine and Feline)

IMAGING PERFORMED BY

Jessica Miller

HOSPITAL NAME

The Gentle Vet

REFERRING VET

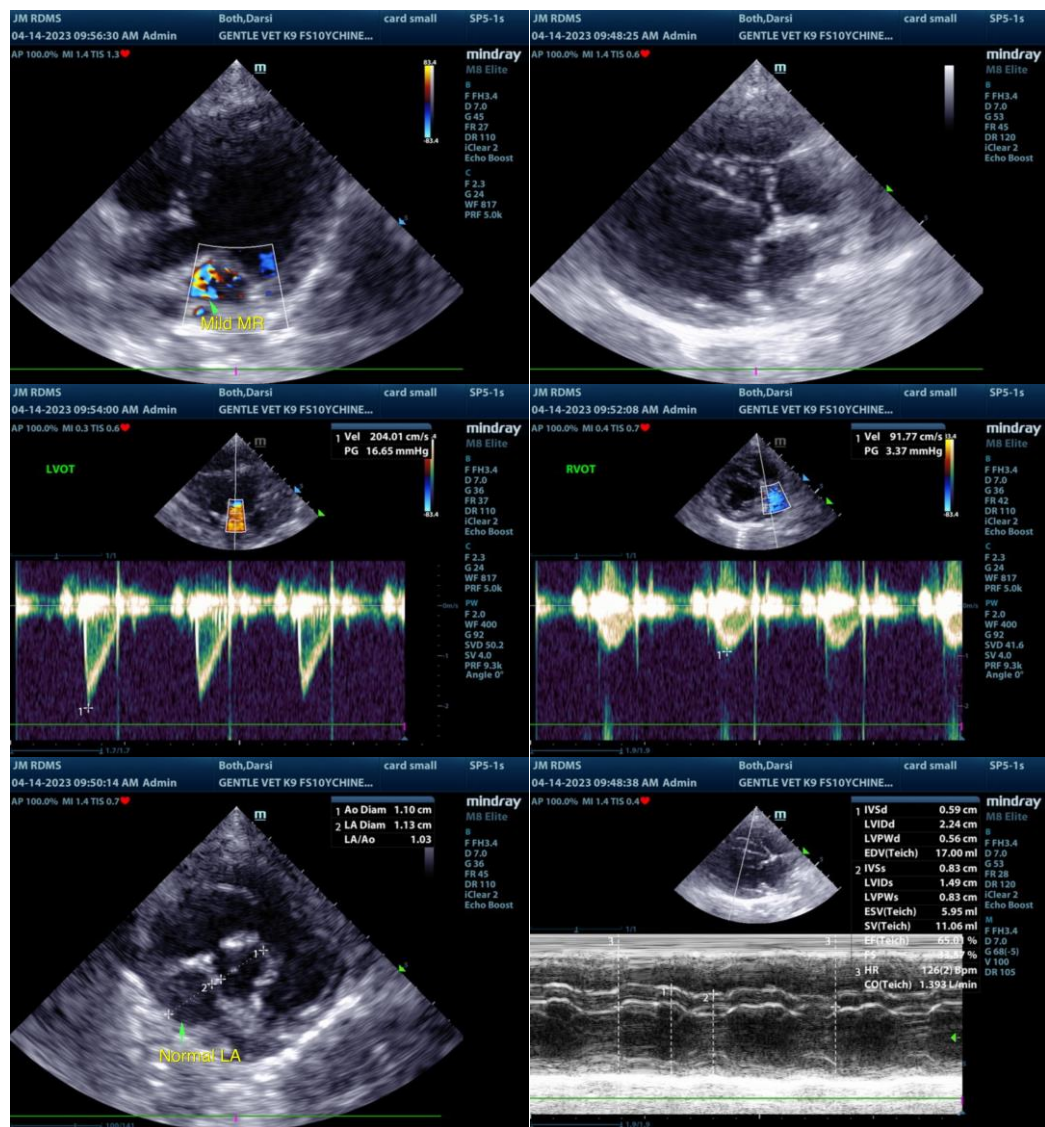
Dr. Dulude

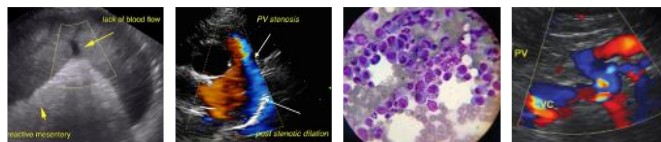
INVOICE

13457ag

DATE

04/14/2023





PATIENT

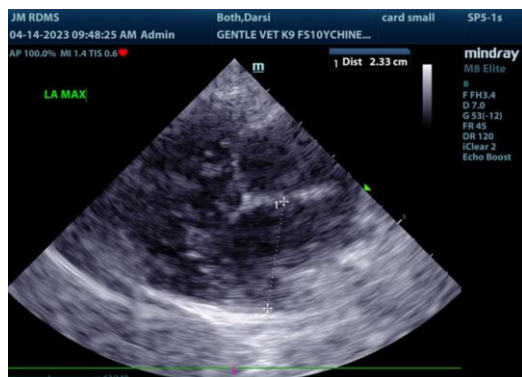
Darsi Both

SPECIES

Canine

BREED

Chinese Crested



SEX

FS

AGE

10yr

WEIGHT

11lb

INTERPRETED BY

R. McKenzie Daniel,
DVM, DABVP
(Canine and Feline)

IMAGING PERFORMED BY

Jessica Miller

HOSPITAL NAME

The Gentle Vet

REFERRING VET

Dr. Dulude

INVOICE

13457ag

DATE

04/14/2023

The information and recommendations provided are based on the images presented by the referring veterinarian/sonographer. No evaluation can be communicated regarding pathology that was not visible in the image/video clips provided.

Thank you for this referral. If the clinical or image interpretation does not parallel your findings or if I can be of any further assistance, please contact me.

R. McKenzie Daniel, DVM, DABVP (Canine/Feline Practice)
mac.daniel@sonopath.com