



PATIENT

Finn Duncan

SPECIES

Canine

BREED

Irish Wolf Hound

SEX

MN

AGE

5 years

WEIGHT

170 lbs.

INTERPRETED BY

R. McKenzie Daniel,
DVM, DABVP
(Canine and Feline)

IMAGING PERFORMED BY

Jenna Walsh CVT

HOSPITAL NAME

Countryside AC

REFERRING VET

Dr. Cox

INVOICE

16610

DATE

4/13/23

PRESENTING CLINICAL SIGNS

Changes in mobility, not losing weight with reduction of calories

Current Medications PhycosMax, gabapentin

ULTRASONOGRAPHIC EXAMINATION OF THE HEART & ABDOMEN

CANINE	MR	TR	LA/AO	LA/AO	FS	EF	EPSS
CARDIAC PARAMETERS	VMAX (m/s)	VMAX (m/s)	(Boon method)	(Heart Base; Swe)	(%)	(%)	(cm)
NORMAL PARAMETER	4.5-5.5	<2.7	1.3	<1.3	28-40	40-100	<0.6
PATIENT				1.3	34	63	0.5
CANINE	HR	AV	PV	BODY WEIGHT	LA	LVIDd	LVIDs
CARDIAC PARAMETERS	(BPM)	VMAX (m/s)	MAX (m/s)	(kg)	2D short axis Base view (cm)	Avg; 2D and m-mode short axis (cm)	Avg; 2D and m-mode short axis (cm)
NORMAL PARAMETER	50-100	0.7-1.7	0.7-1.6				
PATIENT	125	1.4	1.1		5.2	5.1	

Cardiac Presentation

The echocardiogram in this patient demonstrated normal **left atrial** size based on 3 separate methods of LA evaluation. The cranial and caudal **mitral** valve leaflets presented normal linear structure, extension in systole, and union in diastole with normal kinesis. Mild centralized MR was present on Doppler. The **left ventricle** presented thicknesses with linear contour and was not dilated nor restricted. The **myocardium** presented normal echogenicity without subjective evidence of significant fibrotic or ischemic disease. **Contractility** of the ventricular walls was adequate and in normal range for this patient evidenced by the fractional shortening measurement and subjective evaluation of the different regions of the myocardium. The **left ventricular outflow** tract demonstrated normal laminar flow and subjective structural integrity. The **right atrium** and auricle revealed normal size, structure and content. No evidence of masses was noted. **Tricuspid** valvular assessment demonstrated adequate linear morphology and kinesis. The **right ventricle** was of normal size (1/3 diameter of LV), chordae structure, myocardial echogenicity and thickness. **Pulmonary outflow** tract assessment revealed normal valve structure, laminar flow, and diameter (approx. 1:1 pa/ao ratio). No visible **pericardial** or free pleura fluid was noted. The cranial **mediastinum and pericardial and extra-cardiac regions** were free of masses in the visible window.



PATIENT

Urinary System

Finn Duncan

The urinary bladder, trigone, cystourethral junction, and visible pelvic urethra to a depth of 5.0 cm exhibited normal thickness and tone. Anechoic urine was present in the lumen with no uroliths or sediment. The ureteral papillae were normal. The ureters were not visible which is normal. No evidence of inflammatory or neoplastic changes was noted.

SPECIES

Canine

No evidence of pathology associated with the residual prostate.

BREED

Irish Wolf Hound

The area of the aortic trifurcation was free of pathology.

SEX

MN

Normal size and margination were present in the kidneys. A normal 1:3 cortex / medulla ratio and normal corticomedullary definition were maintained. The echogenicity of the cortex was similar to or slightly less than normal liver parenchyma while the medulla echogenicity was hypoechoic to the cortex with no evidence of pelvic dilation. The left kidney measured 8.8 cm in length. The right kidney measured 8.6 cm in length.

AGE

5 years

Adrenal Glands

WEIGHT

170 lbs.

The left adrenal gland was uniform in size and contour with a uniformly hypoechoic parenchyma. The left adrenal gland measured 0.65 cm width at the caudal pole and 0.72 cm width at the cranial pole. The right adrenal gland was uniform in size and contour with a uniformly hypoechoic parenchyma. The right adrenal gland measured 0.65 cm width at the caudal pole.

INTERPRETED BY

R. McKenzie Daniel,
DVM, DABVP
(Canine and Feline)

Spleen

The spleen exhibited a finely textured and homogenous parenchyma which was hyperechoic to the liver and renal cortical parenchyma. The capsule was smooth and regular without apparent expansion. The splenic vasculature at the hilus was normal in volume with no evidence of congestion or thrombosis. Acute to chronic inflammatory, neoplastic, or benign parenchyma changes were not noted.

IMAGING PERFORMED BY

Jenna Walsh CVT

Liver/ Gallbladder

HOSPITAL NAME

Countryside AC

The liver was subjectively normal in size, structure, and contour. The liver parenchyma was uniform and hypoechoic to the spleen with a mild coarse echotexture. The hepatic and portal vasculature were normal in appearance without signs of congestion. The gallbladder was non-distended in size with thin walls and primarily anechoic luminal content. The cystic and common bile ducts were normal.

REFERRING VET

Dr. Cox

Gastrointestinal

INVOICE

16610

The stomach presented intact wall layering with a normal wall layer ratio. The lumen of the stomach was empty with no signs of ileus, obstruction, or foreign material.

DATE

4/13/23

The small intestine presented intact wall layering with 1:3 muscularis/mucosa ratio. The lumen of the small intestine was empty with no signs of ileus, obstruction, or foreign material.

Normal visible colon wall layers were present with apparent formed feces in lumen.



PATIENT

Pancreas

Finn Duncan

The parenchyma of the left limb, body, and right limb of the pancreas presented isoechoic to the adjacent omental fat. A normal curvilinear capsule contour of the pancreas was present. The visible pancreatic duct was normal. No signs of active inflammation or neoplastic disease were evident.

SPECIES

Canine

Free Abdomen

BREED

No overt lymphadenopathy or peritoneal effusion was present.

Irish Wolf Hound

ULTRASONOGRAPHIC FINDINGS

SEX

- Overtly normal cardiac structure and function - no evidence of DCM criteria
- Mild centralized MR
- Sonographically unremarkable abdomen

MN

AGE

5 years

INTERPRETATION OF THE FINDINGS & FURTHER RECOMMENDATIONS

WEIGHT

170 lbs.

No evidence of structural / functional cardiomyopathy. No evidence of abdominal visceral pathology.

The mild MR noted on Doppler is not considered clinically significant at this stage, given the lack of left atrium enlargement and without evidence of DCM criteria.

INTERPRETED BY

R. McKenzie Daniel,
DVM, DABVP
(Canine and Feline)

Recheck echocardiogram is suggested in 6-8 months, sooner if clinical signs consistent with cardiac disease arise.

IMAGING PERFORMED BY

Jenna Walsh CVT

HOSPITAL NAME

Countryside AC

REFERRING VET

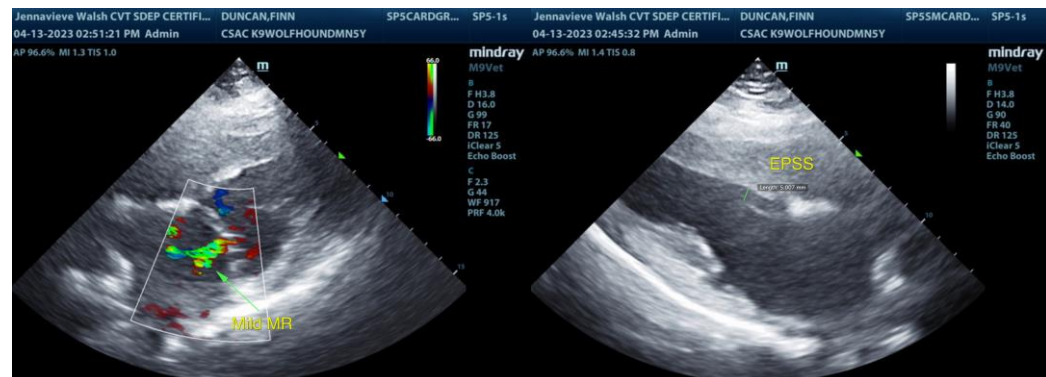
Dr. Cox

INVOICE

16610

DATE

4/13/23





PATIENT

Finn Duncan

SPECIES

Canine

BREED

Irish Wolf Hound

SEX

MN

AGE

5 years

WEIGHT

170 lbs.

INTERPRETED BY

R. McKenzie Daniel,
DVM, DABVP
(Canine and Feline)

IMAGING PERFORMED BY

Jenna Walsh CVT

HOSPITAL NAME

Countryside AC

REFERRING VET

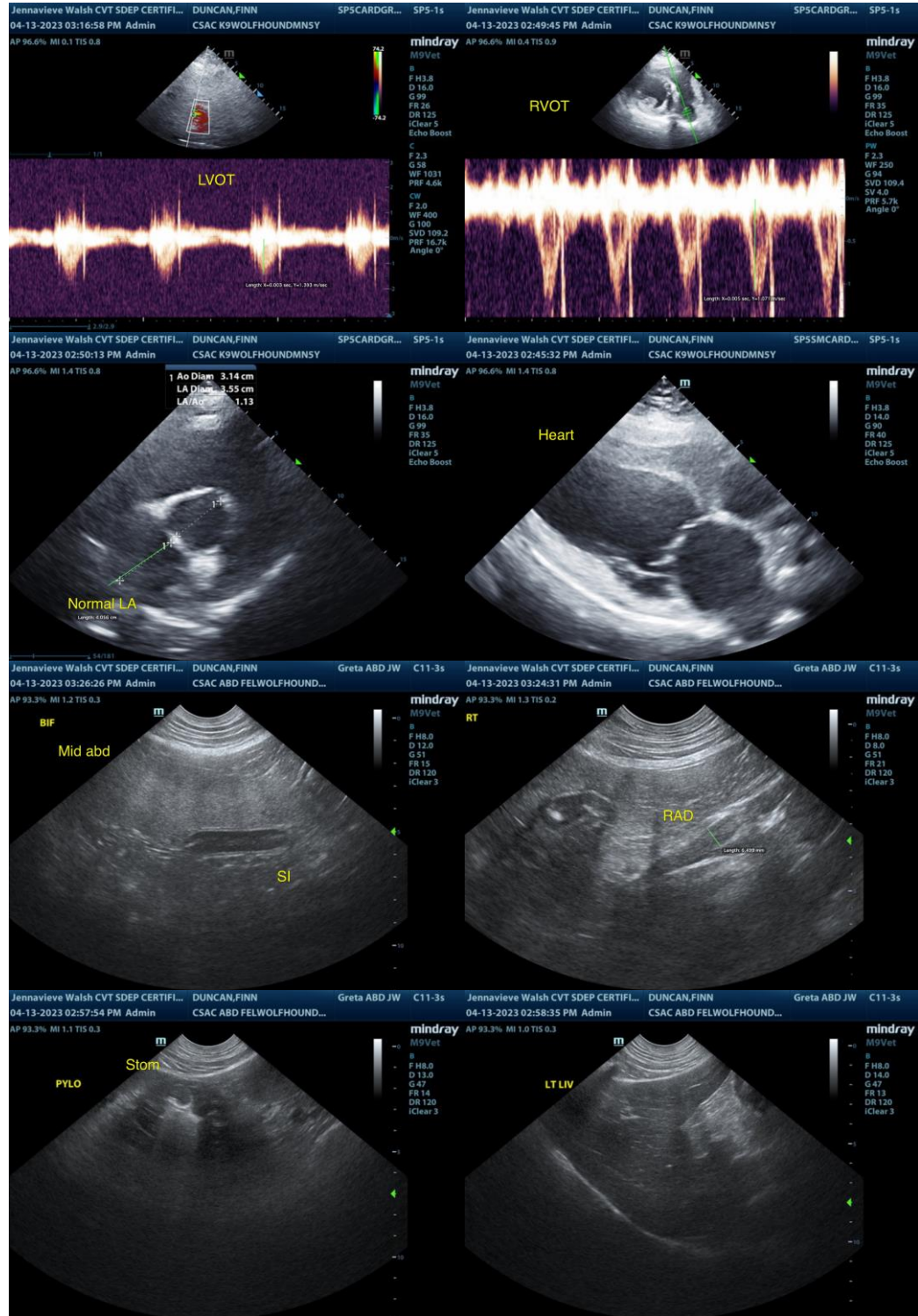
Dr. Cox

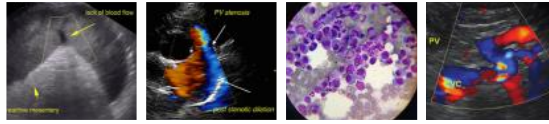
INVOICE

16610

DATE

4/13/23





PATIENT

Finn Duncan

SPECIES

Canine

BREED

Irish Wolf Hound

SEX

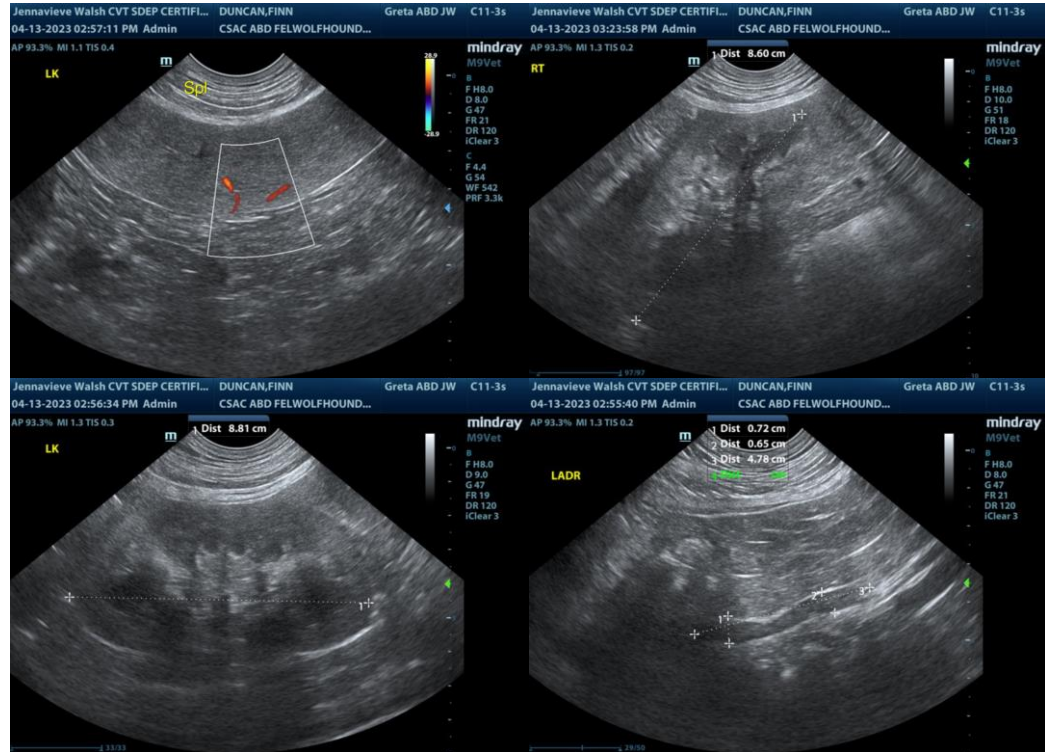
MN

AGE

5 years

WEIGHT

170 lbs.



INTERPRETED BY

R. McKenzie Daniel,
DVM, DABVP
(Canine and Feline)

IMAGING PERFORMED BY

Jenna Walsh CVT

HOSPITAL NAME

Countryside AC

REFERRING VET

Dr. Cox

INVOICE

16610

DATE

4/13/23

The information and recommendations provided are based on the images presented by the referring veterinarian/sonographer. No evaluation can be communicated regarding pathology that was not visible in the image/video clips provided.

Thank you for this referral. If the clinical or image interpretation does not parallel your findings or if I can be of any further assistance please contact me.

R. McKenzie Daniel, DVM, DABVP (Canine / Feline Practice)
info@SonoPath.com