



PATIENT PRESENTING CLINICAL SIGNS

Elvis Diprimo History: Howling, sleeping a lot, abnormal gas pattern in GI, soft tissue opacity in thoracic cavity
Abnormal PE/Chem/CBC/UA Results: pending

SPECIES ULTRASONOGRAPHIC EXAMINATION OF THE HEART & ABDOMEN

Feline

BREED

DSH

SEX

Neutered Male

AGE

10 Years

WEIGHT

13.8 Pounds

FELINE CARDIAC PARAMETERS	BODY WEIGHT (kg)	HR (BPM)	IVSd (cm)	LVIDd (cm)	LVWd (cm)	FS (%)	EF (%)
NORMAL PARAMETER	-----	150-240	0.3-0.6	1.0-2.1	0.25-0.6	35-67	80-100
PATIENT	--	NM	0.35	1.4	0.35	48	81
FELINE CARDIAC PARAMETERS	LA/AO (Boon)	LA/AO HEART BASE (Sisson)	LA 2D 4-chamber long axis AS to FW (Sisson) (cm)	LVOT VEL. (m/s)	RVOT VEL. (m/s)	IVRT (m/)	
NORMAL PARAMETER	<1.5	0.88-1.79	0.7-1.7	<1.6	<1.3	40-60	
PATIENT	--	1.1	1.2	0.9	0.8	NM	

Adapted from June Boon, Veterinary Echocardiography, 1998
Sisson D et al. JVIM 1991; 5: 232, Jacobs et al. Am J Vet Res 1985; 46:1705

Cardiac Presentation

The echocardiogram in this patient demonstrated normal **left atrial** size and structure. Chamber volume and blood echogenicity were normal. The cranial and caudal **mitral** valve leaflets presented minor irregular age-related changes that are not clinically significant at this time with adequate extension in systole and union in diastole. The **left ventricle** presented normal free wall and septal thicknesses with linear contour. The **myocardium** presented some echogenic remodeling consistent with expected age-related change. **Contractility** of the ventricular walls was adequate and in normal range for this breed and patient size. The **left ventricular outflow** tract demonstrated normal laminar flow with subjectively unremarkable structure. Minor aortic insufficiency was present on doppler. Subjective assessment of the **right atrium** and auricle revealed normal size, structure and content. No evidence of masses was noted. **Tricuspid** valvular assessment demonstrated expected findings for this age patient. The **right ventricle** was of normal size (1/3 diameter of LV), echogenicity and thickness. **Pulmonic** tract assessment revealed normal valve structure, laminar flow, and diameter (approx. 1:1 pa/ao ratio). No dilation secondary to cor pulmonale without evidence of pulmonary hypertension. No visible **pericardial** or free pleural fluid was noted. The **mediastinum** was free of masses in the visible window.

Urinary System

The urinary bladder, trigone, cystourethral junction, and visible pelvic urethra to a depth of 2.0 cm exhibited normal thickness and tone. Primarily anechoic urine was present in the lumen. Mild nondependent particulate sediment was present without evidence of calculus formation. The ureteral papillae were normal. The ureters were not visible which is normal. No evidence of inflammatory or neoplastic mural changes were noted.

INTERPRETED BY

R. McKenzie Daniel,
DVM, DABVP
(Canine and Feline)

IMAGING PERFORMED BY

Val Shumskaya

HOSPITAL NAME

Rockaway AH

REFERRING VET

Dr. Natalia

INVOICE

21953

DATE

4/13/23



PATIENT	The area of the aortic trifurcation was free of pathology.
Elvis Diprimo	Normal size and margination were present in the kidneys. A normal 1:3 cortex / medulla ratio was maintained. The medulla and cortices were uniform in texture with some increased echogenicity and mild loss of corticomedullary symmetry and definition expected for the age of the patient. No evidence of pelvic dilation was present. The left kidney measured 3.5 cm in length. The right kidney measured 3.6 cm in length.
SPECIES	
Feline	
BREED	
DSH	
SEX	
Neutered Male	
AGE	
10 Years	
WEIGHT	
13.8 Pounds	
INTERPRETED BY	
R. McKenzie Daniel, DVM, DABVP (Canine and Feline)	
IMAGING PERFORMED BY	
Val Shumskaya	
HOSPITAL NAME	
Rockaway AH	
REFERRING VET	
Dr. Natalia	
INVOICE	
21953	
DATE	
4/13/23	

Adrenal Glands

The left adrenal gland was uniform in size and contour with a uniformly hypoechoic parenchyma. The left adrenal gland measured 0.4 cm.

The right adrenal gland was uniform in size and contour with a uniformly hypoechoic parenchyma. The right adrenal gland measured 0.36 cm.

Spleen

The spleen exhibited a finely textured and homogenous parenchyma which was hyperechoic to the liver and renal cortical parenchyma. The capsule was smooth and regular without apparent expansion. The splenic vasculature at the hilus was normal in volume with no evidence of congestion or thrombosis. Acute to chronic inflammatory, neoplastic, or benign parenchyma changes were not noted.

Liver

The liver was subjectively normal in size, structure, and contour. The liver parenchyma was mildly nonuniform and hypoechoic to the spleen with a moderate coarse echotexture and subjective mild to benign parenchymal remodeling. The hepatic and portal vasculature were normal in appearance without signs of congestion.

The gallbladder was non-distended in size with thin walls and primarily anechoic luminal content. The cystic and common bile ducts were normal.

Gastrointestinal

The stomach presented intact wall layering with a normal wall layer ratio. The lumen of the stomach contained mild to moderate, nonshadowing ingesta, sonographically consistent with food, without signs of obstruction or foreign material.

The small intestine presented intact wall layering with 1:3 muscularis/mucosa ratio. Subjective mild segmental gas pattern was noted. No evidence of mechanical/metabolic intestinal ileus was noted.

Normal visible colon wall layers were present with apparent formed feces in lumen.

Pancreas

The parenchyma of the left limb, body and right limb of the pancreas presented isoechoic to the adjacent omental fat. A normal curvilinear capsule contour of the pancreas was present. The visible pancreatic duct was normal. No signs of active inflammation or neoplastic disease was evident.

Free Abdomen

No omental masses, lymphadenopathy or peritoneal effusion was present. A nonhomogenous, mildly shadowing spherical echo was present within the mid abdomen medial to the spleen, measuring



PATIENT

approximately 1.0 cm in diameter. The echo was consistent with probable focal nodular fat necrosis or bastes body and considered incidental.

Elvis Diprimo

ULTRASONOGRAPHIC FINDINGS

SPECIES

- Overtly normal cardiac structure and function with minor LV myocardial remodeling

Feline

- Minor aortic insufficiency

BREED

- Urinary bladder sediment

DSH

- Mild chronic renal changes

SEX

- Minor hepatic parenchymal remodeling

Neutered Male

- Overtly normal gastrointestinal tract with gastric ingesta- ingesta is sonographically consistent with food

AGE

- Incidental, probable focal nodular fat necrosis/bastes body

10 Years

INTERPRETATION OF THE FINDINGS & FURTHER RECOMMENDATIONS

WEIGHT

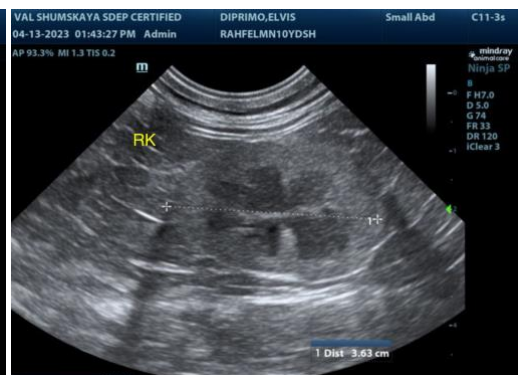
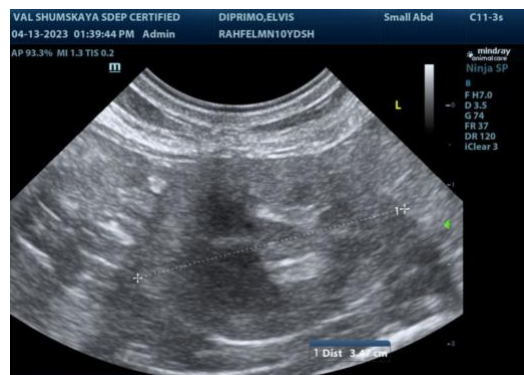
Overall, no sonographic evidence of significant cardiac or abdominal visceral pathology with largely mild age related cardiac and intraabdominal changes. No evidence of cardiac or intraabdominal neoplastic criteria as a potential source of metastasis to the thoracic cavity.

13.8 Pounds

The urinary bladder sediment may suggest cellular / crystalline debris or mucus. Cystocentesis for UA +/- C/S if evidence of inflammatory cells is recommended.

INTERPRETED BY

R. McKenzie Daniel,
DVM, DABVP
(Canine and Feline)

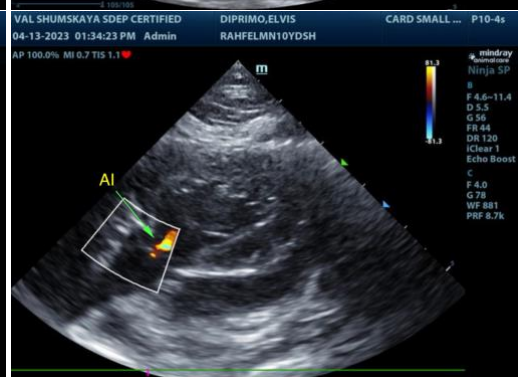
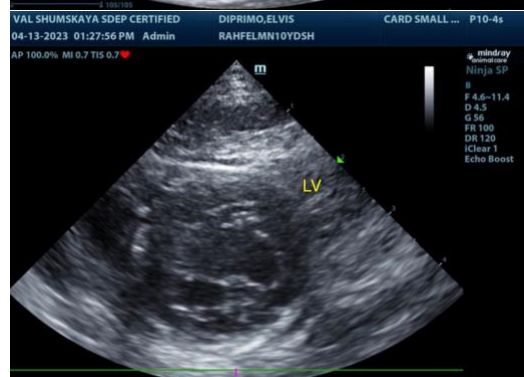


IMAGING PERFORMED BY

Val Shumskaya

HOSPITAL NAME

Rockaway AH



REFERRING VET

Dr. Natalia

INVOICE

21953

DATE

4/13/23



PATIENT

Elvis Diprimo

SPECIES

Feline

BREED

DSH

SEX

Neutered Male

AGE

10 Years

WEIGHT

13.8 Pounds

INTERPRETED BY

R. McKenzie Daniel,
DVM, DABVP
(Canine and Feline)

IMAGING PERFORMED BY

Val Shumskaya

HOSPITAL NAME

Rockaway AH

REFERRING VET

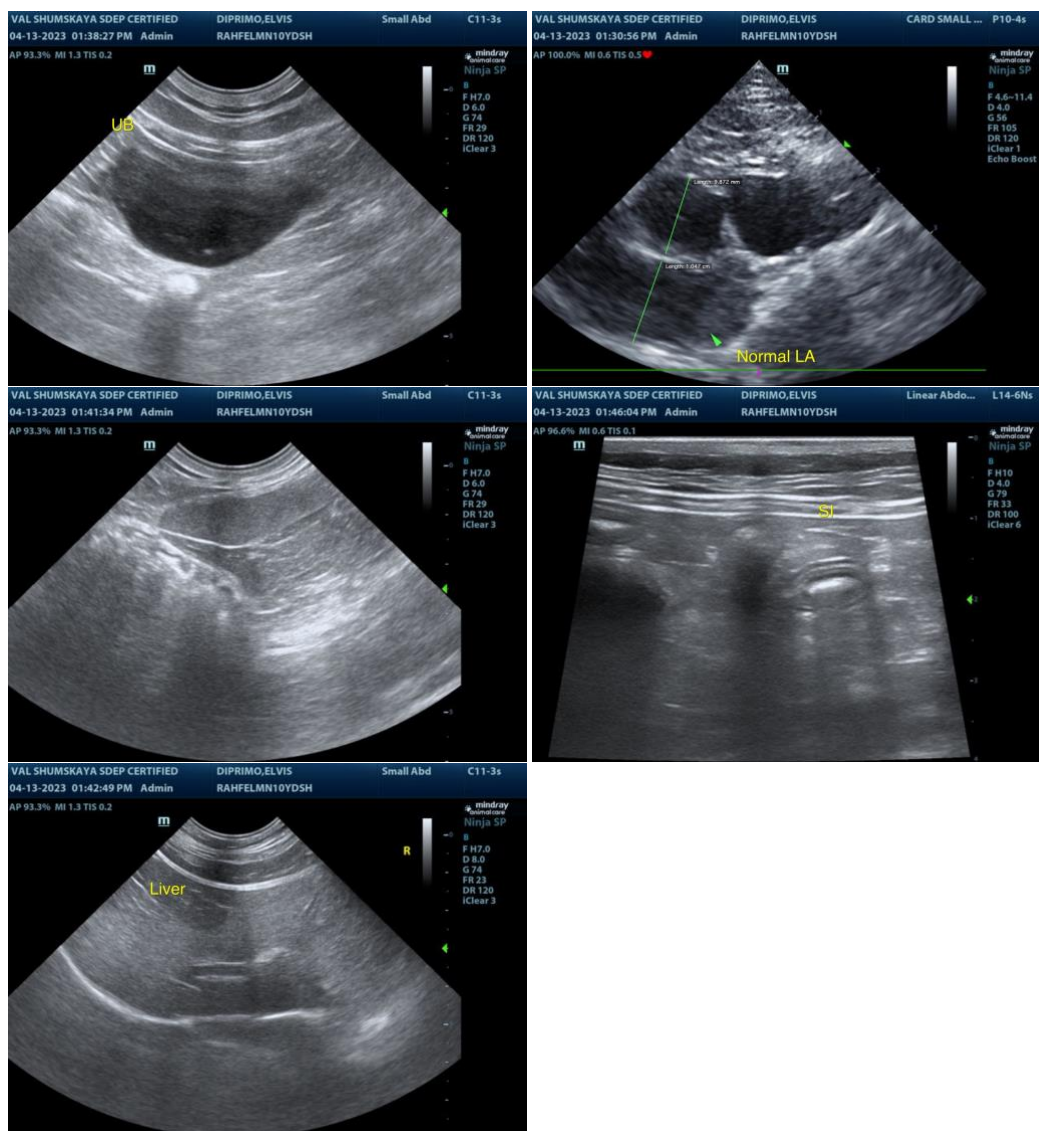
Dr. Natalia

INVOICE

21953

DATE

4/13/23



The information and recommendations provided are based on the images presented by the referring veterinarian. No evaluation can be communicated regarding pathology that was not visible in the image/video clips provided.

Thank you for this referral. If the clinical or image interpretation does not parallel your findings or if I can be of any further assistance please contact me.

R. McKenzie Daniel, DVM, DABVP (Canine / Feline Practice)
info@SonoPath.com