

PATIENT

Cali Beddell

SPECIES

Feline

BREED

DSH

SEX

Spayed Feline

AGE

10

WEIGHT

13lbs

INTERPRETED BY

R. McKenzie Daniel,
DVM, DABVP
(Canine and Feline)

IMAGING PERFORMED BY

Amber Goldman,
RVT

HOSPITAL NAME

Appalachian
Veterinary
Ultrasound

REFERRING VET

Dr. Russell

INVOICE

10178

DATE

4/13/2023

PRESENTING CLINICAL SIGNS

P has been vomiting undigested food for the past week and has been seen at AEC for this before in December, no known cause found P acting normal otherwise, eating/drinking normal gabapentin PRN for anxiety.

ULTRASONOGRAPHIC EXAMINATION OF THE ABDOMEN

Urinary System

The urinary bladder, trigone, cystourethral junction, and visible pelvic urethra to a depth of 2 cm exhibited normal thickness and tone. Anechoic urine was present in the lumen with no uroliths or sediment. The ureteral papillae were normal. The ureters were not visible which is normal. No evidence of inflammatory or neoplastic changes was noted.

The area of the aortic trifurcation was free of pathology.

Normal size and margination was present in the kidneys. A normal 1:3 cortex/medulla ratio was maintained. The medulla and cortices were uniform in texture with some increased echogenicity and loss of corticomedullary symmetry and definition expected for the age of the patient. No evidence of pelvic dilation was present. The left kidney measured 4.0 cm in length. The right kidney measured 4.3 cm in length.

Adrenal Glands

The left adrenal gland was uniform in size and contour with uniformly hypoechoic parenchyma. The left adrenal gland measured 0.37 cm. The right adrenal gland was uniform in size and contour with uniformly hypoechoic parenchyma. The right adrenal gland measured 0.41 cm.

Spleen

The spleen is normal in size and contour. A small, well demarcated, uniform hyperechoic, nondisruptive nodule was noted in the mid-spleen. The spleen measures 0.88 cm. The nodule measures 0.20 cm in diameter.

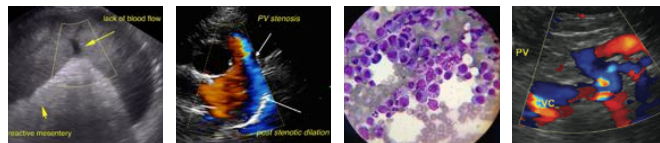
Liver/ Gallbladder

The liver was subjectively normal in size, structure, and contour. The liver parenchyma was uniform and hypoechoic to the spleen with a mild coarse echotexture. The hepatic and portal vasculature were normal in appearance without signs of congestion. The gallbladder was non-distended in size with thin walls and primarily anechoic luminal content. The cystic and common bile ducts were normal.

Gastrointestinal

The stomach presented with normal visualized gastric wall layering. The lumen of the stomach contained echogenic, mild to moderate non-shadowing ingesta/chyme most consistent with post-prandial presentation without signs of ileus, obstruction, or foreign material. No evidence of mechanical pyloric outflow obstruction.

The small intestine presented intact wall layering with a 1:3 muscularis/mucosa ratio. The lumen of the small intestine was empty with no signs of ileus, obstruction, or foreign material. The duodenum exhibited minor corrugation. No obstructive pattern, loss of intestinal wall layering, or evidence of altered wall layer ratio was noted. The duodenum wall measured 0.25 cm in width. The jejunum wall measured 0.25 cm in width. The ileocolic wall measured 0.28 cm in width.



PATIENT

Normal visible colon wall layers were present with apparent formed feces in the lumen.

Cali Beddell

Pancreas

SPECIES

The parenchyma of the left limb, body, and right limb of the pancreas presented isoechoic to the adjacent omental fat. A normal curvilinear capsule contour of the pancreas was present. The visible pancreatic duct was normal. No signs of active inflammation or neoplastic disease were evident.

Feline

BREED

Free Abdomen

DSH

No overt lymphadenopathy, omental masses, or peritoneal effusion was present.

SEX

ULTRASONOGRAPHIC FINDINGS

Spayed Feline

Primary Findings

AGE

- Structurally unremarkable gastrointestinal tract with non-shadowing gastric ingesta, possible minor duodenitis
- Age-related kidneys

10

Secondary Findings

WEIGHT

- Benign splenic nodule – suggestive of small to emerging benign myelolipoma or similar.

13lbs

INTERPRETATION OF THE FINDINGS & FURTHER RECOMMENDATIONS

INTERPRETED BY

Sonographically, no evidence of overt visceral pathology, specifically, no evidence of gastrointestinal mural pathology or evidence of active pancreatitis. The appearance of gastric ingesta is sonographically consistent with food. Correlation with most recent meal ingestion is suggested. If documented NPO, some degree of possible metabolic/functional gastric stasis or non-obstructive delayed gastric emptying could be possible. Dietary intolerance/food allergy, structurally insignificant inflammatory gastrointestinal disease, low grade to chronic pancreatitis, both of which may present sonographically normal. No evidence of intraabdominal neoplastic criteria. Spec FPL could be considered to assess for evidence of low-grade to chronic pancreatitis.

R. McKenzie Daniel,
DVM, DABVP
(Canine and Feline)

IMAGING PERFORMED BY

Amber Goldman,
RVT

Empirically, canned hydrolyzed diet with possible smaller/more frequent meals, gastroprotectant protocol, +/- empirical deworming may prove beneficial.

HOSPITAL NAME

Appalachian
Veterinary
Ultrasound

REFERRING VET

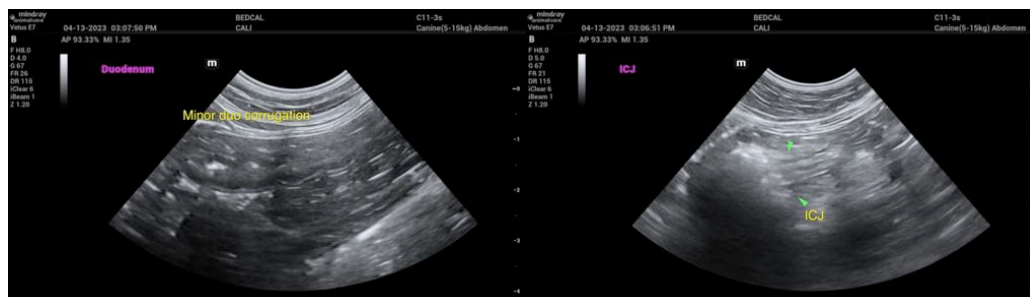
Dr. Russell

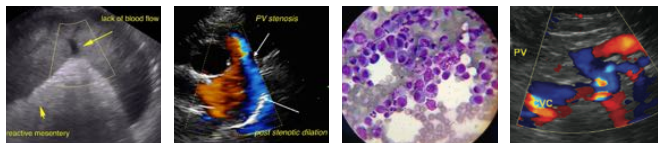
INVOICE

10178

DATE

4/13/2023





PATIENT

Cali Beddell

SPECIES

Feline

BREED

DSH

SEX

Spayed Feline

AGE

10

WEIGHT

13lbs

INTERPRETED BY

R. McKenzie Daniel, DVM, DABVP (Canine and Feline)

IMAGING PERFORMED BY

Amber Goldman, RVT

HOSPITAL NAME

Appalachian Veterinary Ultrasound

REFERRING VET

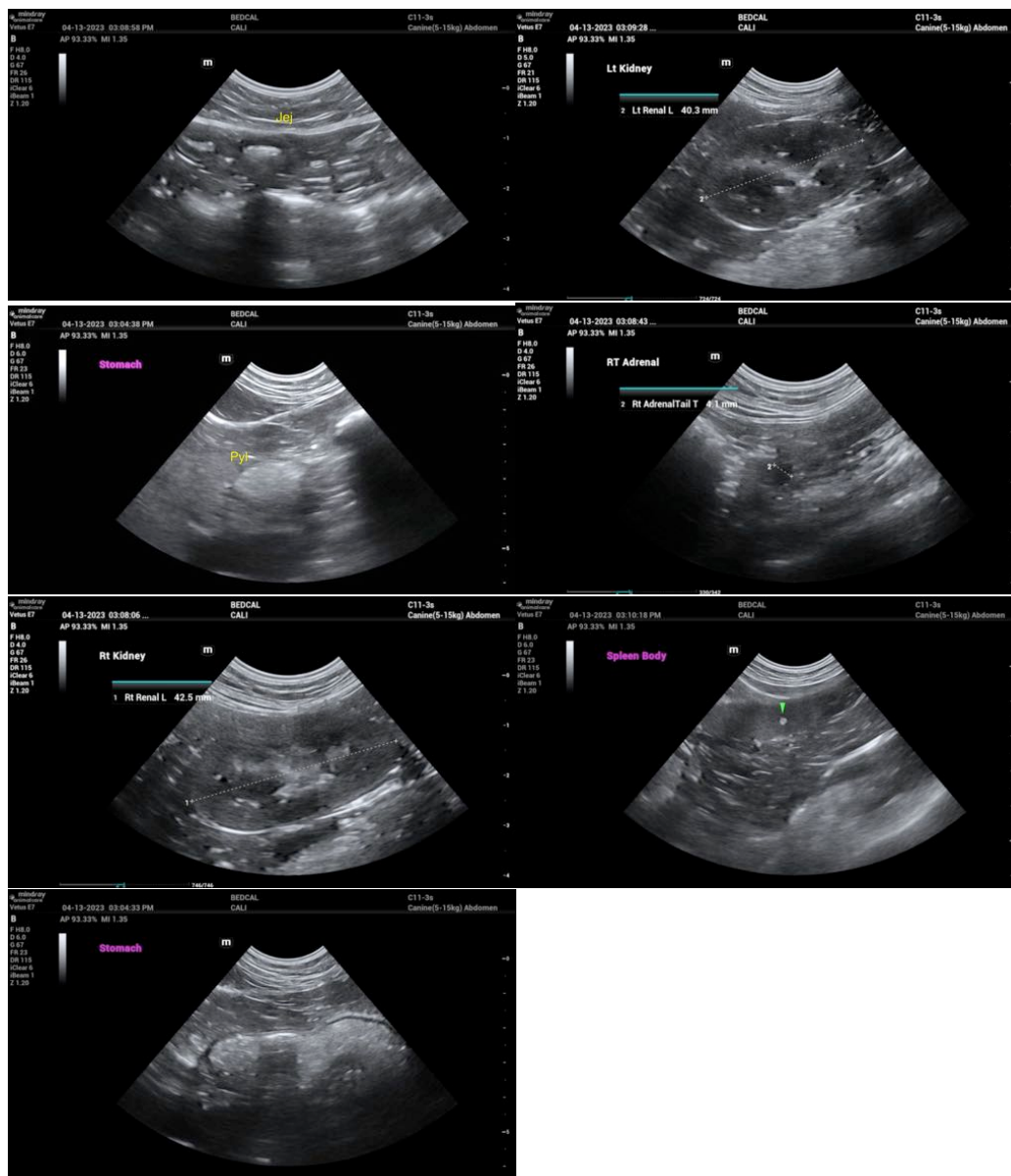
Dr. Russell

INVOICE

10178

DATE

4/13/2023



The information and recommendations provided are based on the images presented by the referring veterinarian/sonographer. No evaluation can be communicated regarding pathology that was not visible in the image/video clips provided.

Thank you for this referral. If the clinical or image interpretation does not parallel your findings or if I can be of any further assistance, please contact me.

R. McKenzie Daniel, DVM, DABVP (Canine / Feline Practice)
info@SonoPath.com