



PATIENT

Daisy Parikh

SPECIES

Canine

BREED

Lhasa Apso

SEX

Spayed Female

AGE

8 Years

WEIGHT

18 pounds

INTERPRETED BY

R. McKenzie Daniel,
DVM, DABVP (Canine
/ Feline Practice)

IMAGING PERFORMED BY

Dr. Sreenivasa
Maddineni

HOSPITAL NAME

West Babylon Animal
Hospital

REFERRING VET

Dr. Sreenivasa
Maddineni

INVOICE

15037

DATE

04/12/26

PRESENTING CLINICAL SIGNS

Follow up abd sono from one taken at VCA, sono report attached. Right nephrectomy performed 1/18/26. Mass identified as cystic renal papillary carcinoma. Distended abdomen. Heavy breathing.

Abnormal PE/Chem/CBC/UA Results: Recent bw showed elevated GGT and SDMA. Most recent bw attached

ULTRASONOGRAPHIC EXAMINATION OF THE ABDOMEN

Urinary System

The urinary bladder, trigone, cystourethral junction, and visible pelvic urethra to a depth of 3.0 cm exhibited normal thickness and tone. Anechoic urine was present in the lumen with no uroliths or sediment. The ureteral papillae were normal. The ureters were not visible which is normal. No evidence of inflammatory or neoplastic change were noted.

Normal size and margination was present in the left kidney. A normal 1:3 cortex / medulla ratio was maintained. The medulla and cortices were uniform in texture with some increased echogenicity and mild loss of corticomedullary symmetry and definition expected for the age of the patient. Nonobstructive medullary to lateral diverticuli renoliths were present. The left kidney measured 4.6 cm in length.

The right kidney was not visualized consistent with previous right nephrectomy.

Adrenal Glands

The left adrenal gland was uniform in size and contour with a uniformly hypoechoic parenchyma. The left adrenal gland measured 0.51 cm width at the caudal pole.

The right adrenal gland was not visualized.

Spleen

The spleen exhibited a finely textured and homogenous parenchyma which was hyperechoic to the liver and renal cortical parenchyma. The capsule was smooth and regular without apparent expansion. The splenic vasculature at the hilus was normal in volume with no evidence of congestion or thrombosis. Acute to chronic inflammatory, neoplastic, or benign parenchyma changes were not noted.

Liver & Gallbladder

The liver was subjectively normal in size, structure, and contour. The liver parenchyma was uniform and hypoechoic to the spleen with a mild coarse echotexture. The hepatic and portal vasculature were normal in appearance without signs of congestion.

The gallbladder was non distended in size with mild nonorganized biliary sludge. The cystic duct and common bile ducts were normal without evidence of dilation.

Gastrointestinal

The stomach presented intact wall layering with a normal wall layer ratio. The lumen of the stomach was empty with no signs of ileus, obstruction or foreign material.



PATIENT

Daisy Parikh

SPECIES

Canine

BREED

Lhasa Apso

SEX

Spayed Female

AGE

8 Years

WEIGHT

18 pounds

INTERPRETED BY

R. McKenzie Daniel,
DVM, DABVP (Canine
/ Feline Practice)

IMAGING PERFORMED BY

Dr. Sreenivasa
Maddineni

HOSPITAL NAME

West Babylon Animal
Hospital

REFERRING VET

Dr. Sreenivasa
Maddineni

INVOICE

15037

DATE

04/12/26

The small intestine presented intact wall layering with 1:3 muscularis/mucosa ratio. The lumen of the small intestine was empty with no signs of ileus, obstruction or foreign material.

Normal visible colon wall layers were present with apparent formed feces in lumen.

Pancreas

The parenchyma of the left limb, body and right limb of the pancreas presented isoechoic to the adjacent omental fat. A normal curvilinear capsule contour of the pancreas was present. The visible pancreatic duct was normal. No signs of active inflammation or neoplastic disease was evident.

Free Abdomen

An ill-defined nonhomogenous nodular appearing mass was present in the cranial abdomen in the area of the right kidney measuring approximately 7.0 cm in diameter. Indistinct mass boundaries compared to adjacent nonhomogenous nodular appearing omentum with omental heterogeneity and nodular changes extending caudally potentially to an approximate level of the apical urinary bladder with concurrent indistinct caudal abdomen to pericystic mass. Variable primarily homogenous to swollen mesenteric lymphadenopathy and mild volume of peritoneal effusion was also present.

ULTRASONOGRAPHIC FINDINGS

- Ill-defined nonhomogenous nodular mass in the cranial abdomen/area of the right kidney.
- Regional to generalized nonhomogenous nodular mesentery and associated variable swollen hypoechoic mesenteric lymphadenopathy.
- Mild volume effusion.
- Intact mild chronic left kidney exhibiting nonobstructive medullary renoliths.
- Sonographically unremarkable liver/spleen.
- Mild gallbladder debris.

INTERPRETATION OF THE FINDINGS & FURTHER RECOMMENDATIONS

Given previous nephrectomy with confirmed right kidney neoplasia, the current ill-defined mass, nodular omentum, lymphadenopathy and effusion are consistent with diffuse metastatic criteria, i.e. carcinomatosis. Correlation with mass/omental FNA cytology and effusion analysis could be considered with oncology consult.

Unfortunately, an unfavorable prognosis is indicated. Three view chest radiographs are recommended if not done.



PATIENT

Daisy Parikh

SPECIES

Canine

BREED

Lhasa Apso

SEX

Spayed Female

AGE

8 Years

WEIGHT

18 pounds

INTERPRETED BY

R. McKenzie Daniel,
DVM, DABVP (Canine
/ Feline Practice)

**IMAGING
PERFORMED BY**

Dr. Sreenivasa
Maddineni

HOSPITAL NAME

West Babylon Animal
Hospital

REFERRING VET

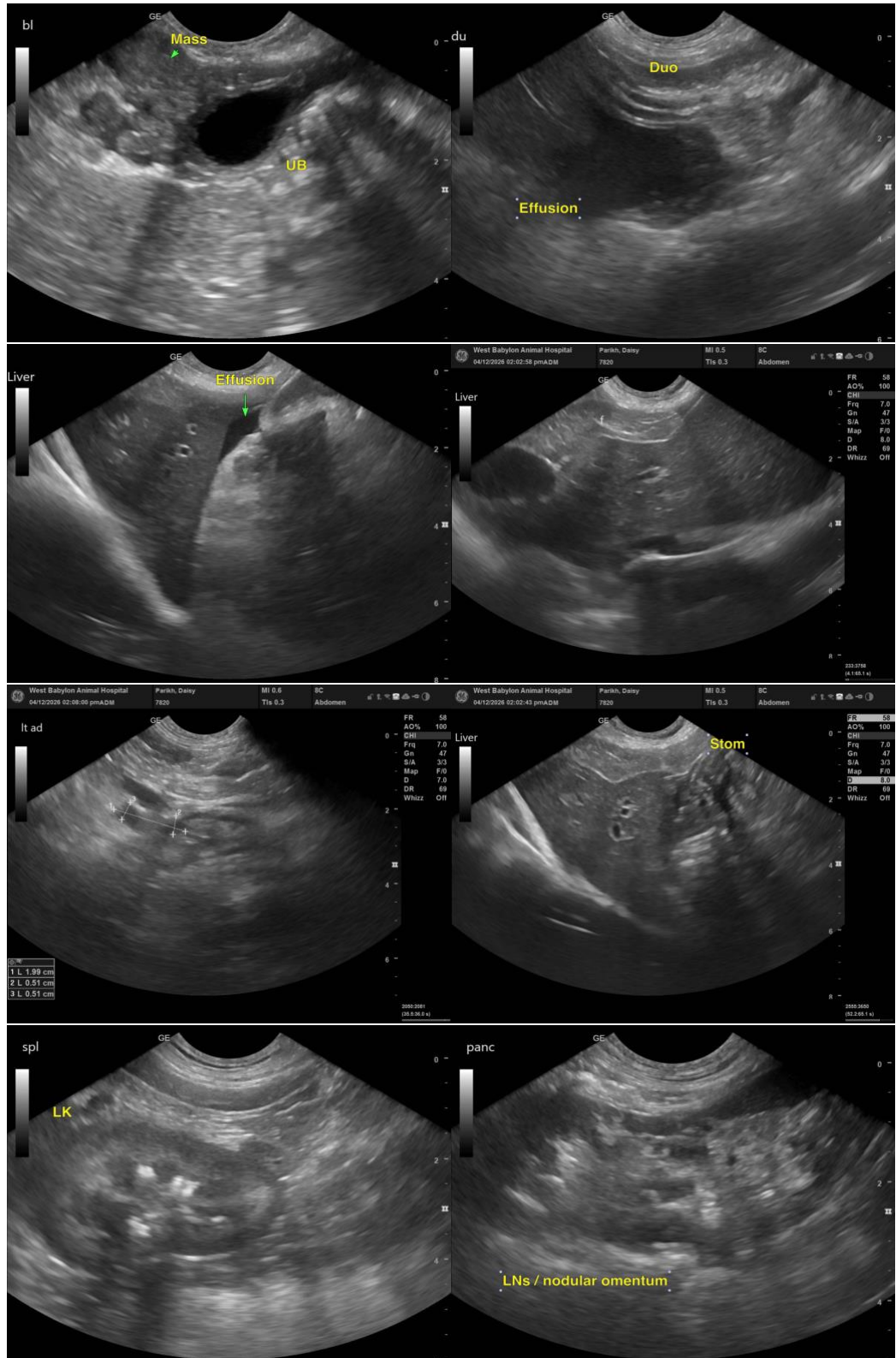
Dr. Sreenivasa
Maddineni

INVOICE

15037

DATE

04/12/26





PATIENT

Daisy Parikh

SPECIES

Canine

BREED

Lhasa Apso

SEX

Spayed Female

AGE

8 Years

WEIGHT

18 pounds

INTERPRETED BY

R. McKenzie Daniel,
DVM, DABVP (Canine
/ Feline Practice)

IMAGING PERFORMED BY

Dr. Sreenivasa
Maddineni

HOSPITAL NAME

West Babylon Animal
Hospital

REFERRING VET

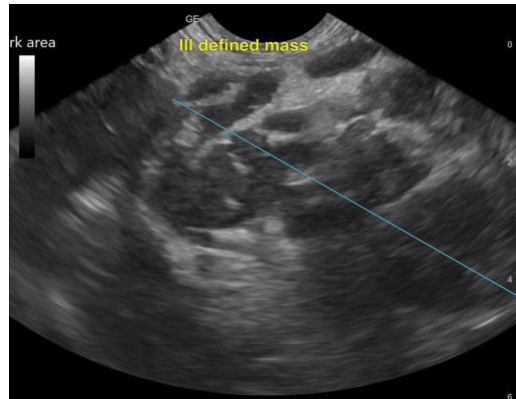
Dr. Sreenivasa
Maddineni

INVOICE

15037

DATE

04/12/26



The information and recommendations provided are based on the images presented by the referring veterinarian/sonographer. No evaluation can be communicated regarding pathology that was not visible in the image/video clips provided.

Thank you for this referral. If the clinical or image interpretation does not parallel your findings or if I can be of any further assistance, please contact me.

R. McKenzie Daniel, DVM, DABVP (Canine / Feline Practice)

info@SonoPath.com