



PATIENT	PRESENTING CLINICAL SIGNS
Archie Kump	Mild azotemia, pyuria, hematuria, isosthenuria on UA. Negative urine culture, PU/PD. Pyuria improved after 10 days of Clavaseptin but worsened azotemia. PU/PD improved. Concern for pyelonephritis. Has started Zeniquin.
SPECIES	
Canine	Abnormal PE/Chem/CBC/UA Results: 3/16/23 creatinine 213(44-159) BUN 18.7(2.5-9.6) 4/4/23 Creatinine 239 BUN 30.1 SDMA 25. Lepto witness test negative. Urinalysis - WBCs 5/hpf, RBCs 5/hpf, Cocci 1-2+, Sp. Grav 1.006
BREED	
Old English Sheepdog	
SEX	
MI	The urinary bladder was mildly distended in size exhibiting normal tone. Anechoic urine was present with minor, nondependent, particulate sediment, which may indicate cellular debris / protein, crystalline debris, or mucus. The urethra exhibited normal structure and tone to a depth of 3.0 cm.
AGE	
1 years	The prostate was enlarged in size with an intact, symmetrical capsule contour. The margins of the gland were intact and able to be differentiated from the surrounding tissue. The prostatic parenchyma was mildly echogenic to heteroechoic without parenchymal mineralization. The prostate measured 3.9 cm diameter. No evidence of regional periprostatic inflammation was noted.
WEIGHT	
36.4 kg	The area of the aortic trifurcation was free of pathology.
INTERPRETED BY	
R. McKenzie Daniel, DVM, DABVP	Adequate to normal size was noted in the kidneys with primarily maintained symmetrical capsule contour. Mild cortical hypertrophy was noted with mild nonuniform Increased cortex echogenicity and mild to moderate loss of corticomedullary border distinction. Adequate medullary volume was present with discrete areas of pinpoint dystrophic medullary mineral. No pyelectasia was visualized. No evidence of left or right retroperitoneal inflammatory criteria was noted. The left kidney measured 7.1 cm in length. The right kidney measured 8.0 cm in length.
IMAGING PERFORMED BY	
Crystal Hill	
HOSPITAL NAME	
Hartzel AH	
REFERRING VET	
Dr. Morris	
INVOICE	
16562	
DATE	
4/11/23	

ULTRASONOGRAPHIC EXAMINATION OF THE ABDOMEN

Urinary System

The urinary bladder was mildly distended in size exhibiting normal tone. Anechoic urine was present with minor, nondependent, particulate sediment, which may indicate cellular debris / protein, crystalline debris, or mucus. The urethra exhibited normal structure and tone to a depth of 3.0 cm.

The prostate was enlarged in size with an intact, symmetrical capsule contour. The margins of the gland were intact and able to be differentiated from the surrounding tissue. The prostatic parenchyma was mildly echogenic to heteroechoic without parenchymal mineralization. The prostate measured 3.9 cm diameter. No evidence of regional periprostatic inflammation was noted.

The area of the aortic trifurcation was free of pathology.

Adequate to normal size was noted in the kidneys with primarily maintained symmetrical capsule contour. Mild cortical hypertrophy was noted with mild nonuniform Increased cortex echogenicity and mild to moderate loss of corticomedullary border distinction. Adequate medullary volume was present with discrete areas of pinpoint dystrophic medullary mineral. No pyelectasia was visualized. No evidence of left or right retroperitoneal inflammatory criteria was noted. The left kidney measured 7.1 cm in length. The right kidney measured 8.0 cm in length.

Adrenal Glands

The left adrenal gland was uniform in size and contour with a uniformly hypoechoic parenchyma. The left adrenal gland measured 0.48 cm width at the caudal pole. No overt pathology was noted in the area of the right adrenal gland.

Spleen

The spleen exhibited a finely textured and homogenous parenchyma which was hyperechoic to the liver and renal cortical parenchyma. The capsule was smooth and regular without apparent expansion. The splenic vasculature at the hilus was normal in volume with no evidence of congestion or thrombosis. Acute to chronic inflammatory, neoplastic, or benign parenchyma changes were not noted.

Liver/ Gallbladder

The liver was subjectively normal in size, structure, and contour. The liver parenchyma was uniform and hypoechoic to the spleen with a mild coarse echotexture. The hepatic and portal vasculature were



PATIENT	normal in appearance without signs of congestion. The gallbladder was non-distended in size with thin walls and primarily anechoic luminal content. The cystic and common bile ducts were normal.
Archie Kump	
SPECIES	Gastrointestinal
Canine	The stomach presented intact wall layering with a normal wall layer ratio. The lumen of the stomach contained minor ingesta, sonographically consistent with food, was present in the gastric lumen without signs of obstruction or foreign material.
BREED	The small intestine presented intact wall layering with 1:3 muscularis/mucosa ratio. The lumen of the small intestine was empty with no signs of ileus, obstruction, or foreign material.
Old English Sheepdog	Normal visible colon wall layers were present with apparent formed feces in lumen.
SEX	Pancreas
MI	The parenchyma of the left limb, body, and right limb of the pancreas presented isoechoic to the adjacent omental fat. A normal curvilinear capsule contour of the pancreas was present. The visible pancreatic duct was normal. No signs of active inflammation or neoplastic disease were evident.
AGE	Free Abdomen
1 years	No overt lymphadenopathy or peritoneal effusion was present.
WEIGHT	ULTRASONOGRAPHIC FINDINGS
36.4 kg	Primary Findings
INTERPRETED BY	<ul style="list-style-type: none"> Bilateral chronic nephritis pattern exhibiting hyperechoic cortex and loss of corticomedullary border distinction Minor urinary bladder sediment
R. McKenzie Daniel, DVM, DABVP	Secondary Findings
IMAGING PERFORMED BY	<ul style="list-style-type: none"> Mild benign prostatic hyperplasia - expected prostatic presentation for a young, intact male canine, no overt prostatitis
Crystal Hill	INTERPRETATION OF THE FINDINGS & FURTHER RECOMMENDATIONS
HOSPITAL NAME	Sonographically, the appearance of the kidneys was consistent with chronic nephropathy and suspected chronic nonspecific nephritis with considerations including interstitial nephritis, pyelonephritis, and glomerulonephritis, although no reported significant proteinuria. Potential for some degree of renal dysplasia is possible, given the young age of the patient, yet overall bilateral renal size was adequate. A renal biopsy would be required for a definitive diagnosis. Recheck urine C/S on a sterile urine sample is suggested 7 days post-completion of the current antibiotic. Baseline UPC level could be considered if no significant evidence of inflammatory sediment on urinalysis. Pending further renal staging, essential CKD therapy and monitoring of systemic BP are suggested. Guarded long-term prognosis is indicated, given the sonographic appearance of the kidneys.
Hartzel AH	
REFERRING VET	
Dr. Morris	
INVOICE	
16562	
DATE	
4/11/23	



PATIENT

Archie Kump

SPECIES

Canine

BREED

Old English Sheepdog

SEX

MI

AGE

1 years

WEIGHT

36.4 kg

INTERPRETED BY

R. McKenzie Daniel,
DVM, DABVP

**IMAGING
PERFORMED BY**

Crystal Hill

HOSPITAL NAME

Hartzel AH

REFERRING VET

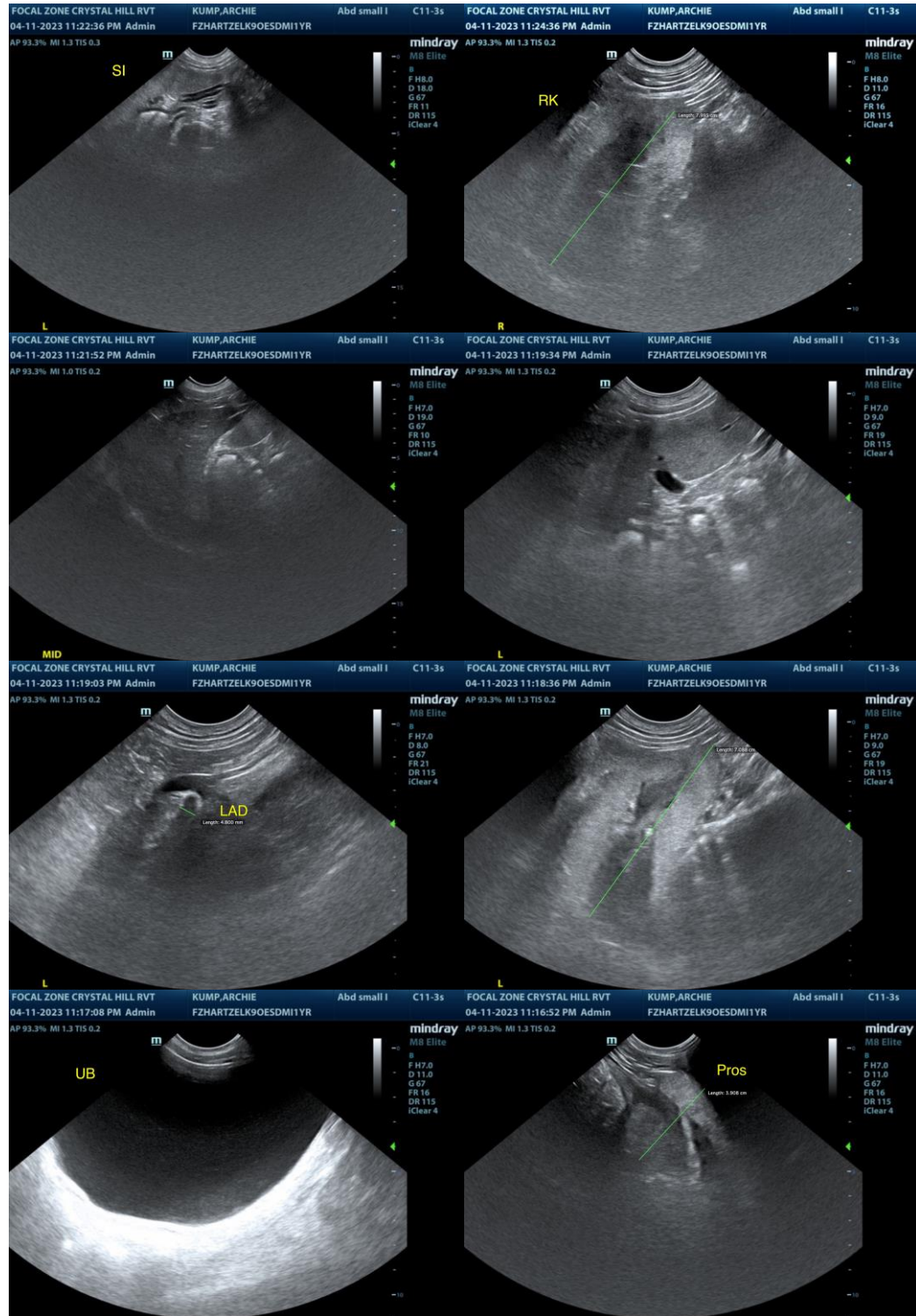
Dr. Morris

INVOICE

16562

DATE

4/11/23



The information and recommendations provided are based on the images presented by the referring veterinarian/sonographer. No evaluation can be communicated regarding pathology that was not visible in the image/video clips provided.

Thank you for this referral. If the clinical or image interpretation does not parallel your findings or if I



PATIENT

can be of any further assistance please contact me.

Archie Kump

SPECIES

Canine

BREED

Old English Sheepdog

SEX

MI

AGE

1 years

WEIGHT

36.4 kg

INTERPRETED BY

R. McKenzie Daniel,
DVM, DABVP

**IMAGING
PERFORMED BY**

Crystal Hill

HOSPITAL NAME

Hartzel AH

REFERRING VET

Dr. Morris

INVOICE

16562

DATE

4/11/23