SonoPath
Clinical Sonography & Telecytology
EDUCATIONAL TELECONSULTATION SERVICES™
1-800-838-4268 info@sonopath.com SonoPath.com

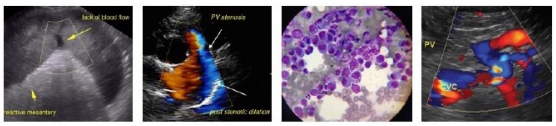

THE FOCAL ZONE
IMAGING PERFORMED BY
289-808-2608 info@thefocalzone.com

PATIENT

Pluto Parker

SPECIES

Canine

BREED

Malamute

SEX

Neutered Male

AGE

11 Years

WEIGHT

60 kg

INTERPRETED BY

R. McKenzie Daniel, DVM, DABVP (Canine and Feline)

IMAGING PERFORMED BY

Kelly Reschny

HOSPITAL NAME

Hillview Vet Clinic

REFERRING VET

Dr. Stevenson

INVOICE

36789

DATE

4/11/22

PRESENTING CLINICAL SIGNS

unable to hear heart , too big and heavy panting RR panting bcs 8/9 moderate muscle wastage back end weight loss, concern for cushings, pancreatic or liver changes
Abnormal PE/Chem/CBC/UA Results: Unremarkable CBC. Chem – Calcium 3.1, ALP 592, ALT 422, Glob 44, Spec cPL 320.

ULTRASONOGRAPHIC EXAMINATION OF THE ABDOMEN

Urinary System

The urinary bladder exhibited normal thickness and tone. Anechoic urine was present in the lumen with no uroliths or sediment. The ureteral papillae were normal. The ureters were not visible which is normal. No evidence of inflammatory or neoplastic changes were noted.

No overt pathology in the area of the residual prostate.

Normal size and margination were present in the kidneys. A normal 1:3 cortex / medulla ratio was maintained. The medulla and cortices were uniform in texture with some increased echogenicity and loss of corticomedullary symmetry and definition expected for the age of the patient. No evidence of pelvic dilation was present. The left kidney measured 8.0 cm. The right kidney measured 9.2 cm.

Adrenal Glands

The left adrenal gland was uniform in size and contour, isoechoic to adjacent periadrenal omentum. The left adrenal gland measured 0.84 cm at the cranial pole and 0.91 cm at the caudal pole.

The right adrenal gland was indistinctly visualized, given patient size and conformation, without evidence of overt pathology. The right adrenal gland subjectively measured 0.89 cm at the caudal pole.

Spleen

The spleen exhibited a finely textured and homogenous parenchyma which was hyperechoic to the liver and renal cortical parenchyma. The capsule was smooth and regular without apparent expansion. The splenic vasculature at the hilus was normal in volume with no evidence of congestion or thrombosis. Acute to chronic inflammatory, neoplastic, or benign parenchyma changes were not noted.

Liver

The liver exhibited potential for mild generalized enlargement. The liver parenchyma was mildly nonuniform and hypoechoic to the spleen with a moderate coarse echotexture and subjective mild to benign parenchymal remodeling. The hepatic and portal vasculature were normal in appearance without signs of congestion. The gallbladder was non distended in size with mild, echogenic, nonmineralized biliary sludge. The cystic duct and common bile ducts were normal without evidence of dilation.

Gastrointestinal

The stomach presented intact wall layering with a normal wall layer ratio. The lumen of the stomach contained moderate ingesta exhibiting progressive distal acoustic shadowing.

The small intestine presented intact wall layering with 1:3 muscularis/mucosa ratio. The lumen of the small intestine was empty with no signs of ileus, obstruction or foreign material.

Normal visible colon wall layers were present with apparent formed feces in lumen.

SonoPath
Clinical Sonography & Telecytology
EDUCATIONAL TELECONSULTATION SERVICES™
1-800-838-4268 info@sonopath.com SonoPath.com

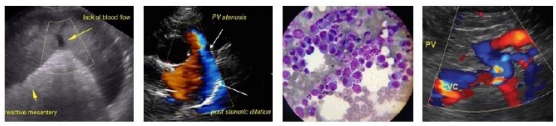

THE FOCAL ZONE
IMAGING PERFORMED BY
289-808-2608 info@thefocalzone.com

PATIENT
Pluto Parker

SPECIES
Canine

BREED
Malamute

SEX
Neutered Male

AGE
11 Years

WEIGHT
60 kg

INTERPRETED BY
R. McKenzie Daniel, DVM, DABVP (Canine and Feline)

IMAGING PERFORMED BY
Kelly Reschny

HOSPITAL NAME
Hillview Vet Clinic

REFERRING VET
Dr. Stevenson

INVOICE
36789

DATE
4/11/22

Pancreas

The parenchyma of the left limb, body and right limb of the pancreas presented isoechoic to the adjacent omental fat. A normal curvilinear capsule contour of the pancreas was present. The visible pancreatic duct was normal. No signs of active inflammation or neoplastic disease was evident.

Free Abdomen

No omental masses, lymphadenopathy or effusion.

ULTRASONOGRAPHIC FINDINGS

- Hepatopathy exhibiting generalized mildly non-uniform parenchyma
- Mild gallbladder debris (non-mucocele)
- Mild chronic renal changes
- Sonographically unremarkable gastrointestinal tract with moderate progressively shadowing gastric ingesta

INTERPRETATION OF THE FINDINGS & FURTHER RECOMMENDATIONS

The hepatic presentation is non-specific with potential considerations including vacuolar hepatopathy, inflammatory/immune mediated disease with benign parenchymal remodeling, indistinct areas of nodular hyperplasia, fibrosis, extramedullary hematopoiesis, infiltrative neoplasia (thought less likely), or other hepatopathy.

Assuming normal clotting status, hepatic FNA using 25-gauge needle could be considered for screening cytology. Pending hepatic cytology, hepatosupportive medications including Denamarin and Ursodiol may prove beneficial. Adrenal testing could be considered if clinical signs strongly support of adrenal hyperfunction are present. However, the bilateral adrenal gland and hepatic presentation was not overtly suggestive of hyperadrenocorticism. No overt evidence of pancreatic pathology, although potential for low-grade to chronic pancreatitis could be present, yet sonographically normal. Correlation with clinical signs and history suggested.

A GI panel to include PLI/TLI/Cobalamin/Folate as well as three view chest radiographs and neurological examination are recommended to assess for or rule out occult disease which may cause weight loss.

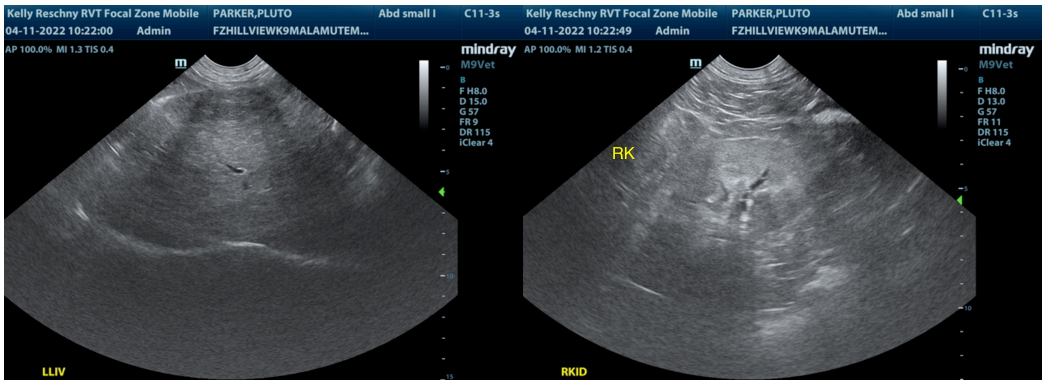

SonoPath
Clinical Sonography & Telecytology
EDUCATIONAL TELECONSULTATION SERVICES™
1-800-838-4268 info@sonopath.com SonoPath.com

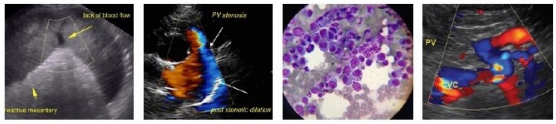

THE FOCAL ZONE
IMAGING PERFORMED BY
289-808-2608 info@thefocalzone.com

PATIENT

Pluto Parker

SPECIES

Canine

BREED

Malamute

SEX

Neutered Male

AGE

11 Years

WEIGHT

60 kg

INTERPRETED BY

R. McKenzie Daniel, DVM, DABVP (Canine and Feline)

IMAGING PERFORMED BY

Kelly Reschny

HOSPITAL NAME

Hillview Vet Clinic

REFERRING VET

Dr. Stevenson

INVOICE

36789

DATE

4/11/22

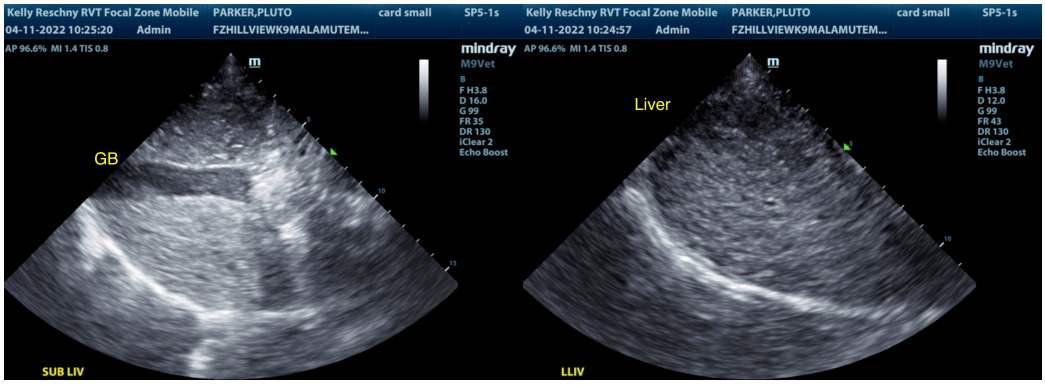

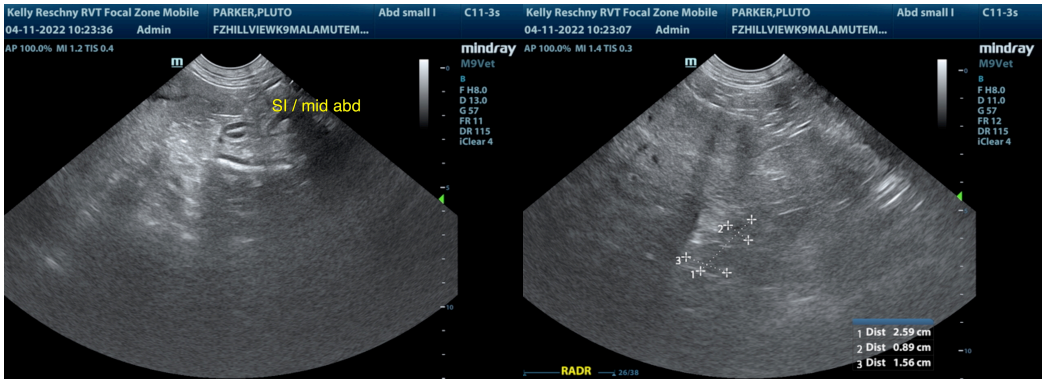

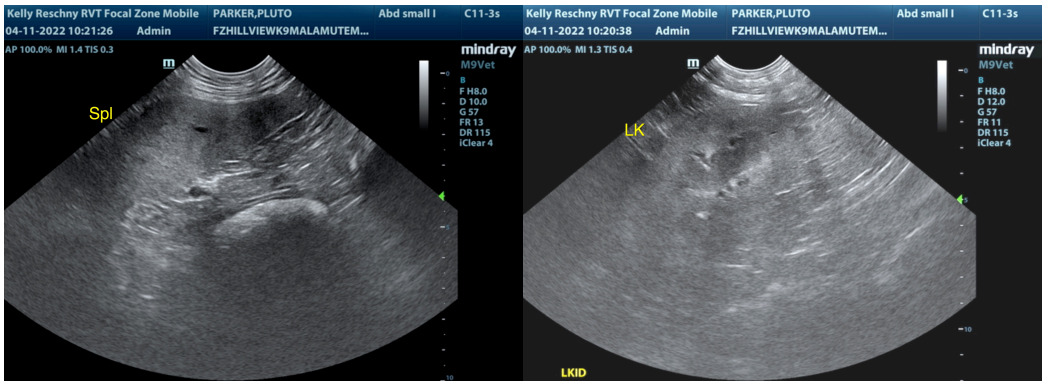

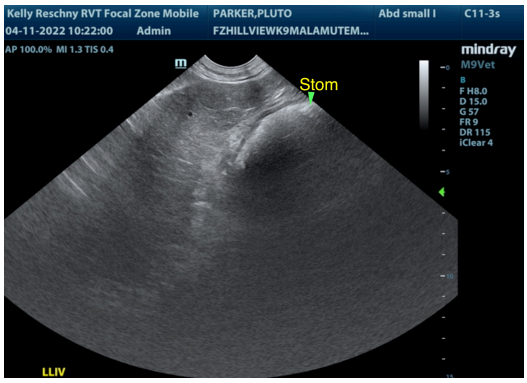

SonoPath
Clinical Sonography & Telecytology
EDUCATIONAL TELECONSULTATION SERVICES™
1-800-838-4268 info@sonopath.com SonoPath.com

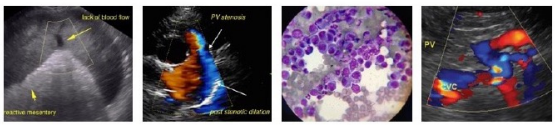

THE FOCAL ZONE
IMAGING PERFORMED BY
289-808-2608 info@thefocalzone.com

PATIENT

Pluto Parker

SPECIES

Canine

BREED

Malamute

SEX

Neutered Male

AGE

11 Years

WEIGHT

60 kg

INTERPRETED BY

R. McKenzie Daniel, DVM, DABVP (Canine and Feline)

IMAGING PERFORMED BY

Kelly Reschny

HOSPITAL NAME

Hillview Vet Clinic

REFERRING VET

Dr. Stevenson

INVOICE

36789

DATE

4/11/22

The information and recommendations provided are based on the images presented by the referring veterinarian/sonographer. No evaluation can be communicated regarding pathology that was not visible in the image/video clips provided.

Thank you for this referral. If the clinical or image interpretation does not parallel your findings or if I can be of any further assistance please contact me.

R. McKenzie Daniel, DVM, DABVP (Canine / Feline Practice)

info@SonoPath.com