

## PATIENT PRESENTING CLINICAL SIGNS

**PATIENT** Mylo Mainelli

**SPECIES** Canine

**BREED** Shepherd X

Sudden onset of panting starting last night about 7pm, 2 episodes of attempting to vomit but not productive. Lethargic, shaking. No diarrhea, coughing or sneezing. No known toxins.(but did test positive for amphetamines and Oxy on Urine test) No heart murmur. HR 112, RR panting. Has been on Baytril, Ampicillin, Metronidazole, Torbugesic and Cerenia. Was taken to emerg with concerns for Bloat/GDV. Ruled out bloat on rads - see report. After Cerenia and Torbugesic given, he rested well and no further attempts to vomit. Concerned re: Splenomegaly, pneumonia.  
Abnormal PE/Chem/CBC/UA Results: Please see attached bloodwork and rad report. Urine sp grav-1.025, trace protein, blood 250, pH 7.0

## ULTRASONOGRAPHIC EXAMINATION OF THE HEART & ABDOMEN

### SEX

Neutered Male

### AGE

4 Years

### WEIGHT

47.6 kg

### INTERPRETED BY

R. McKenzie Daniel,  
DVM, DABVP  
(Canine and Feline)

### IMAGING PERFORMED BY

Crystal Hill

### HOSPITAL NAME

BPH Burlington

### REFERRING VET

Dr. Nozomi

### INVOICE

36776

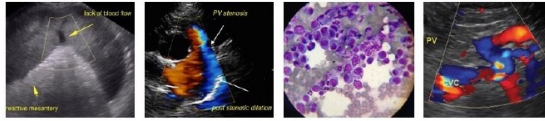
### DATE

4/11/22

CANINE CARDIAC PARAMETERS	MR VMAX (m/s)	TR VMAX (m/s)	LA/AO (Boon method)	LA/AO (Heart Base; Swe)	FS (%)	EF (%)	EPSS (cm)
NORMAL PARAMETER	4.5-5.5	<2.7	1.3	<1.6	28-40	40-100	<0.6
PATIENT			NM	1.38	33.3	65.6	0.39
CANINE CARDIAC PARAMETERS	HR (BPM)	AV VMAX (m/s)	PV MAX (m/s)	BODY WEIGHT (kg)	LA 2D short axis Base view (cm)	LVIDd Avg; 2D and m-mode short axis (cm)	LVIDs Avg; 2D and m-mode short axis (cm)
NORMAL PARAMETER	50-100	0.7-1.7	0.7-1.6	BELOW	BELOW	BELOW	BELOW
PATIENT	NM	1.5	1.2		3.9	3.9	

### Cardiac Presentation

The echocardiogram in this patient demonstrated normal **left atrial** size based on 3 separate methods of LA evaluation. The cranial and caudal **mitral** valve leaflets presented normal linear structure, extension in systole, and union in diastole with normal kinesis. The **left ventricle** presented thicknesses with linear contour and was not dilated nor restricted. The **myocardium** presented normal echogenicity without subjective evidence of significant fibrotic or ischemic disease. **Contractility** of the ventricular walls was adequate and in normal range for this patient evidenced by the fractional shortening measurement and subjective evaluation of the different regions of the myocardium. The **left ventricular outflow** tract demonstrated normal laminar flow and subjective structural integrity. The **right atrium** and auricle revealed normal size, structure and content. No evidence of overt or visualized masses. **Tricuspid** valvular assessment demonstrated adequate linear morphology and kinesis. The **right ventricle** was of normal size (1/3 diameter of LV), chordae structure, myocardial echogenicity and thickness. **Pulmonary outflow** tract assessment revealed normal subjective valve structure, laminar systolic flow, and normal diameter (approx. 1:1 pa/ao ratio). Color doppler assessment revealed minor pulmonic valve insufficiency measuring 1.0 cm in diastolic velocity. Scant to mild volume free pleural fluid was present without evidence of concurrent pericardial free fluid. The cranial mediastinum, pericardial and extracardiac regions were free of overt or visualized masses in the visible window.



**PATIENT**

**Urinary System**

Mylo Mainelli

The urinary bladder, trigone, cystourethral junction, and visible pelvic urethra to a depth of 2.0 cm exhibited normal thickness and tone. Anechoic urine was present in the lumen with no uroliths or sediment. The ureteral papillae were normal. The ureters were not visible which is normal. No evidence of inflammatory or neoplastic changes were noted.

**SPECIES**

Canine

Normal size and margination were present in the kidneys. A normal 1:3 cortex / medulla ratio and normal corticomedullary definition were maintained. The echogenicity of the cortex was similar to or slightly less than normal liver parenchyma while the medulla echogenicity was hypoechoic to the cortex with no evidence of pelvic dilation. The left kidney measured 8.5 cm. The right kidney measured 7.7 cm.

**BREED**

Shepherd X

The area of the aortic trifurcation was free of pathology.

**SEX**

Neutered Male

**Adrenal Glands**

The adrenal glands were indistinctly visualized owing to patient size and conformation, yet without evidence of overt pathology. The left adrenal gland subjectively measured 2.8 cm length x 0.85 cm. The right adrenal gland subjectively measured 2.2 cm length x 0.82 cm.

**AGE**

4 Years

**Spleen**

The spleen exhibited subjective mild generalized enlargement with maintained symmetrical capsule contour and finely textured homogeneous splenic parenchyma. No splenic masses or nodules noted. Normal splenic vascularity.

**WEIGHT**

47.6 kg

**Liver**

The liver was subjectively normal in size, structure, and contour. The liver parenchyma was uniform and hypoechoic to the spleen with a mild coarse echotexture. The hepatic and portal vasculature were normal in appearance without signs of congestion. The gallbladder was non-distended in size with thin walls and primarily anechoic luminal content. The cystic and common bile ducts were normal.

**INTERPRETED BY**

R. McKenzie Daniel,  
DVM, DABVP  
(Canine and Feline)

**Gastrointestinal**

The stomach presented intact wall layering with a normal wall layer ratio. Minor retained non-shadowing, echogenic fluid and chyme present.

**IMAGING PERFORMED BY**

Crystal Hill

The small intestine presented intact wall layering with 1:3 muscularis/mucosa ratio. The lumen of the small intestine was empty with no signs of ileus, obstruction or foreign material.

**HOSPITAL NAME**

BPH Burlington

Normal visible colon wall layers were present with apparent formed feces in lumen.

**REFERRING VET**

Dr. Nozomi

**Pancreas**

The parenchyma of the left limb, body and right limb of the pancreas presented isoechoic to the adjacent omental fat. A normal curvilinear capsule contour of the pancreas was present. The visible pancreatic duct was normal. No signs of active inflammation or neoplastic disease was evident.

**Free Abdomen**

No overt lymphadenopathy or peritoneal effusion was present.

**INVOICE**

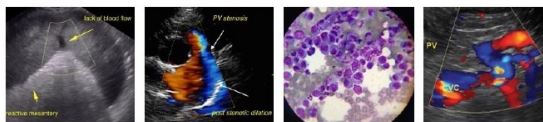
36776

**ULTRASONOGRAPHIC FINDINGS**

**DATE**

4/11/22

- Mild splenomegaly – subjectively benign.
- Overtly normal gastrointestinal tract with mild retained gastric ingesta/chyme



## PATIENT

Mylo Mainelli

## SPECIES

Canine

## BREED

Shepherd X

## SEX

Neutered Male

## AGE

4 Years

## WEIGHT

47.6 kg

## INTERPRETED BY

R. McKenzie Daniel,  
DVM, DABVP  
(Canine and Feline)

## IMAGING PERFORMED BY

Crystal Hill

## HOSPITAL NAME

BPH Burlington

## REFERRING VET

Dr. Nozomi

## INVOICE

36776

## DATE

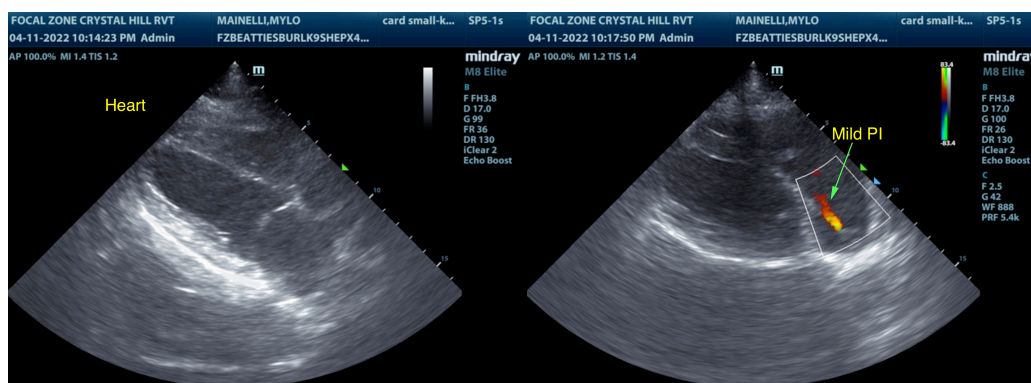
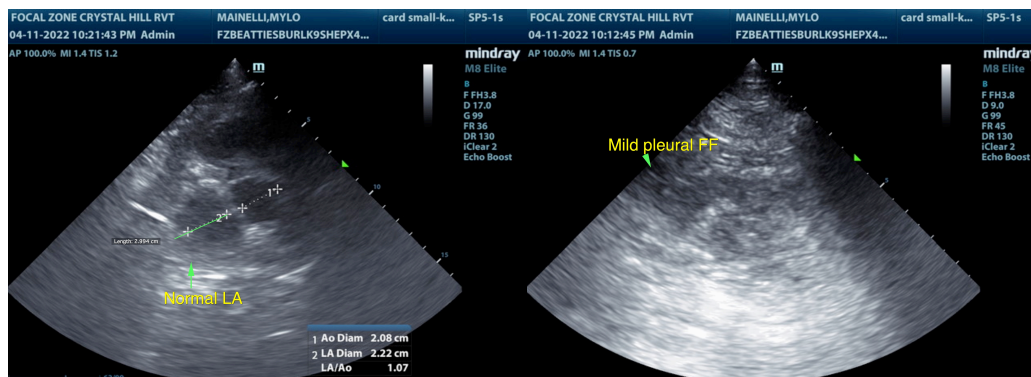
4/11/22

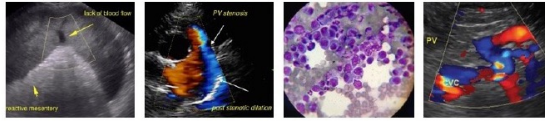
## INTERPRETATION OF THE FINDINGS & FURTHER RECOMMENDATIONS

Overall, no overt evidence of cardiac or abdominal visceral pathology. The minor pleural effusion in this case appears to be non-cardiogenic and potentially secondary or associated to radiographically diagnosed pneumonia. If clinically indicated, thoracocentesis for effusion analysis, cytology +/- culture and sensitivity could be considered, although the volume of pleural effusion at the time of the ultrasound appeared to be minor to mild.

The subjective splenomegaly may indicate patient variant, mild breed associated hypersplenism, hyperplasia, hematopoiesis, or potential concurrent or incidental splenitis without evidence of neoplastic criteria. Some contribution to the splenomegaly from sedation may also be possible. Ultrasound guided splenic FNA using 25-gauge needle and assuming normal clotting status may be considered if persistent splenomegaly or primary to ensure only benign change are present.

Empirical therapy for mild gastritis/gastroenteritis or potential minor gastric hypomotility would be reasonable.





**PATIENT**

Mylo Mainelli

**SPECIES**

Canine

**BREED**

Shepherd X

**SEX**

Neutered Male

**AGE**

4 Years

**WEIGHT**

47.6 kg

**INTERPRETED BY**

R. McKenzie Daniel,  
DVM, DABVP  
(Canine and Feline)

**IMAGING PERFORMED BY**

Crystal Hill

**HOSPITAL NAME**

BPH Burlington

**REFERRING VET**

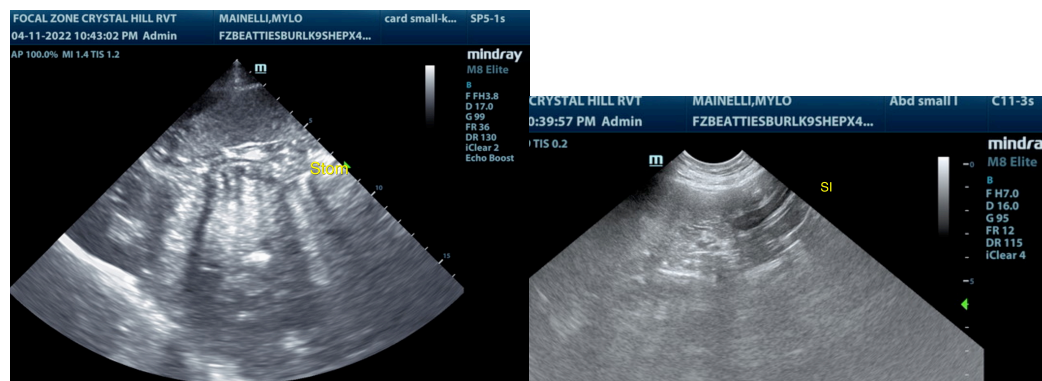
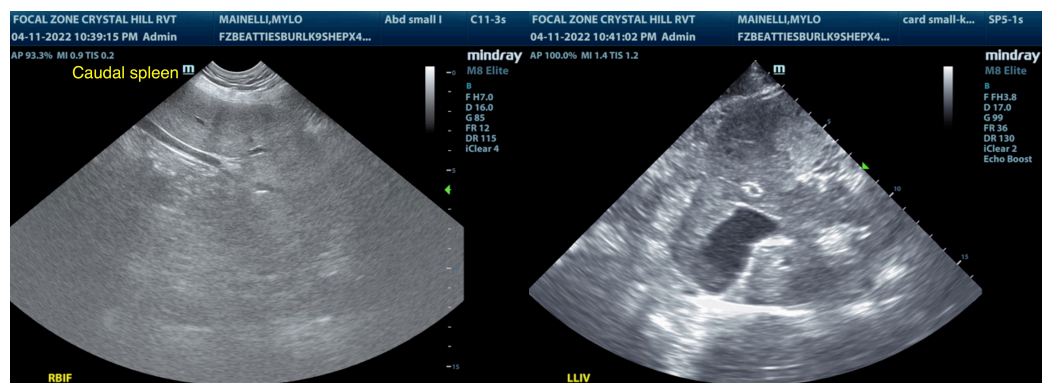
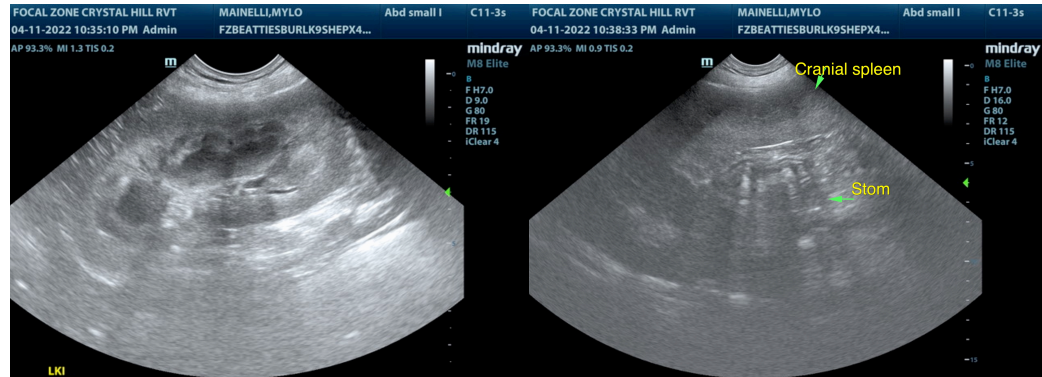
Dr. Nozomi

**INVOICE**

36776

**DATE**

4/11/22



The information and recommendations provided are based on the images presented by the referring veterinarian/sonographer. No evaluation can be communicated regarding pathology that was not visible in the image/video clips provided.

Thank you for this referral. If the clinical or image interpretation does not parallel your findings or if I can be of any further assistance please contact me.

**R. McKenzie Daniel, DVM, DABVP (Canine / Feline Practice)**

info@SonoPath.com