

PATIENT PRESENTING CLINICAL SIGNS

Max Sullivan PU/PD; progressive abdominal distention. Intermittent bilous emesis. Melena was noticed in the past. Intermittent tan diarrhea. Active, eating well. No toxin exposure. UA/culture, LDDST pending.

SPECIES ULTRASONOGRAPHIC EXAMINATION OF THE ABDOMEN

Canine **Urinary System**

BREED

Dachshund

The urinary bladder, trigone, cystourethral junction, and visible pelvic urethra to a depth of – cm exhibited normal thickness and tone. Anechoic urine was present in the lumen with no uroliths or sediment. The ureteral papillae were normal. The ureters were not visible which is normal. No evidence of inflammatory or neoplastic changes were noted.

SEX

Neutered Male

The residual prostate was symmetrically normal in size with uniform parenchyma and slight coarse echotexture. The prostate measured 0.7 cm diameter.

AGE

12 Years

Normal size and margination was present in the kidneys. A normal 1:3 cortex / medulla ratio was maintained. The medulla and cortices were uniform in texture with some increased echogenicity and loss of corticomedullary symmetry and definition expected for the age of the patient. No evidence of pelvic dilation was present. The left kidney measured 5.0 cm. The right kidney measured 4.9 cm. Pinpoint medullary mineral noted in both kidneys.

Adrenal Glands

WEIGHT

9.8 kg

The bilateral adrenal glands were mildly prominent in size. The left adrenal gland was slightly enlarged compared to the right. The left adrenal gland measured 0.82 cm at the cranial pole and 1.0 cm at the caudal pole. Mild parenchyma heterogeneity and mild capsule asymmetry was present. The right adrenal gland measured 0.63 cm at the cranial pole and 0.60 cm at the caudal pole. The adrenal glands are not overtly suggestive of neoplastic criteria. Potential for minor early adenomatous change.

INTERPRETED BY

R. McKenzie Daniel, DVM, DABVP (Canine and Feline)

Spleen

IMAGING PERFORMED BY

Pamela Harrigan, RDCS

The spleen exhibited primarily finely textured parenchyma which was hyperechoic to the liver and renal cortical parenchyma. Mild generalized parenchyma heterogeneity was present without evidence of nodular changes. The capsule was smooth and regular without apparent expansion. Potential mild medial folding of the caudal spleen, which is not indicative of underlying splenic pathology and likely a patient variant. The splenic vasculature at the hilus was normal in volume with no evidence of congestion or thrombosis. The parenchymal heterogeneity is likely consistent with benign changes such as extramedullary hematopoiesis or age related remodeling with minor potential for inflammatory or neoplastic disease.

HOSPITAL NAME

New England AMC

Liver

REFERRING VET

Dr. Albert Fernandez

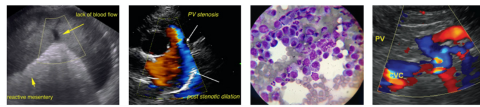
The liver exhibited subjective mild enlargement with normal structure and contour. The liver parenchyma was mildly nonuniform and hypoechoic to the spleen with a moderate coarse echotexture and subjective mild to benign parenchymal remodeling. Regional area of mildly non-homogeneous, hyperechoic parenchyma noted in the caudal left liver measuring approximately 3.0 cm in diameter. This area of hyperechoic parenchyma was non-expansive and did not result in distortion of the hepatic capsule. The hepatic and portal vasculature were normal in appearance without signs of congestion. The gallbladder was non-distended in size with thin walls. Anechoic content noted with non-dependent, mildly congealed yet mobile debris. The cystic and common bile ducts were normal.

INVOICE

36774

DATE

4/11/22



PATIENT *Gastrointestinal*

Max Sullivan The stomach presented intact wall layering with a normal wall layer ratio. The lumen of the stomach was empty with no signs of ileus, obstruction or foreign material.

SPECIES Canine The small intestine presented intact wall layering. Segmental mildly prominent duodenojejunal mucosal layer noted with intermittent segmental duodenojejunal mucosal speckling. Duodenum wall measured 0.39 cm. Jejunum wall measured 0.36 cm. The lumen of the small intestine was empty with no signs of ileus, obstruction or foreign material.

BREED Dachshund Normal visible colon wall layers were present with apparent formed feces in lumen.

SEX *Pancreas*

Neutered Male The parenchyma of the left limb, body and right limb of the pancreas presented isoechoic to the adjacent omental fat. A normal curvilinear capsule contour of the pancreas was present. The visible pancreatic duct was normal. No signs of active inflammation or neoplastic disease was evident.

ULTRASONOGRAPHIC FINDINGS

- Non-specific hyperechoic hepatic parenchyma/nodule
- Moderate congealed yet mobile gallbladder debris (non-mucocele)
- Bilateral prominent, mildly non-homogeneous adrenal glands
- Sonographically unremarkable stomach, segmental non-specific duodenojejunal mucosal speckling

INTERPRETATION OF THE FINDINGS & FURTHER RECOMMENDATIONS

Pending adrenal workup with LDDST and assessment of systemic blood pressure for evidence of hypertension are warranted. Pending adrenal testing, sonographic monitoring of the bilateral adrenal glands for evidence of progressive non-homogeneous parenchymal changes and enlargement would be ideal.

The hepatic nodule, although non-specific, is not overtly suggestive of neoplastic criteria, with nodular/regenerative hyperplasia, lipogranuloma, regional fibrosis possible. Correlation with full lab work to assess hepatic enzymes and for evidence of cholestasis suggested. Ursodiol therapy recommended, if evidence of cholestasis.

The segmental small intestine exhibited subtle mural changes, which may indicate segmental inflammation. As needed GI support and potential hydrolyzed diet trial (if persistent/progressive gastrointestinal signs) may prove beneficial.

INTERPRETED BY

R. McKenzie Daniel, DVM,
 DABVP (Canine and Feline)

IMAGING PERFORMED BY

Pamela Harrigan, RDCS

HOSPITAL NAME

New England AMC

REFERRING VET

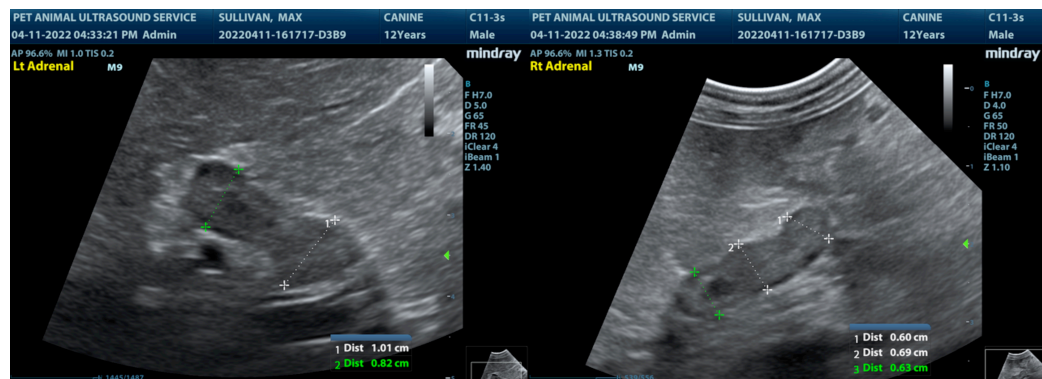
Dr. Albert Fernandez

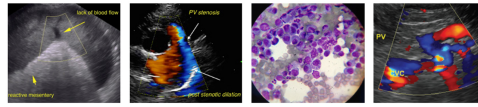
INVOICE

36774

DATE

4/11/22





PATIENT

Max Sullivan

SPECIES

Canine

BREED

Dachshund

SEX

Neutered Male

AGE

12 Years

WEIGHT

9.8 kg

INTERPRETED BY

R. McKenzie Daniel, DVM,
 DABVP (Canine and Feline)

IMAGING PERFORMED BY

Pamela Harrigan, RDCS

HOSPITAL NAME

New England AMC

REFERRING VET

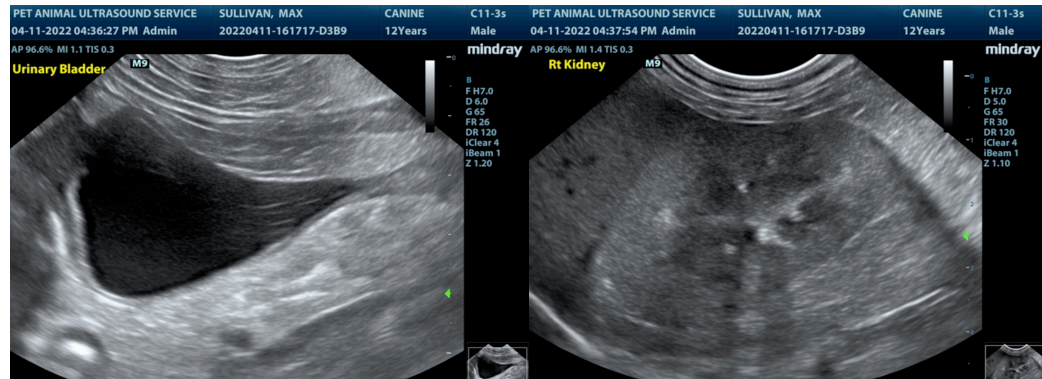
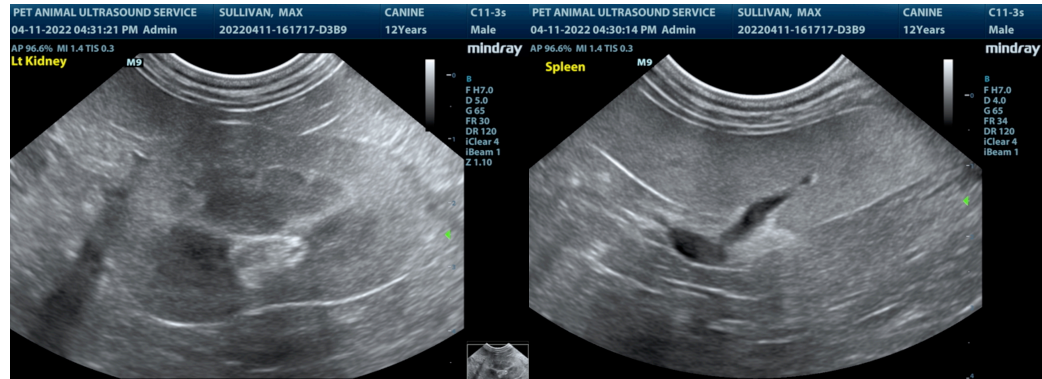
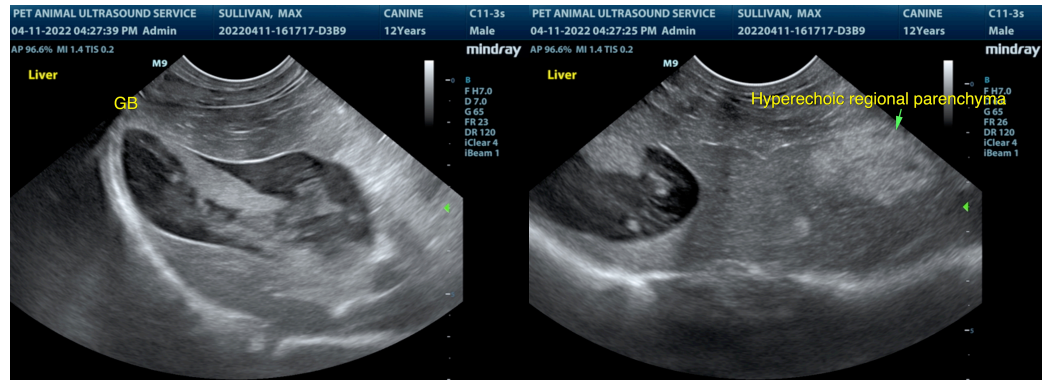
Dr. Albert Fernandez

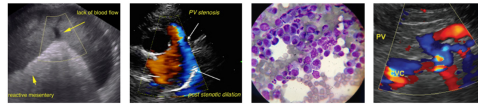
INVOICE

36774

DATE

4/11/22





PATIENT

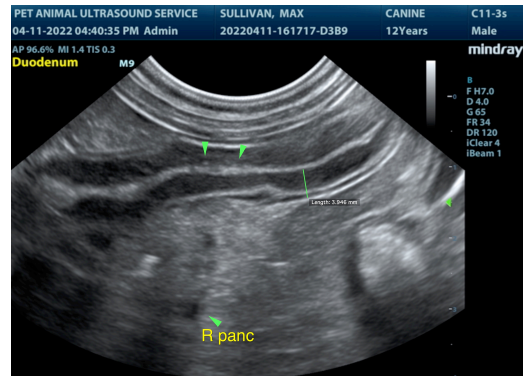
Max Sullivan

SPECIES

Canine

BREED

Dachshund



SEX

Neutered Male

The information and recommendations provided are based on the images presented by the referring veterinarian. No evaluation can be communicated regarding pathology that was not visible in the image/video clips provided.

AGE

12 Years

Thank you for this referral. If the clinical or image interpretation does not parallel your findings or if I can be of any further assistance please contact me.

WEIGHT

9.8 kg

R. McKenzie Daniel, DVM, DABVP (Canine / Feline Practice)
 info@SonoPath.com

INTERPRETED BY

R. McKenzie Daniel, DVM,
 DABVP (Canine and Feline)

IMAGING PERFORMED BY

Pamela Harrigan, RDCS

HOSPITAL NAME

New England AMC

REFERRING VET

Dr. Albert Fernandez

INVOICE

36774

DATE

4/11/22