



PATIENT PRESENTING CLINICAL SIGNS

PATIENT
Coco Gibson
History: pt has a history of recurrent UTIs. most recently on 4/4 pt was seen for polakiuria and hematuria. pt was placed on clavamox and gabapentin while awaiting culture results. O says that pt is still having hematuria.

SPECIES

Feline
Abnormal PE/Chem/CBC/UA Results: See attached results: Culture from urine collected on 4/4 showed no growth. The UA demonstrated a USG of 1.022, WBC 3/hpf, RBC >50/hpf

BREED

DSH

ULTRASONOGRAPHIC EXAMINATION OF THE URINARY TRACT

Urinary System

SEX

Spayed female

The urinary bladder presented normal in size and tone with anechoic urine and mild particulate sediment. No evidence of macro calculi or uroliths was observed. Focal mild thickening of the ventroapical urinary bladder wall was present, measuring approximately 1.0 cm x 0.67 cm. The focally thickened bladder wall exhibited homogeneous isoechoic mural echogenicity compared to adjacent non thickened apical and ventral bladder wall. No evidence of mural mineralization was observed. The trigone, cystourethral junction, and visible pelvic urethra to a depth of 2 cm exhibited normal thickness and tone with no evidence of pathology.

AGE

13 years

WEIGHT

13.6 pounds

Normal size and margination was present in the kidneys. A normal 1:3 cortex / medulla ratio was maintained. The medulla and cortices were uniform in texture with some mildly increased echogenicity and mild loss of corticomedullary symmetry and definition expected for the age of the patient. Minor pyelectasia was present in the right kidney. No evidence of concurrent right ureter dilation was noted.

INTERPRETED BY

R. McKenzie Daniel,
DVM, DABVP
(Canine and Feline)

The left kidney measured 3.6 cm in length. The right kidney measured 4.0 cm in length.

ULTRASONOGRAPHIC FINDINGS

- Mild focally thickened ventroapical bladder wall, mild particulate urinary bladder sediment.
- Mild chronic renal changes with minor right kidney pyelectasia.

IMAGING PERFORMED BY

Jasmine Palacios

INTERPRETATION OF THE FINDINGS & FURTHER RECOMMENDATIONS

HOSPITAL NAME

Rivers Edge Pet Medical
Center

The focally thickened ventroapical UB wall which appeared to be static throughout the ultrasound exam and without evidence of overtly adhered congealed sediment is nonspecific. Focal cystitis, given this presentation is considered a primary differential diagnosis although the possibility of emerging neoplastic criteria cannot be definitively excluded. No overt evidence of left or right renal pathology as a potential cause of the patient's hematuria was obvious. The mild pyelectasia present in the right kidney is nonspecific yet is suspected to be secondary to minor pelvic scarring or mild chronic renal changes without overt evidence of pyelonephritis. Empirical therapy for idiopathic cystitis with sonographic monitoring of the focally thickened ventroapical UB wall for evidence of progression with an initial recheck in 3-4 weeks would be reasonable.

REFERRING VET

Dr. Cora Hollomon

INVOICE

10335ag

DATE

04/11/2022



PATIENT

Coco Gibson

SPECIES

Feline

BREED

DSH

SEX

Spayed female

AGE

13 years

WEIGHT

13.6 pounds

INTERPRETED BY

R. McKenzie Daniel,
DVM, DABVP
(Canine and Feline)

**IMAGING
PERFORMED BY**
Jasmine Palacios

HOSPITAL NAME

Rivers Edge Pet Medical
Center

REFERRING VET

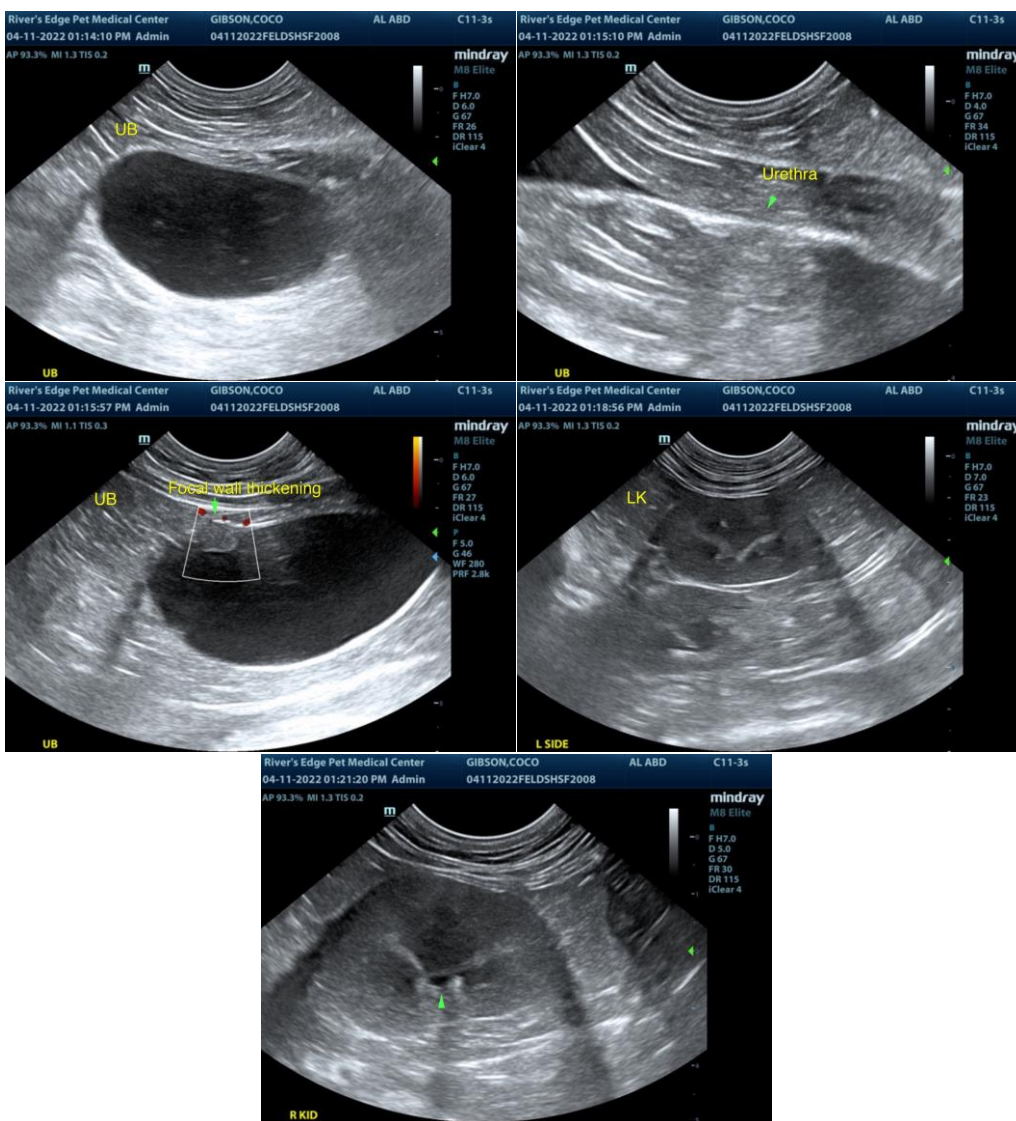
Dr. Cora Hollomon

INVOICE

10335ag

DATE

04/11/2022



The information and recommendations provided are based on the images presented by the referring veterinarian/sonographer. No evaluation can be communicated regarding pathology that was not visible in the image/video clips provided.

Thank you for this referral. If the clinical or image interpretation does not parallel your findings or if I can be of any further assistance please contact me.

R. McKenzie Daniel, DVM, DABVP (Canine / Feline Practice)

info@SonoPath.com



PATIENT

Coco Gibson

SPECIES

Feline

BREED

DSH

SEX

Spayed female

AGE

13 years

WEIGHT

13.6 pounds

INTERPRETED BY

R. McKenzie Daniel,
DVM, DABVP
(Canine and Feline)

**IMAGING
PERFORMED BY**

Jasmine Palacios

HOSPITAL NAME

Rivers Edge Pet Medical
Center

REFERRING VET

Dr. Cora Hollomon

INVOICE

10335ag

DATE

04/11/2022