



PATIENT

Zod Matles

SPECIES

Feline

BREED

DSH

SEX

Neutered Male

AGE

1 Year

WEIGHT

13.2 pounds

INTERPRETED BY

R. McKenzie Daniel,
 DVM, DABVP (Canine
 / Feline Practice)

IMAGING PERFORMED BY

Meghan Morse LVT,
 CVT

HOSPITAL NAME

Walden Animal Clinic

REFERRING VET

Dr. Dickey

INVOICE

15016

DATE

04/10/26

PRESENTING CLINICAL SIGNS

FUO. Possible mid abd mass? Littermate died of FIP @ 6 months of age. Hx of acute anorexia. No GI symptoms otherwise. Current med: Convenia

Abnormal PE/Chem/CBC/UA Results: Increased GLOB and T Bili

ULTRASONOGRAPHIC EXAMINATION OF THE ABDOMEN

Urinary System

The urinary bladder, trigone, cystourethral junction, and visible pelvic urethra to a depth of 3.0 cm exhibited normal thickness and tone. Anechoic urine was present in the lumen with minor urine sediment. The ureteral papillae were normal. The ureters were not visible which is normal. No evidence of inflammatory or neoplastic change were noted.

Normal size and margination was present in the kidneys. A normal 1:3 cortex / medulla ratio and normal corticomedullary definition were maintained. The echogenicity of the cortex was similar to or slightly less than normal liver parenchyma while the medulla echogenicity was hypoechoic to the cortex with no evidence of pelvic dilation. The left kidney measured 3.8 cm in length. The right kidney measured 4.0 cm in length.

Adrenal Glands

The adrenal glands were indistinctly visualized yet overtly normal in size, position and shape. The left adrenal gland measured 0.34 cm width. The right adrenal gland measured 0.35 cm width.

Spleen

The spleen was mildly enlarged and exhibited a finely textured and homogenous parenchyma which was hyperechoic to the liver and renal cortical parenchyma. The capsule was smooth and regular without apparent expansion. The splenic vasculature at the hilus was normal in volume with no evidence of congestion or thrombosis. Acute to chronic inflammatory, neoplastic, or benign parenchyma changes were not noted. The spleen measured 1.2 cm width level of the mid spleen.

Liver & Gallbladder

The liver was subjectively normal in size, structure, and contour. The liver parenchyma was uniform and hypoechoic to the spleen with a mild coarse echotexture. The hepatic and portal vasculature were normal in appearance without signs of congestion.

The gallbladder was non-distended in size with thin walls and primarily anechoic luminal content. The cystic and common bile ducts were normal.

Gastrointestinal

The stomach presented intact wall layering with a normal wall layer ratio. The lumen of the stomach was empty with no signs of ileus, obstruction or foreign material.

The visualized segments of small intestine exhibited intact wall layering and normal wall layer ratio with empty lumen. An example of the small intestine wall measured .23 cm wall width.

The visualized colon exhibited variably thickened wall and non-distended in size containing soft fecal matter. The descending colon wall measured 0.39 cm wall width.



PATIENT

Pancreas

Zod Matles

The pancreas was indistinctly visualized owing to increased peripancreatic omental artifact.

SPECIES

Free Abdomen

Feline

Intermittent variable to markedly enlarged nonhomogenous hypoechoic mesenteric lymph nodes were present. A larger lymph node measured 4.0 cm x 2.7 cm exhibiting width: length ratio >0.5.

BREED

Generalized nonhomogenous hyperechoic to nodular appearing omentum with a moderate volume of mildly echogenic peritoneal effusion.

DSH

ULTRASONOGRAPHIC FINDINGS

SEX

- Variably to markedly enlarged nonhomogenous hypoechoic mesenteric lymphadenopathy.
- Generalized nonhomogenous nodular omentum and moderate volume peritoneal effusion.
- Mild splenomegaly.
- Sonographically unremarkable visualized gastrointestinal tract.
- Thickened visualized colon containing soft fecal matter.

Neutered Male

AGE

INTERPRETATION OF THE FINDINGS & FURTHER RECOMMENDATIONS

1 Year

Primary considerations for the sonographic findings include FIP or multicentric neoplasia, i.e. lymphomatosis or similar. FIP is favored given familial history.

WEIGHT

Further assessment may include (assuming normal clotting status) lymph node FNA cytology and abdominal effusion analysis cytology, and FIP titers/PCR. Unfortunately, an unfavorable prognosis is indicated. Gastrointestinal support is recommended.

13.2 pounds

INTERPRETED BY

R. McKenzie Daniel,
 DVM, DABVP (Canine
 / Feline Practice)

IMAGING PERFORMED BY

Meghan Morse LVT,
 CVT

HOSPITAL NAME

Walden Animal Clinic

REFERRING VET

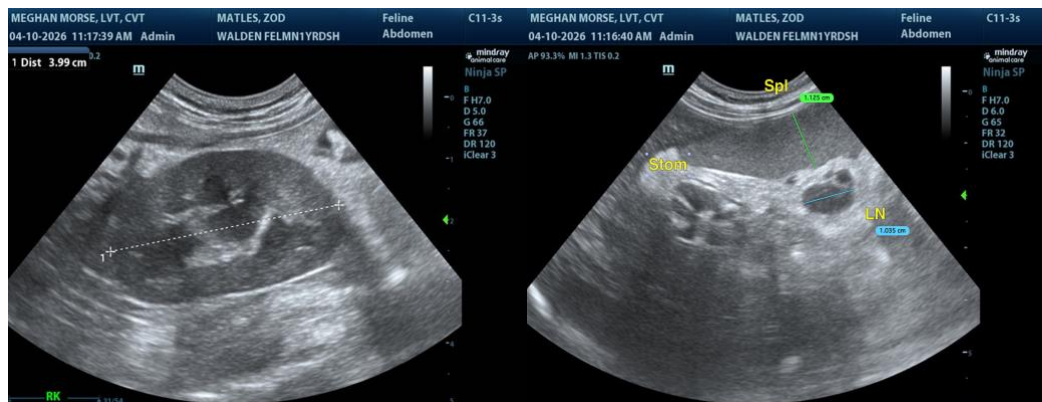
Dr. Dickey

INVOICE

15016

DATE

04/10/26





PATIENT

Zod Matles

SPECIES

Feline

BREED

DSH

SEX

Neutered Male

AGE

1 Year

WEIGHT

13.2 pounds

INTERPRETED BY

R. McKenzie Daniel,
 DVM, DABVP (Canine
 / Feline Practice)

**IMAGING
 PERFORMED BY**

Meghan Morse LVT,
 CVT

HOSPITAL NAME

Walden Animal Clinic

REFERRING VET

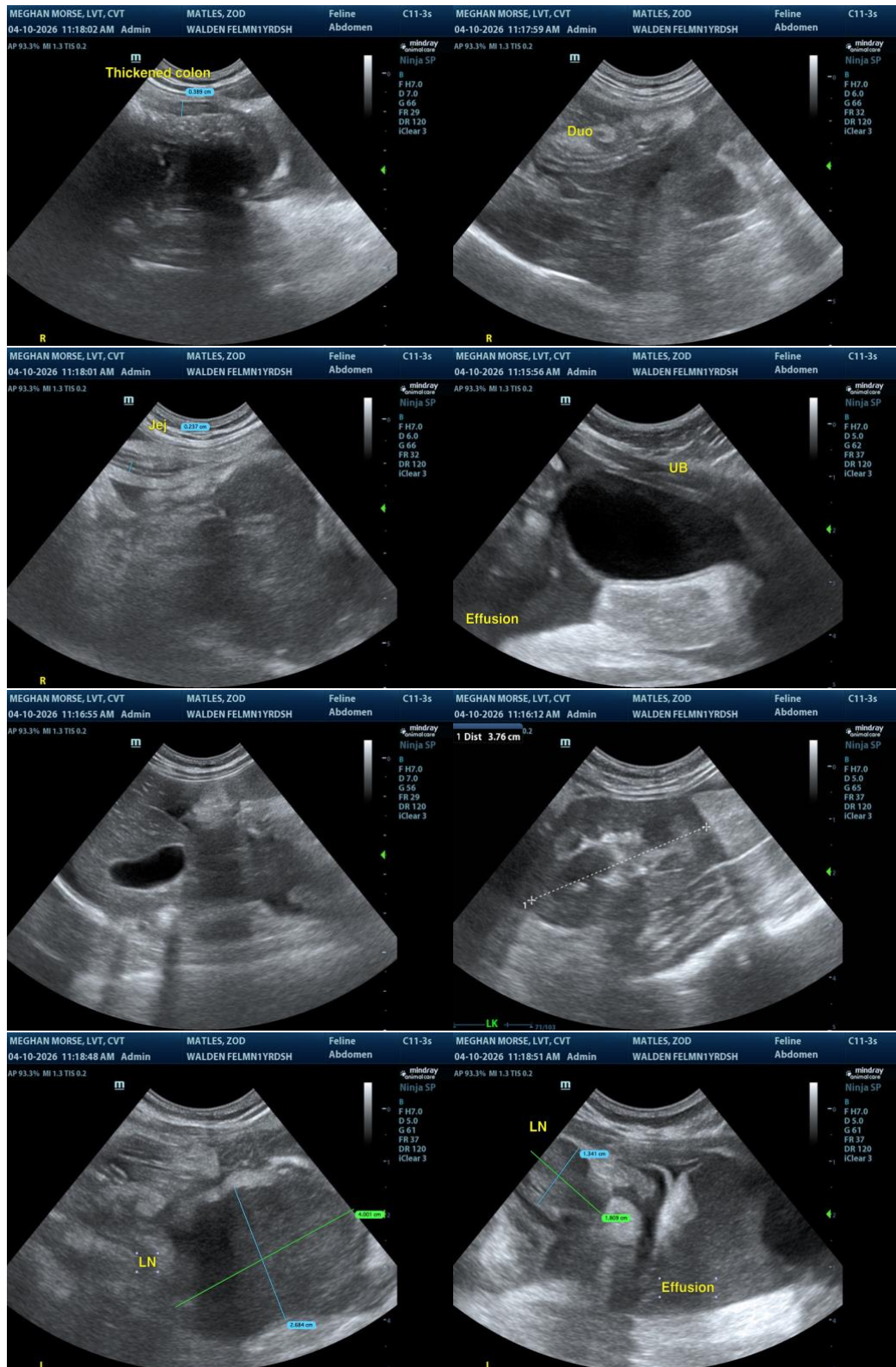
Dr. Dickey

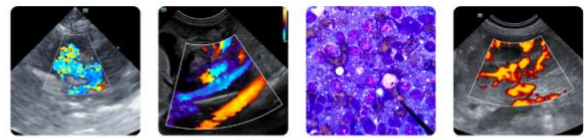
INVOICE

15016

DATE

04/10/26





PATIENT

Zod Matles

SPECIES

Feline

BREED

DSH

SEX

Neutered Male

AGE

1 Year

WEIGHT

13.2 pounds

INTERPRETED BY

R. McKenzie Daniel,
DVM, DABVP (Canine
/ Feline Practice)

**IMAGING
PERFORMED BY**

Meghan Morse LVT,
CVT

HOSPITAL NAME

Walden Animal Clinic

REFERRING VET

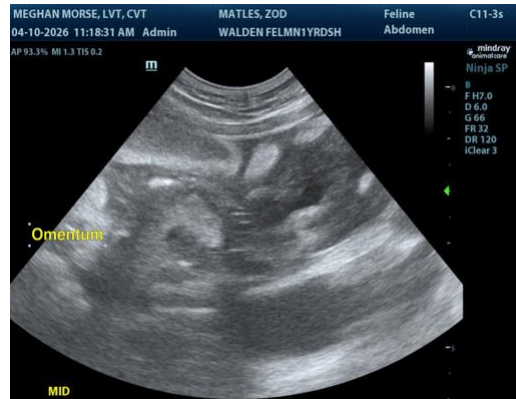Dr. Dickey

INVOICE

15016

DATE

04/10/26



The information and recommendations provided are based on the images presented by the referring veterinarian/sonographer. No evaluation can be communicated regarding pathology that was not visible in the image/video clips provided.

Thank you for this referral. If the clinical or image interpretation does not parallel your findings or if I can be of any further assistance, please contact me.

R. McKenzie Daniel, DVM, DABVP (Canine / Feline Practice)

info@SonoPath.com