

PATIENT

Max Gorhan

SPECIES

Canine

BREED

Labradoodle

SEX

Neutered Male

AGE

8 Years

WEIGHT

37 kg

INTERPRETED BY

R. McKenzie Daniel,
DVM, DABVP (Canine
/ Feline Practice)

IMAGING PERFORMED BY

Dr. Sarah Barthelemy

HOSPITAL NAME

Fish Creek Pet Hospital

REFERRING VET

Dr. Wilson

INVOICE

15008

DATE

04/10/26

PRESENTING CLINICAL SIGNS

1 week lethargy, hyporexia progressing to anorexia, diarrhea, vomiting

Abnormal PE/Chem/CBC/UA Results: Marked ALP and ALT elevation Elevated GGT mild, moderate tbili elevation Marked thrombocytopenia Neutrophilia and monocytosis

ULTRASONOGRAPHIC EXAMINATION OF THE ABDOMEN

Urinary System

The urinary bladder, trigone, cystourethral junction, and visible pelvic urethra to a depth of 3.0 cm exhibited normal thickness and tone. Anechoic urine was present in the lumen with no uroliths or sediment. The ureteral papillae were normal. The ureters were not visible which is normal. No evidence of inflammatory or neoplastic change were noted.

The area of the residual prostate appeared normal and free of pathology.

Normal size and margination was present in the kidneys. A normal 1:3 cortex / medulla ratio and normal corticomedullary definition were maintained. The echogenicity of the cortex was similar to or slightly less than normal liver parenchyma while the medulla echogenicity was hypoechoic to the cortex with no evidence of pelvic dilation. The left kidney measured 6.8 cm in length. The right kidney measured 7.2 cm in length.

Adrenal Glands

The left adrenal gland was uniform in size and contour with a uniformly hypoechoic parenchyma. The left adrenal gland measured 0.64 cm width at the caudal pole.

The right adrenal gland was uniform in size and contour with a uniformly hypoechoic parenchyma. The right adrenal gland measured 0.55 cm width at the caudal pole.

Spleen

The spleen revealed generalized splenomegaly. Multifocal, small to discrete, hypoechoic nodules were present diffusely throughout the parenchyma without associated capsule impingement or distortion. The splenic vasculature at the hilus was normal in volume with no evidence of congestion or thrombosis. A mild irregular expansive mixed echogenic caudal splenic mass was present with associated capsule distortion measuring approximately 5.6 cm x 4.0 cm.

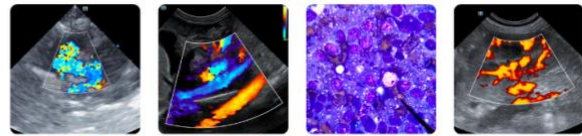
Liver & Gallbladder

The liver revealed hepatomegaly with symmetrical rounded mildly swollen capsule contour and homogenous mildly hypoechoic parenchyma with mild increased prominence of the intrahepatic hyperechoic portal vascular borders. Distinct masses or nodules were not evident. The hepatic and portal vasculature were normal in appearance without signs of congestion.

The gallbladder was non distended in size with mild congealed nonorganized biliary sludge. The cystic duct and common bile ducts were normal without evidence of dilation.

Gastrointestinal

The stomach presented intact wall layering with a normal wall layer ratio. The stomach was mildly gas distended.



PATIENT

Max Gorhan

SPECIES

Canine

BREED

Labradoodle

SEX

Neutered Male

AGE

8 Years

WEIGHT

37 kg

INTERPRETED BY

R. McKenzie Daniel,
DVM, DABVP (Canine
/ Feline Practice)

IMAGING PERFORMED BY

Dr. Sarah Barthelmy

HOSPITAL NAME

Fish Creek Pet Hospital

REFERRING VET

Dr. Wilson

INVOICE

15008

DATE

04/10/26

The small intestine presented intact wall layering with 1:3 muscularis/mucosa ratio. The lumen of the small intestine was empty with no signs of ileus, obstruction or foreign material.

Normal visible colon wall layers were present with soft fecal matter consistent with patient's history.

Pancreas

The parenchyma of the left limb, body and right limb of the pancreas presented isoechoic to the adjacent omental fat. A normal curvilinear capsule contour of the pancreas was present. The visible pancreatic duct was normal. No signs of active inflammation or neoplastic disease was evident.

Free Abdomen

Mildly hypoechoic to swollen hepatic lymph nodes adjacent to the portal vein were present with an example measuring 2.9 cm x 1.3 cm. Minor pockets of perihepatic to peritoneal effusion.

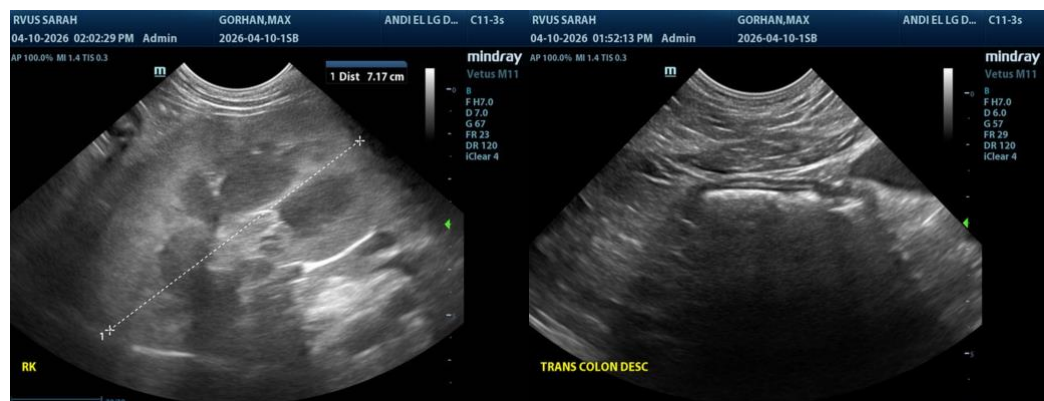ULTRASONOGRAPHIC FINDINGS

- Macronodular spleen with caudal splenic mass.
- Enlarged hypoechoic noncongested liver.
- Mild nonorganized gallbladder debris (non-mucocele).
- Sonographically unremarkable gastrointestinal tract with soft fecal matter in colon.
- Mildly swollen hepatic lymphadenopathy.
- Minor perihepatic/peritoneal effusion.

INTERPRETATION OF THE FINDINGS & FURTHER RECOMMENDATIONS

The hepatosplenic presentation meets multicentric neoplastic criteria with considerations including round cell neoplasia, hemangiosarcoma, histiocytic sarcoma or other.

FNA cytology of the spleen and liver using a 25-gauge needle and assuming normal clotting status is warranted for further assessment with potential for oncology consult. No evidence of post-hepatic obstruction. Suggested sampling may be dependent on stabilization of thrombocytopenia. Unfortunately, an unfavorable prognosis is indicated.





PATIENT

Max Gorhan

SPECIES

Canine

BREED

Labradoodle

SEX

Neutered Male

AGE

8 Years

WEIGHT

37 kg

INTERPRETED BY

R. McKenzie Daniel,
DVM, DABVP (Canine
/ Feline Practice)

**IMAGING
PERFORMED BY**

Dr. Sarah Barthelemy

HOSPITAL NAME

Fish Creek Pet Hospital

REFERRING VET

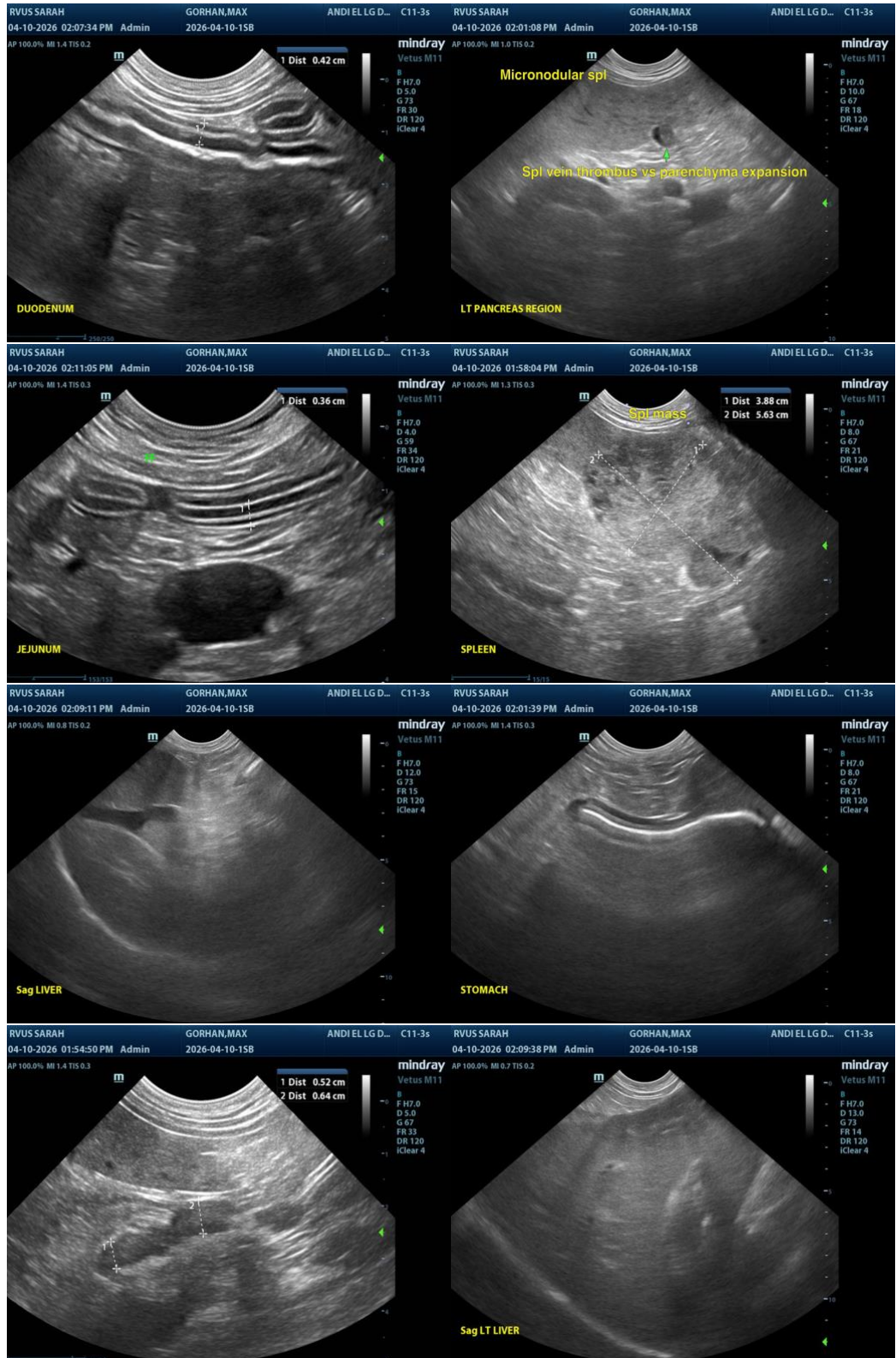
Dr. Wilson

INVOICE

15008

DATE

04/10/26





PATIENT

Max Gorhan

SPECIES

Canine

BREED

Labradoodle

SEX

Neutered Male

AGE

8 Years

WEIGHT

37 kg

INTERPRETED BY

R. McKenzie Daniel,
DVM, DABVP (Canine
/ Feline Practice)

IMAGING PERFORMED BY

Dr. Sarah Barthelemy

HOSPITAL NAME

Fish Creek Pet Hospital

REFERRING VET

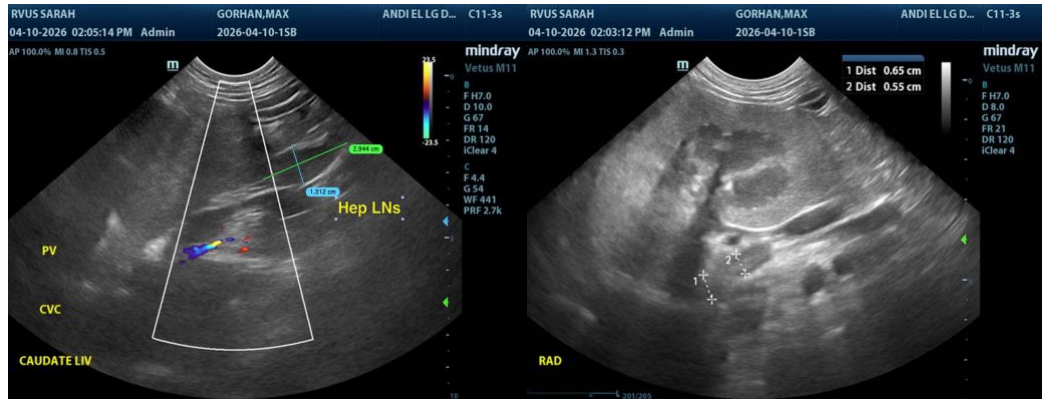
Dr. Wilson

INVOICE

15008

DATE

04/10/26



The information and recommendations provided are based on the images presented by the referring veterinarian/sonographer. No evaluation can be communicated regarding pathology that was not visible in the image/video clips provided.

Thank you for this referral. If the clinical or image interpretation does not parallel your findings or if I can be of any further assistance, please contact me.

R. McKenzie Daniel, DVM, DABVP (Canine / Feline Practice)

info@SonoPath.com