SonoPath
Clinical Sonography & Telecytology

EDUCATIONAL TELECONSULTATION SERVICES™

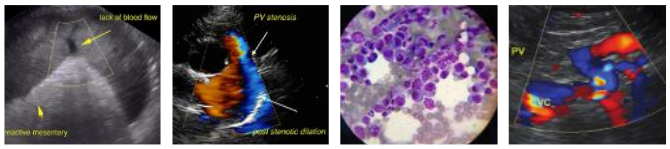

SonoPath.com
1-800-838-4268 info@sonopath.com

PATIENT

Roca Taylor

SPECIES

Feline

BREED

DSH

SEX

FS

AGE

8yr

WEIGHT

9.4lb

INTERPRETED BY

R. McKenzie Daniel, DVM, DABVP (Canine and Feline)

IMAGING PERFORMED BY

Sarah Green

HOSPITAL NAME

Healing Spirit Animal Wellness

REFERRING VET

Sarah Green

INVOICE

13445ag

DATE

04/10/2023

PRESENTING CLINICAL SIGNS

Chronic hematuria, azotemia

Abnormal PE/Chem/CBC/UA Results: No weight loss or other significant exam findings, BUN=60 (16-37) mg/dL, Cr=3.3 (1.9-2.3) mg/dL, SDMA, P both WNL, UA: usg=1.020, protein= 100 mg/dL, up:c ≥0.4 <2.0, RBCs TNTC no organisms seen, culture negative

ULTRASONOGRAPHIC EXAMINATION OF THE ABDOMEN

Urinary System

The urinary bladder walls were normal. The trigone, cystourethral junction, and visible pelvic urethra to a depth of 1 cm exhibited normal thickness and tone. Anechoic urine was present in the lumen with mild non-dependent particulate to hyperechoic sediment. The sediment may indicate cellular debris / protein, crystalline debris, lipid, or mucus. The ureteral papillae were normal. The ureters were not visible which is normal. No evidence of inflammatory or neoplastic changes were noted.

Normal renal size with asymmetrical margination was present in both kidneys. The renal cortex presented uniformly increased in echogenicity with uniform echotexture. The renal cortex appeared to be hypertrophied resulting in an altered cortex: medulla ratio. Mild to moderate loss of corticomedullary distinction was also present. Bilateral pinpoint medullary mineral was present. The renal medullary volume was subjectively reduced. The left kidney measured 3.8 cm in length. The right kidney measured 3.8 cm in length.

The area of the aortic trifurcation was free of pathology.

Adrenal Glands

The left adrenal gland was uniform in size and contour with a uniformly hypoechoic parenchyma. The left adrenal gland measured 0.4 cm width. No overt pathology in the area of the right adrenal gland.

Spleen

The spleen exhibited a finely textured and homogenous parenchyma which was hyperechoic to the liver and renal cortical parenchyma. The capsule was smooth and regular without apparent expansion. The splenic vasculature at the hilus was normal in volume with no evidence of congestion or thrombosis. Acute to chronic inflammatory, neoplastic, or benign parenchyma changes were not noted.

Liver/Gallbladder

The liver was subjectively normal in size, structure, and contour. The liver parenchyma was uniform and hypoechoic to the spleen with a mild coarse echotexture. The hepatic and portal vasculature were normal in appearance without signs of congestion. The gallbladder was non-distended in size with thin walls and primarily anechoic luminal content. The cystic and common bile ducts were normal.

Gastrointestinal

The stomach presented intact wall layering with a normal wall layer ratio. The lumen of the stomach was empty with no signs of ileus, obstruction or foreign material.

The small intestine presented intact wall layering with 1:3 muscularis/mucosa ratio. The lumen of the small intestine was empty with no signs of ileus, obstruction or foreign material.

Normal visible colon wall layers were present with apparent formed feces in lumen.

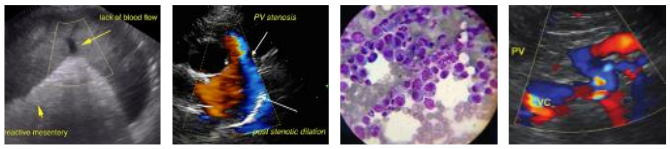

SonoPath.com
1-800-838-4268 info@sonopath.com

PATIENT

Roca Taylor

SPECIES

Feline

BREED

DSH

SEX

FS

AGE

8yr

WEIGHT

9.4lb

INTERPRETED BY

R. McKenzie Daniel, DVM, DABVP (Canine and Feline)

IMAGING PERFORMED BY

Sarah Green

HOSPITAL NAME

Healing Spirit Animal Wellness

REFERRING VET

Sarah Green

INVOICE

13445ag

DATE

04/10/2023

Pancreas

The pancreas was normal in size and contour with heterogenous subtly hypoechoic parenchyma present in the left pancreatic limb. Minor pancreatic duct dilation was present.

Free Abdomen

No omental masses, overt lymphadenopathy or peritoneal effusion was present.

ULTRASONOGRAPHIC FINDINGS

- Sonographically unremarkable urinary bladder/visible urethra with mild urinary bladder sediment.
- Non-specific chronic renal changes with pinpoint dystrophic medullary mineral and suspect cortical infarcts.

Secondary findings

- Mild heterogenous hypoechoic left pancreas-suspect patient variant given no reported clinical signs. Potential for low grade pancreatic inflammation possible.

INTERPRETATION OF THE FINDINGS & FURTHER RECOMMENDATIONS

No evidence of lower urinary tract pathology as an obvious cause of the patient's hematuria which suggests primary renal origin of the hematuria. No evidence of upper/lower urinary tract neoplastic criteria present. Empirical CKD therapy with potential ACE inhibitor medication given the evidence of proteinuria with concurrent azotemia is recommended. Monitoring of systemic BP is advised. Subjectively the kidneys do not appear to be end stage yet prognosis may be considered variable with continued monitoring of renal response to CKD therapy +/- as needed fluid therapy.

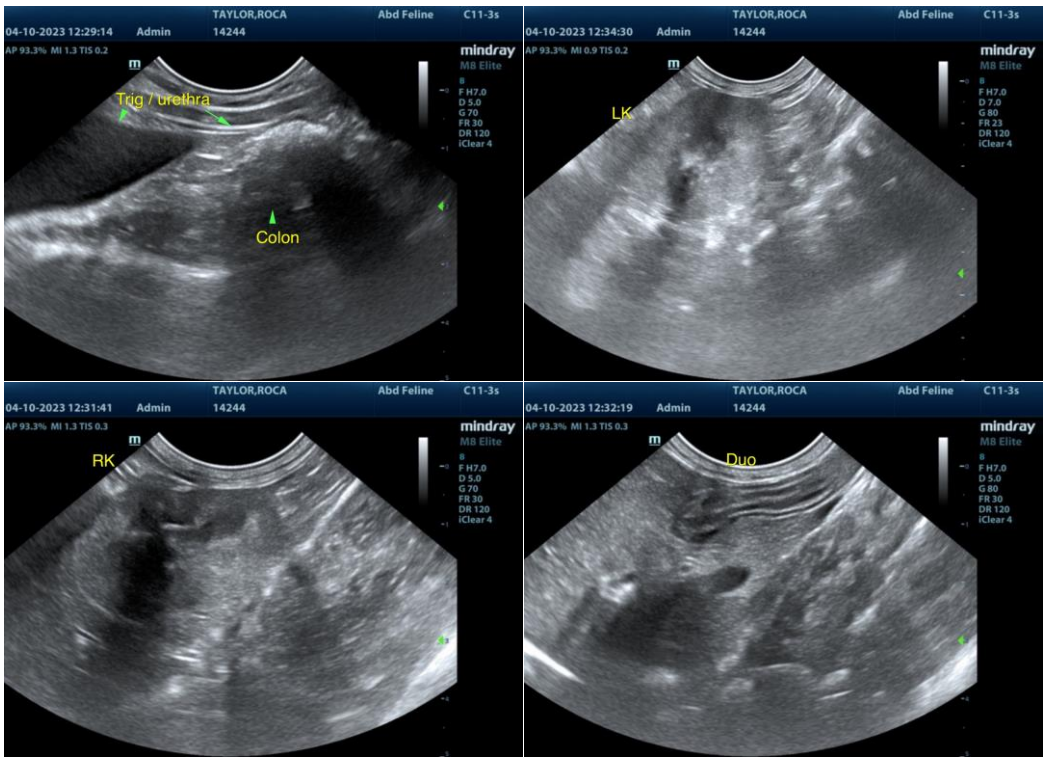

SonoPath

Clinical Sonography & Telecytology

EDUCATIONAL TELECONSULTATION SERVICES™

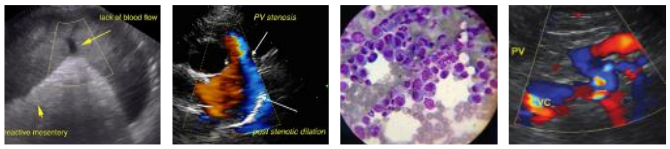

SonoPath.com™
1-800-838-4268 info@sonopath.com

PATIENT

Roca Taylor

SPECIES

Feline

BREED

DSH

SEX

FS

AGE

8yr

WEIGHT

9.4lb

INTERPRETED BY

R. McKenzie Daniel, DVM, DABVP (Canine and Feline)

IMAGING PERFORMED BY

Sarah Green

HOSPITAL NAME

Healing Spirit Animal Wellness

REFERRING VET

Sarah Green

INVOICE

13445ag

DATE

04/10/2023

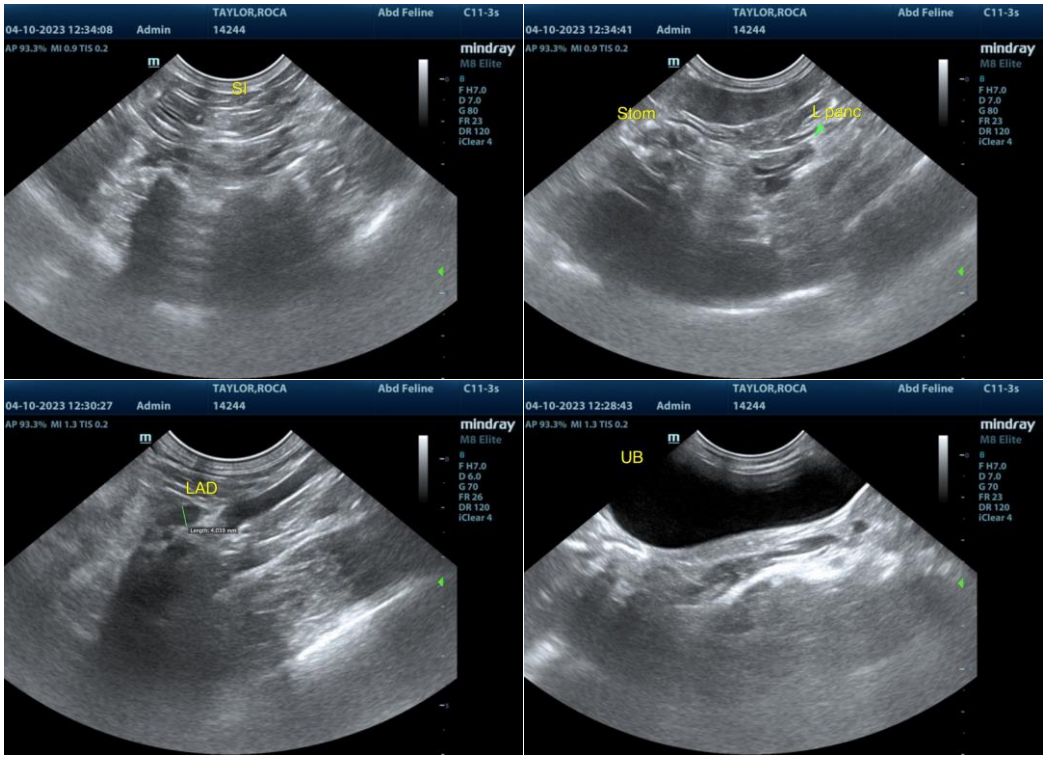

The information and recommendations provided are based on the images presented by the referring veterinarian/sonographer. No evaluation can be communicated regarding pathology that was not visible in the image/video clips provided.

Thank you for this referral. If the clinical or image interpretation does not parallel your findings or if I can be of any further assistance, please contact me.

R. McKenzie Daniel, DVM, DABVP (Canine/Feline Practice)
mac.daniel@sonopath.com