



PATIENT

Rocco Carmichael

SPECIES

Canine

BREED

Shih Tzu

SEX

Male Neutered

AGE

15y 10m 2wks

WEIGHT

7 kgs

INTERPRETED BY

R. McKenzie Daniel,
DVM, DABVP
(Canine and Feline)

IMAGING PERFORMED BY

Dr. Jill Rankin

HOSPITAL NAME

VCA Canada Coach
Hill AH

REFERRING VET

Dr. Barker

INVOICE

13358

DATE

4/1/26

PRESENTING CLINICAL SIGNS

History: Rocco is a 15-year-old Shih Tzu mix presenting for a history of hypertension and an elevated urine protein/creatinine (UPC) ratio. The current diagnostic plan includes an abdominal ultrasound and radiographs to further investigate his condition. For his hypertension, Rocco was initially started on telmisartan. Due to persistently high blood pressure, amlodipine was added approximately one week ago. The owner has since discontinued the telmisartan. Regarding his renal status, a urinalysis on March 4 showed 3+ protein with a urine specific gravity (USG) of 1.017. A more recent urinalysis via cystocentesis, performed within the last two weeks, revealed a UPC of 2.9, a USG of 1.012, and 2+ protein. Bloodwork from March 4 indicated a slightly elevated BUN (12.1), a high platelet count (420), neutrophilia, and lymphopenia. His T4 level was noted to be normal.

ULTRASONOGRAPHIC EXAMINATION OF THE ABDOMEN

Urinary System

The urinary bladder, trigone, cystourethral junction, and visible pelvic urethra to a depth of 3.0 cm exhibited normal thickness and tone. Anechoic urine was present in the lumen with no uroliths or sediment. The ureteral papillae were normal. The ureters were not visible which is normal. No evidence of inflammatory or neoplastic changes were noted.

The area of the residual prostate appeared normal and free of pathology.

Normal renal size with asymmetrical margination was present in both kidneys. The renal cortex presented uniformly increased in echogenicity with uniform echotexture. The renal cortex appeared to be hypertrophied resulting in an altered cortex: medulla ratio. Moderate indistinct loss of corticomedullary distinction was also present. Pinpoint medullary mineral and intermittent cortical cysts noted. The left kidney measured 3.7 cm in length. The right kidney measured 4.3 cm in length.

Adrenal Glands

The left and right adrenal glands were asymmetrically enlarged in size with expansive non-homogeneous, hypoechoic, non-mineralized nodules with associated capsule asymmetry. Cranial right adrenal nodule measured 2.2 cm x 1.9 cm. Overall, the right adrenal gland measured 5.2 cm length x 1.0 cm width at the caudal pole. The cranial left adrenal nodule measured 2.8 cm length x 1.9 cm. Overall, left adrenal gland measured 2.9 cm x 0.86 cm width at the caudal pole.

Spleen

The spleen exhibited a finely textured and homogenous parenchyma which was hyperechoic to the liver and renal cortical parenchyma. The capsule was smooth and regular without apparent expansion. The splenic vasculature at the hilus was normal in volume with no evidence of congestion or thrombosis. Acute to chronic inflammatory, neoplastic, or benign parenchyma changes were not noted.

Liver

The liver presented subjective mildly enlarged in size with mildly rounded symmetrical capsule contour and mildly increased hepatic parenchymal echogenicity compared to the spleen and renal cortices. The echotexture of the liver parenchyma was uniform with a mild coarse echotexture. The capsule of the liver was symmetrical in margination. The hepatic and portal vasculature were normal in appearance without signs of congestion. Intermittent, discrete, hypoechoic to non-homogeneous intraparenchymal nodules were present with an example measuring 0.8 cm in diameter. The gallbladder was non



PATIENT

Rocco Carmichael

SPECIES

Canine

BREED

Shih Tzu

SEX

Male Neutered

AGE

15y 10m 2wks

WEIGHT

7 kgs

INTERPRETED BY

R. McKenzie Daniel,
DVM, DABVP
(Canine and Feline)

IMAGING PERFORMED BY

Dr. Jill Rankin

HOSPITAL NAME

VCA Canada Coach
Hill AH

REFERRING VET

Dr. Barker

INVOICE

13358

DATE

4/1/26

distended in size with mild to moderate, congealed, non-organized, hyperechoic, nonmineralized biliary sludge. The cystic duct and common bile ducts were normal without evidence of dilation.

Gastrointestinal

The stomach presented intact wall layering with a normal wall layer ratio. The lumen of the stomach was empty with no signs of ileus, obstruction or foreign material.

The small intestine presented intact wall layering with 1:3 muscularis/mucosa ratio. The lumen of the small intestine was empty with no signs of ileus, obstruction or foreign material.

Normal visible colon wall layers were present with apparent formed feces in lumen.

Pancreas

The pancreas was normal in size and contour with mild isoechoic to heterogeneous parenchyma compared to adjacent omentum. No signs of active inflammation or neoplasia.

Free Abdomen

No overt lymphadenopathy or peritoneal effusion was present.

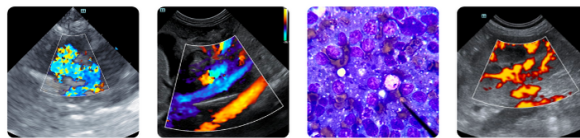
ULTRASONOGRAPHIC FINDINGS

- Mild hepatomegaly with discrete liver nodules
- Congealed, non-organized gallbladder debris – not consistent with mature mucocele
- Bilateral nodular adrenomegaly
- Chronic renal changes exhibiting medullary mineral and cortical cysts
- Mild pancreatic remodeling

INTERPRETATION OF THE FINDINGS & FURTHER RECOMMENDATIONS

Both adrenal glands abnormal and nodular in appearance with considerations including hyperplasia, functional vs non-functional adenomas, unilateral to bilateral adrenal tumors or combination. Overt adrenal vascular invasion was not obvious. Vacuolar inflammatory, metabolic or reactive hepatopathy, discrete areas of nodular hyperplasia or hematopoiesis, hepatic fibrosis, early primary or metastatic hepatic neoplastic nodules possible.

Urine metanephrine level is recommended to assess for evidence of pheochromocytoma given historical hypertension. Adrenal testing with LDDST recommended if clinical signs consistent with Cushing's Syndrome. Assuming normal clotting status and using 25-gauge needle, hepatic parenchyma and accessible nodular FNA cytology could be considered for further assessment. Hepato-supportive medications, if evidence of cholestasis, is indicated. Further evaluation may include abdominal CT vs serial sonographic monitoring of the liver and bilateral adrenal glands for evidence of progressive pathology.



PATIENT

Rocco Carmichael

SPECIES

Canine

BREED

Shih Tzu

SEX

Male Neutered

AGE

15y 10m 2wks

WEIGHT

7 kgs

INTERPRETED BY

R. McKenzie Daniel,
DVM, DABVP
(Canine and Feline)

IMAGING PERFORMED BY

Dr. Jill Rankin

HOSPITAL NAME

VCA Canada Coach
Hill AH

REFERRING VET

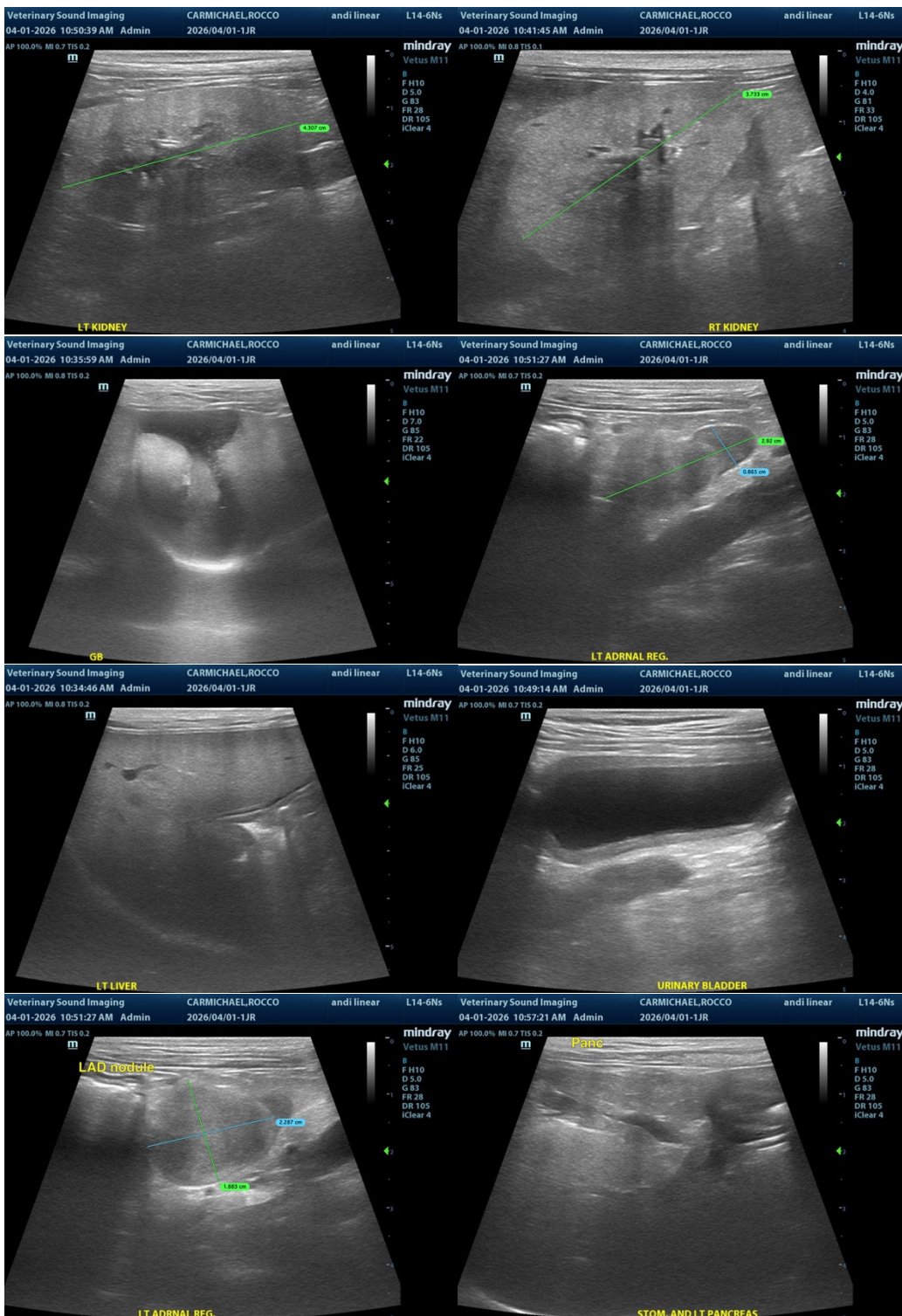
Dr. Barker

INVOICE

13358

DATE

4/1/26





PATIENT

Rocco Carmichael

SPECIES

Canine

BREED

Shih Tzu

SEX

Male Neutered

AGE

15y 10m 2wks

WEIGHT

7 kgs

INTERPRETED BY

R. McKenzie Daniel,
DVM, DABVP
(Canine and Feline)

IMAGING PERFORMED BY

Dr. Jill Rankin

HOSPITAL NAME

VCA Canada Coach
Hill AH

REFERRING VET

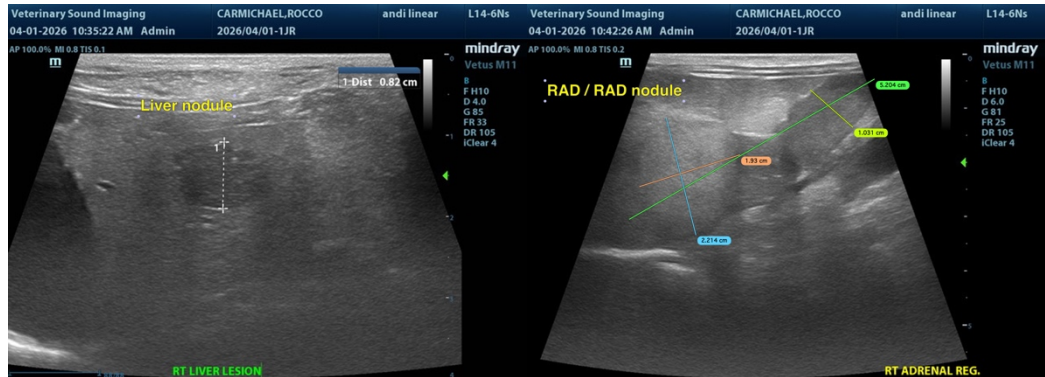
Dr. Barker

INVOICE

13358

DATE

4/1/26



The information and recommendations provided are based on the images presented by the referring veterinarian/sonographer. No evaluation can be communicated regarding pathology that was not visible in the image/video clips provided.

Thank you for this referral. If the clinical or image interpretation does not parallel your findings or if I can be of any further assistance, please contact me.

R. McKenzie Daniel, DVM, DABVP (Canine / Feline Practice)

info@sonopath.com