


PATIENT PRESENTING CLINICAL SIGNS

Alice Laurie History: History of juvenile renal dysplasia Not eating for 3 days Vomiting more than usual Shaking and restless but no energy on her walks Ampicillin 22mg/kg TID, Cerenia 1mg/kg SID, Buprenorphine 0.015mg/kg BID

SPECIES

Canine

Abnormal PE/Chem/CBC/UA Results: CREA high (unreadable) UREA high (unreadable) PHOS high (unreadable) CPLi abnormal

BREED

Standard Poodle

ULTRASONOGRAPHIC EXAMINATION OF THE ABDOMEN
Urinary System
SEX

Spayed female

The urinary bladder presented mildly distended in size with normal tone and anechoic urine with moderate dependent to non-dependent sediment. The trigone, cystourethral junction, and visible pelvic urethra to a depth of 3 cm exhibited normal thickness and tone. Anechoic urine was present in the lumen with no uroliths or sediment. The ureteral papillae were normal. The ureters were not visible which is normal. No evidence of inflammatory or neoplastic changes were noted.

AGE

6 years

Normal renal size with asymmetrical margination was present in both kidneys. The renal cortex presented uniformly increased in echogenicity with uniform echotexture. The renal cortex appeared to be hypertrophied resulting in an altered cortex: medulla ratio. Mild loss of corticomedullary distinction was also present. The renal medullary volume was subjectively reduced. Minor pyelectasia was present in the right kidney. The left kidney measured 4.7 cm in length. The right kidney measured 5.0 cm in length.

WEIGHT

22.7 kg

The area of the aortic trifurcation was free of pathology.

INTERPRETED BY

R. McKenzie Daniel,
 DVM, DABVP
 (Canine and Feline)

Adrenal Glands

The left adrenal gland was uniform in size and contour with a uniformly hypoechoic parenchyma. The left adrenal gland measured 0.68 cm width at the caudal pole and 2.3 cm length. The right adrenal gland was uniform in size and contour with a uniformly hypoechoic parenchyma. The right adrenal gland measured 0.78 cm width at the caudal pole.

IMAGING PERFORMED BY

Crystal Hill

Spleen
HOSPITAL NAME

Beattie Pet Hospital

The spleen exhibited a finely textured and homogenous parenchyma which was hyperechoic to the liver and renal cortical parenchyma. The capsule was smooth and regular without apparent expansion. The splenic vasculature at the hilus was normal in volume with no evidence of congestion or thrombosis. Acute to chronic inflammatory, neoplastic, or benign parenchyma changes were not noted.

REFERRING VET

Dr. Salib

Liver

The liver was subjectively normal in size, structure, and contour. The liver parenchyma was uniform and hypoechoic to the spleen with a mild coarse echotexture. The hepatic and portal vasculature were normal in appearance without signs of congestion. The gallbladder was non-distended in size with thin walls and moderate nondependent mildly congealed yet nonorganized debris. The cystic and common bile ducts were normal.

INVOICE

10274ag

DATE

04/01/2022


PATIENT *Gastrointestinal*

Alice Laurie The stomach presented wall thickening secondary to echogenic mucosa hypertrophy. Intact wall layering was maintained and distinct. Mild gastric distension with minor primarily anechoic fluid was present.

SPECIES The small intestine presented intact wall layering with 1:3 muscularis/mucosa ratio. The lumen of the small intestine was empty with no signs of ileus, obstruction or foreign material.

Canine

Normal visible colon wall layers were present with apparent formed feces in lumen.

BREED *Pancreas*

Standard Poodle

The pancreas was normal in size and contour with isoechoic to heterogeneous parenchyma compared to adjacent omentum. No signs of active inflammation or neoplasia.

SEX *Free Abdomen*

Spayed female

No overt lymphadenopathy or peritoneal effusion was present.

AGE

6 years

ULTRASONOGRAPHIC FINDINGS
WEIGHT

22.7 kg

- Bilateral renal dysplasia with minor right kidney pyelectasia.
- Mildly distended urinary bladder containing moderate sediment.
- Uremic gastritis.
- Moderate gallbladder debris-nonspecific incidental likely secondary to fasting or nonclinical cholestasis.

INTERPRETED BY

R. McKenzie Daniel,
 DVM, DABVP
 (Canine and Feline)

INTERPRETATION OF THE FINDINGS & FURTHER RECOMMENDATIONS

The bilateral kidneys are consistent with the previous diagnosis of congenital renal dysplasia, this is likely progressive given the significant azotemia. No overt evidence of active pancreatitis yet potential for low grade pancreatitis could be present. Further renal staging to include urine C/S and baseline UPC if no evidence of inflammatory cells is suggested as well as BP assessment. Hospitalization with diuresis protocol, monitoring of urine output and body weight and as needed gastrointestinal support with assessment of renal response would be reasonable. A guarded prognosis is indicated given the renal presentation in light of severe azotemia.

IMAGING PERFORMED BY

Crystal Hill

HOSPITAL NAME

Beattie Pet Hospital

REFERRING VET

Dr. Salib

INVOICE

10274ag

DATE

04/01/2022



PATIENT

Alice Laurie

SPECIES

Canine

BREED

Standard Poodle

SEX

Spayed female

AGE

6 years

WEIGHT

22.7 kg

INTERPRETED BY

R. McKenzie Daniel,
DVM, DABVP
(Canine and Feline)

IMAGING PERFORMED BY

Crystal Hill

HOSPITAL NAME

Beattie Pet Hospital

REFERRING VET

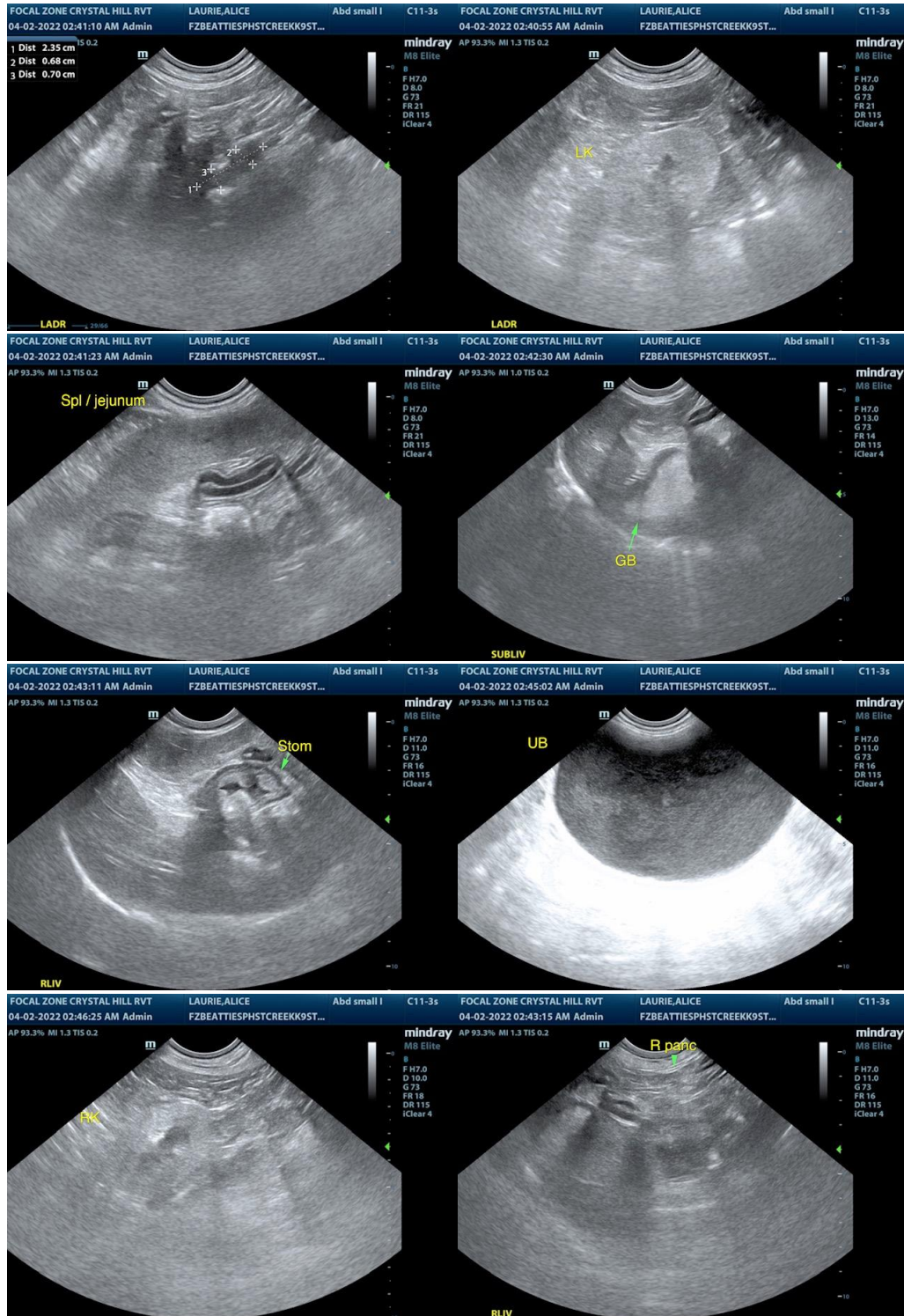
Dr. Salib

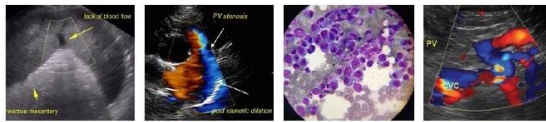
INVOICE

10274ag

DATE

04/01/2022





PATIENT

Alice Laurie

The information and recommendations provided are based on the images presented by the referring veterinarian/sonographer. No evaluation can be communicated regarding pathology that was not visible in the image/video clips provided.

SPECIES

Canine

Thank you for this referral. If the clinical or image interpretation does not parallel your findings or if I can be of any further assistance please contact me.

R. McKenzie Daniel, DVM, DABVP (Canine / Feline Practice)

info@SonoPath.com

BREED

Standard Poodle

SEX

Spayed female

AGE

6 years

WEIGHT

22.7 kg

INTERPRETED BY

R. McKenzie Daniel,
DVM, DABVP
(Canine and Feline)

**IMAGING
PERFORMED BY**

Crystal Hill

HOSPITAL NAME

Beattie Pet Hospital

REFERRING VET

Dr. Salib

INVOICE

10274ag

DATE

04/01/2022